



Peri-operative Imaging in Extremity Fractures

Suzan Beerekamp

Peri-operative Imaging in Extremity Fractures

Suzan Beerekamp

This thesis was prepared at the Trauma Unit, Department of Surgery, Amsterdam University Medical Centers, location Academic Medical Center, University of Amsterdam, the Netherlands.

Copyright 2020 © Suzan Beerekamp, Amsterdam, the Netherlands.
No parts of this thesis may be reproduced, stored or transmitted in any form or by any means, without prior permission of the author.

Part of the research described in this thesis was financially supported by Philips Healthcare, Best, the Netherlands.

The printing of this thesis was financially supported by



ISBN: 978-94-6380-869-9

Layout & Cover: Remco Wetzels

Printed by: Proefschriftmaken.nl

Peri-operative imaging in extremity fractures

ACADEMISCH PROEFSCHRIFT

ter verkrijging van de graad van doctor

aan de Universiteit van Amsterdam op gezag van de Rector Magnificus

prof. dr. Ir. K.I.J. Maex

ten overstaan van een door het College voor Promoties ingestelde commissie,

in het openbaar te verdedigen in de Agnietenkapel

op woensdag 23 september 2020, te 10.00 uur

door

Maria Suzanne Henriëtte Beerekamp


geboren te Amsterdam

Promotiecommissie:

Promotores:	prof. dr. J.C. Goslings	AMC - UvA
	prof. dr. D.T. Ubbink	AMC - UvA
Copromotor:	dr. N.W.L. Schep	Maasstad Ziekenhuis
Overige leden:	prof. dr. P.M.M. Bossuyt	AMC - UvA
	prof. dr. M. Poeze	Universiteit Maastricht
	prof. dr. F. Nollet	AMC - UvA
	prof. dr. R.J. Bennink	AMC - UvA
	dr. V.P.M. van der Hulst	OLVG
	dr. J.A. Halm	AMC - UvA
	dr. B. Carelsen	Philips Healthcare

Faculteit der Geneeskunde

Table of Contents		Page
	General introduction and thesis outline	7
Chapter 1	Epidemiology of extremity fractures in The Netherlands <i>Injury 2017; 48: 1355-62</i>	15
Part 1	The radiologic evaluation of reduction and fixation of extremity fractures	
Chapter 2	How to evaluate the quality of fracture reduction and fixation of the wrist and ankle in clinical practice: A Delphi consensus <i>Archives of Orthopaedic Trauma Surgery 2011; 131: 739-46</i>	37
Chapter 3	Evaluation of quality of fracture reduction and fixation of the calcaneus in clinical practice: An international Delphi consensus <i>Archives of Orthopaedic Trauma Surgery 2013; 133: 1377-84</i>	53
Chapter 4	Systematic CT evaluation of reduction and hardware positioning of surgically treated calcaneal fractures: a reliability analysis <i>Archives of Orthopaedic Trauma Surgery 2017; 137: 1261-67</i>	67
Part 2	Intra-operative 3D-imaging in extremity fracture surgery	
Chapter 5	Accuracy and consequences of 3D-fluoroscopy in upper and lower extremity fracture treatment - A systematic review <i>European Journal of Radiology 2012; 81: 4019-28</i>	83
Chapter 6	Effects of intra-operative fluoroscopic 3D-imaging on perioperative strategy in calcaneal fracture surgery <i>Archives of Orthopaedic Trauma Surgery 2017; 137: 1667-75</i>	104
Chapter 7	Fracture surgery of the extremities with the intra-operative use of 3D-RX: a randomized multicenter trial (EF3X-trial) <i>BMC Musculoskeletal Disorders 2011; 12: 151</i>	121
Chapter 8	Intraoperative effect of 2D vs 3D fluoroscopy on quality of reduction and patient-related outcome in calcaneal fracture surgery <i>Foot & Ankle International, 2020; ePub ahead of print</i>	137
Chapter 9	The correlation between intra-operative 2D- and 3D-fluoroscopy with postoperative CT-scans in the treatment of calcaneal fractures <i>European Journal of Radiology 2019; 112: 222-228</i>	157
	Thesis summary	169
	General discussion & future perspectives	175
	Nederlandse samenvatting	182
	Algemene discussie en toekomstperspectieven	185
	Appendix	
	PhD portfolio	192
	Curriculum Vitae	195
	List of publications	196
	Dankwoord	199



General introduction & thesis outline

General introduction

Extremity fractures are the most frequently occurring fractures. These fractures can have a major impact on patients' quality of life due to loss of function. Fractures extending into the joint surface are more likely to result in loss of function. For these fractures, anatomical position of fracture fragments is essential because they require primary bone healing.¹ Therefore dislocated intra-articular fractures require surgical intervention to restore the anatomy and provide a rigid fixation allowing for early active motion of the joint. Additionally, the quality of the soft tissue surrounding the fracture is equally important for the healing capability and prevention of infection. Surgical damage to the surrounding tissue should therefore be limited as much as possible.¹

The ultimate goal of articular fracture surgery is to restore pre-existent joint function and thus limit a patients' overall burden and, specifically, his or her loss of productivity and the consequent societal costs. Reduction and fixation are performed with as little soft tissue damage as possible to achieve optimal functional outcome in articular fractures.

Intra-operative fluoroscopic imaging provides better visualization of the fracture fragments and position of implants, especially when direct views are limited due to a minimally invasive approach. Intra-operative 2D-imaging is commonly used, however projection of structures over one another can be misleading. This technique can result in residual articular steps and gaps as well as incorrect positioned implants not recognized on the 2D-images. To gain more insight and consequently improve the quality of reduction and fixation, intra-operative 3D-imaging has been introduced.

For the studies in this thesis, the BV Pulsera with 3D-RX (3-Dimensional Rotational X-ray) has been used. The BV Pulsera (Philips Healthcare, Best, the Netherlands) consists of a mobile C-arm unit modified to provide a motorized rotational movement and is combined with a Philips 3D-RA workstation. Intra-operative 2D-imaging produces the image of a single X-ray pulse, providing a projection image. For intra-operative 3D-imaging, a series of 225 projection images is acquired over a period of 30 seconds leveraging a 200° rotation range of the C-arm. The projection images are used to reconstruct a 3D data set. Both volume rendering and slice images in the axial, coronal and sagittal plane are available. The images can be enhanced by coloring the metal present in the joint (Titanview®).

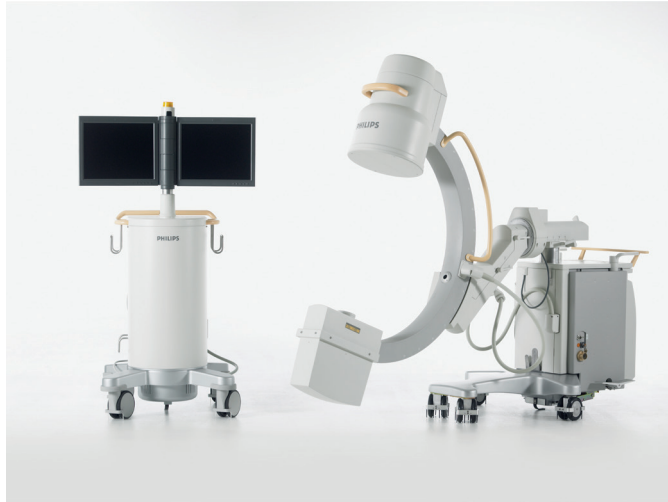


Figure 1: The 3D-RX Pulsera - Philips Healthcare, Best, the Netherlands
Left: The mobile workstation.
Right: The mobile C-arm with the X-ray tube on the downside and image intensifier on the upside

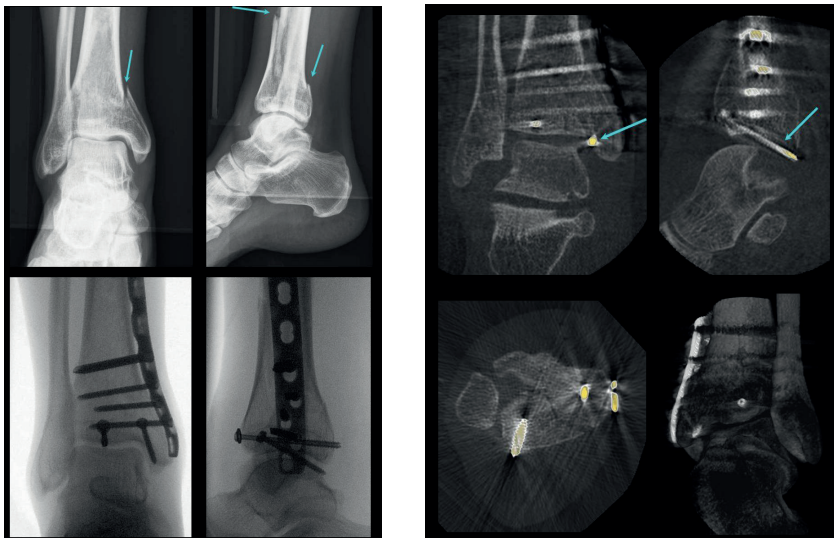


Figure 2: Example of pre- and intra-operative imaging of a pilon fracture²
Upper left: Antero-posterior (AP)- and lateral X-ray views of a pilon fracture pre-operatively. The arrows show the fracture lines.
Lower left: AP and lateral views of intra-operative 2D-fluoroscopic imaging after reduction and fixation.
Right side: Coronal, sagittal and axial reconstructions and volume rendering of intra-operative 3D-fluoroscopic imaging. The metal is colored with Titanview software. The blue arrows show that both pulling screws protrude into the articular surface.

This thesis focuses on the clinical benefits of intra-operative 3D-imaging in patients with an intra-articular fracture of the extremities, requiring surgical reduction and fixation. These benefits are defined as quality of fracture reduction and functional outcome in patients with articular fractures.

Thesis outline

Because of the burden to society, epidemiologic data are essential to policy making.²⁻⁴ The transition to more operative treatment of fractures and a changing demography with an ageing population has led to the need to evolve the current epidemiology of extremity fractures. In **Chapter 1** we aim to explore the trends in incidence and treatment of extremity fractures between 2004 and 2012 in relation to gender and age in more detail.

Part 1 - The radiologic evaluation of reduction and fixation of extremity fractures

A variety of criteria has been introduced to qualify the quality of reduction of intra-articular fractures of the wrist, ankle and calcaneus.⁵⁻²¹ Most of these criteria are angle- or distance measurements. However, no generally accepted scoring protocol is available to qualify an acceptable reduction and fixation of an articular fracture. For evaluation and comparison of radiological results of interventions, a scoring protocol is indispensable. Therefore, the aim is to define which parameters should be part of a radiological scoring protocol. The parameters that should be included in this radiological scoring protocol will be defined by means of a Delphi consensus with clinical experts in **Chapter 2** for the wrist and ankle and in **Chapter 3** for the calcaneus. In **Chapter 4** the aim is to perform a reliability analysis of the radiological scoring protocol of the calcaneus.

Part 2 - Intra-operative 3D-imaging in extremity fracture surgery


In a systematic review in **Chapter 5** we will review the literature on the accuracy and consequences of the intra-operative use of 3D-imaging in extremity fractures. In a retrospective study described in **Chapter 6** we aim to assess the effects of intra-operative use of fluoroscopic 3D-imaging in patients with a calcaneal fracture. The number and type of intra-operative corrections of reduction and implant position will be described, as well as pre- intra- and postoperative (peri-operative) imaging used and patient-relevant outcomes in terms of revision surgery, secondary fusions and infectious complications

In 11-40% of the surgical procedure, additional corrections in fracture reduction and/or fixation are performed after intra-operative 3D-imaging. However, previously no data have been published on how the patient benefits from this in terms of quality of reduction, fixation and clinical outcome. Therefore, we will design a randomized clinical trial aiming to determine the effectiveness of the additional use of intra-operative 3D-imaging. The study protocol is provided in **Chapter 7**. The clinical effectiveness of the use of intra-operative 3D-imaging in calcaneal fracture surgery, in terms of quality of fracture reduction and fixation and patient reported outcomes, is described in **Chapter 8**. In **Chapter 9** the aim is to determine the correlation of the evaluation of the intra-operative 2D- and 3D-images of calcaneal fractures compared to the postoperative CT-images, the reference standard for intra-articular fractures.

References

1. Buckley R., Moran C.G., Apivattthakakul T. AO Principles of fracture treatment. Thieme Medical Publishers, 01/2011, 2018.
2. Beerekamp M.S.H., Ubbink D.T., Luitse J.S.K., et al. Perioperative 3D-fluoroscopy of intra-articular fractures of the extremities. *Nederlands Tijdschrift voor Geneeskunde* 2011; 155: A2737.
3. De Putter C.E., Selles R.W., Polinder S. Economic impact of hand and wrist injuries: Health-Care costs and productivity costs in a population-based study. *The Journal of Bone and Joint Surgery (American Volume)* 2012; 94: e56
4. Meerding W.J., Mulder S., Van Beeck E.F. Incidence and costs of injuries in The Netherlands. *European Journal of Public Health* 2006; 16: 271–277.
5. Polinder S., Haagsma J., Panneman M., et al. The economic burden of injury: Healthcare and productivity costs of injuries in the Netherlands. *Accident; Analysis and Prevention* 2016; 93: 92–100.
6. Langenhuijsen J.F., Heetveld M.J., Ultee J.M., et al. Results of ankle fractures with involvement of the posterior tibial margin. *The Journal of Trauma* 2002; 53: 55–60.
7. Cole R.J., Bindra R.R., Evanoff B.A., et al. Radiographic evaluation of osseous displacement following intra-articular fractures of the distal radius: reliability of plain radiography versus computed tomography. *The Journal of Hand Surgery (American Volume)* 1997; 22: 792–800.
8. Goldfarb C.A., Yin Y., Gilula L.A., et al. Wrist Fractures: What the clinician wants to know. *Radiology* 2001; 219: 11–28.
9. Knirk J.L., Jupiter J.B. Intra-articular fractures of the distal end of the radius in young adults. *Journal of Bone and Joint Surgery (American Volume)* 1986; 68: 647–59.
10. Mann F.A., Wilson A.J., Gilula L.A. Radiographic evaluation of the wrist: What does the hand surgeon want to know? *Radiology* 1992; 184: 15–24.
11. Jaremko J.L., Lambert R.G.W., Rowe B.H., et al. Do radiographic indices of distal radius fracture reduction predict outcomes in older adults receiving conservative treatment? *Clinical Radiology* 2007; 62: 65–72.
12. Jeong G.K., Kaplan F.T.D., Liporace F., et al. An Evaluation of two scoring systems to predict instability in fractures of the distal radius. *The Journal of Trauma* 2004; 57: 1043–7.
13. Jaskulka R.A., Ittner G., Schedl R. Fractures of the posterior tibial margin: Their role in the prognosis of malleolar fractures. *The Journal of Trauma* 1989; 29: 1565–70.
14. Musgrave D.J., Fankhauser R.A. Intraoperative radiographic assessment of ankle fractures. *Clinical Orthopaedics and Related Research* 1998; 351: 186–90.
15. Ovadia D.N., Beals R.K. Fractures of the tibial plafond. *The Journal of Bone and Joint Surgery (American Volume)* 1986; 68: 543–51.
16. Bajammal S., Tornetta P., Sanders D., et al. Displaced intra-articular calcaneal fractures. *Journal of Orthopaedic Trauma* 2005; 19: 360–4.

17. Buckley R., Tough S., McCormack R., et al. Operative compared with nonoperative treatment of displaced intra-articular calcaneal fractures: A prospective, randomized, controlled multicenter trial. *The Journal of Bone and Joint Surgery (American Volume)* 2002; 84-A: 1733–44.
18. Daftary A., Haims A.H., Baumgaertner M.R. Fractures of the Calcaneus: A review with emphasis on CT. *RadioGraphics* 2005; 25: 1215–1226.
19. Paley D., Hall H. Intra-articular fractures of the calcaneus. A critical analysis of results and prognostic factors. *The Journal of Bone and Joint Surgery (American Volume)* 1993; 75: 342–54.
20. Richards P.J., Bridgman S. Review of the radiology in randomised controlled trials in open reduction and internal fixation (ORIF) of displaced intraarticular calcaneal fractures. *Injury* 2001; 32: 633–636.
21. Schepers T., Ginai A.Z., Mulder P.G.H., et al. Radiographic evaluation of calcaneal fractures: To measure or not to measure. *Skeletal Radiology* 2007; 36: 847-52.
22. Walde T.A., Sauer B., Degreif J., et al. Closed reduction and percutaneous Kirschner wire fixation for the treatment of dislocated calcaneal fractures: Surgical technique, complications, clinical and radiological results after 2-10 years. *Archives of Orthopaedic and Trauma Surgery* 2008; 128: 585–591.
23. Khoury A., Siewerdsen J.H., Whyne C.M., et al. Intraoperative cone-beam CT for image-guided tibial plateau fracture reduction. *Computer Aided Surgery* 2007; 12: 195–207.
24. Ruan Z., Luo C., Feng D., et al. Intraoperative three-dimensional imaging in tibial plateau fractures with complex depressions. *Technology and Health Care* 2011; 19: 71–7.
25. Khoury A., Atesok K., Liebergall M., et al. The role of ISO-C3D in crush injuries to the distal lower syndesmosis. *Current Orthopaedic Practice* 2011; 22: 167–170.
26. Rübberdt A., Feil R., Stengel D., et al. The clinical use of the ISO-C(3D) imaging system in calcaneus fracture surgery. *Unfallchirurg* 2006; 109: 112–8.
27. Queitsch C., Schulz A.P., Haustedt N., et al. Improved therapy of calcaneal fractures by intraoperative 3D-fluoroscopy and locked-screw plate fixation. *European Journal of Trauma* 2006; 32: 471–476.
28. Geerling J., Kendoff D., Citak M., et al. Intraoperative 3D imaging in calcaneal fracture care-clinical implications and decision making. *The Journal of Trauma* 2009; 66: 768–73.
29. Kendoff D., Citak M., Gardner M.J., et al. Intraoperative 3D imaging: Value and consequences in 248 cases. *The Journal of Trauma* 2009; 66: 232–8.
30. Atesok K., Finkelstein J., Khoury A., et al. The use of intraoperative three-dimensional imaging (ISO-C-3D) in fixation of intraarticular fractures. *Injury* 2007; 38: 1163–9.
31. Beerekamp M.S.H., Haverlag R., Luitse J.S.K., Ubbink D.T., Goslings J.C. Het peroperatieve gebruik van 3D-beeldvorming bij fracturen aan de extremiteiten. *Nederlands Tijdschrift voor Traumachirurgie* 2011; 2–8.
32. Richter M., Zech S. Intraoperative 3-dimensional imaging in foot and ankle trauma - Experience with a second-generation device (ARCADIS-3D). *Journal of Orthopaedic Trauma* 2009; 23: 213–220.



Chapter I

Epidemiology of extremity fractures in the Netherlands

M.S.H. Beerekamp, R.J.O. de Muinck Keizer, N.W.L. Schep,
D.T. Ubbink, M.J. Panneman, J.C. Goslings

Injury 2017; 48 (7): 1355-62

Abstract

Introduction

Insight in epidemiologic data of extremity fractures is relevant to identify people at risk. By analyzing age- and gender specific fracture incidence and treatment patterns, we may adjust future policy, take preventive measures and optimize health care management. Current epidemiologic data on extremity fractures and their treatment are scarce, outdated or aiming at a small spectrum of fractures. The aim of this study was to assess trends in incidence and treatment of extremity fractures between 2004 and 2012 in relation to gender and age.

Methods

We used a combination of national registries of patients aged ≥ 16 years with extremity fractures. Fractures were coded by the International Classification of Diseases (ICD) 10 and allocated to an anatomic region. ICD-10 codes were used for combining the data of the registries. Absolute numbers, incidences, number of patients treated in university hospitals and surgically treated patients were reported. A binary logistic regression was used to calculate trends during the study period.

Results

From 2004 to 2012 the Dutch population aged ≥ 16 years grew from 13,047,018 to 13,639,412 inhabitants, particularly in the higher age groups of 46 years and older. The absolute number of extremity fractures increased significantly from 129,188 to 176,129 (OR 1.308 [1.299-1.318]), except for forearm and lower leg fractures. Incidences increased significantly (3-4%) for wrist, hand/finger, hip/upper leg, ankle and foot/toe fractures. In contrast to the older age categories from 66 years and older, in younger age categories from 16-35 years, fractures of the extremities were more frequent in men than in women. Treatments gradually moved towards non-university hospitals for all except forearm fractures. Both relative and absolute numbers increased for surgical treatments of clavicle/shoulder, forearm, wrist and hand/finger fractures. Contrarily, lower extremity fractures showed an increase in non-surgical treatment, except for lower leg fractures.

Conclusion

During the study period, we observed an increasing incidence of extremity fractures and a shift towards surgical treatment. Patient numbers in university hospitals declined. If these trends continue, policy makers would be well advised to consider the changing demands in extremity fracture treatment and pro-actively increase capacity and resources.

Introduction

“Study the past, if you would define the future” is a famous quote by Chinese philosopher Confucius (551-479 BC). Extremity fractures comprise a major part of public health care cost in the Western world.^{1,2} Insight in epidemiologic data of extremity fractures is important to identify people at risk for these fractures. By analyzing age- and gender specific fracture incidence and treatment patterns we may be able to adjust future policy, take preventive measures and optimize management in health care.

During the last decades, the ongoing development of surgical implants and a deeper understanding of fracture biology and predictors of functional outcome have changed the indications for surgical fracture treatment.³ In addition, in Western Europe, an ageing population is creating a great challenge with a higher incidence of (severely) osteoporotic fractures. For the younger age category, fracture epidemiology has a substantial influence on societal costs in terms of loss of productivity.⁴ Moreover, national registries are more reliable and therefore useful for national and global comparison.

Unfortunately, currently published epidemiologic studies about extremity fractures and their management are scarce,⁵⁻⁹ outdated¹⁰ or aim at a small spectrum of fractures, for example osteoporotic fractures.^{11,12} Therefore, in order to signal the need for possible policy adjustments in fracture care, the aim of this study was to assess trends in incidence and treatment of extremity fractures between 2004 and 2012 in relation to gender and age.

Patients and Methods

Three databases were used for data collection. Data on the composition of the Dutch population were obtained from Statistics Netherlands (the Hague, the Netherlands).¹³ Mid-year age- and gender-specific data were used to calculate incidence rates per 100,000 persons.

Fracture incidence was determined using the Dutch Injury Surveillance System (DISS).¹⁴ This data extraction was performed by the Consumer Safety Institute (Amsterdam, the Netherlands), by recording all injuries treated at Emergency Departments (ED) of a representative sample of hospitals. During the inclusion period, thirteen hospitals, including three university hospitals and ten non-university hospitals, participated in the DISS. The thirteen hospitals served patients from both rural and urban areas across the country. These hospitals were selected as a representative sample of the Dutch population in terms of age and sex. Together, the patients presenting to the ED's of the thirteen hospitals formed a sample of 12% of the total number of injured patients presenting at the ED's in the Netherlands. These data can be extrapolated to a national level, as described in previous studies.^{15,16}

The DISS registers ED-visits rather than fracture treatments. In order to determine the percentage of patients receiving surgical treatment, abovementioned data were merged with data from the Dutch Hospital Data (DHD, Utrecht, the Netherlands). The DHD registers

data regarding hospital admissions, surgical treatment, gender and age of admitted patients.¹⁷ The DHD has almost complete national coverage (>95%, except in 2012, 88%) and figures were extrapolated to national coverage each year.^{15,16} Patients were included in the DHD according to their main diagnosis at discharge after a hospital admission, usually the more severe injuries.

Correction of missing data

The DHD-data were corrected by weighing for incomplete coverage; the injuries were registered and categorized according to the ICD-10. To merge the extrapolated numbers of DISS and the weighted numbers of DHD datasets to determine the number of patients with a fracture, both datasets were aggregated by year, hospital type, age, gender and fracture location.

About 70-80% of the hospitals were coding surgical procedures in the DHD registry. To determine the fraction of surgically treated patients the hospitals with missing treatment data were removed and the resulting dataset was aggregated by year, hospital type, age, gender, fracture location and calculated the proportion of surgical treatment per case.

The three aggregated datasets with ED-visits-, admissions- and treatment information were merged, and the resulting file was used to obtain the numbers of surgical treatment by multiplying the proportion by the number of admissions per year, hospital type, age, gender and fracture location.

Statistical analyses

Data were expressed as absolute numbers or incidence data per 100,000 inhabitants. To analyze trends in the population, incidences, number of patients treated in a university hospital, and surgically treated patients; a weighed binary logistic regression was used (SPSS version 23, IBM, Armonk, NY, USA). Results were presented as odds ratios (OR) with 95% confidence intervals (CI) with the data from the year 2004 as reference category. Changes with a p-value < 0.05 were considered significant.

Results

Population

Within the nine-year study period, the Dutch adult population (aged ≥ 16 years) grew from 13,047,018 in 2004 to 13,639,412 in 2012. Higher age groups expanded faster than the younger age groups of which some showed a decrease in relative growth (Figure 1 & Table 1). In 2012 people, aged 26-35 and 36-45 years represented 14.7% and 17.7% of the adult population, respectively, versus 17.8% and 19.9% in 2004.

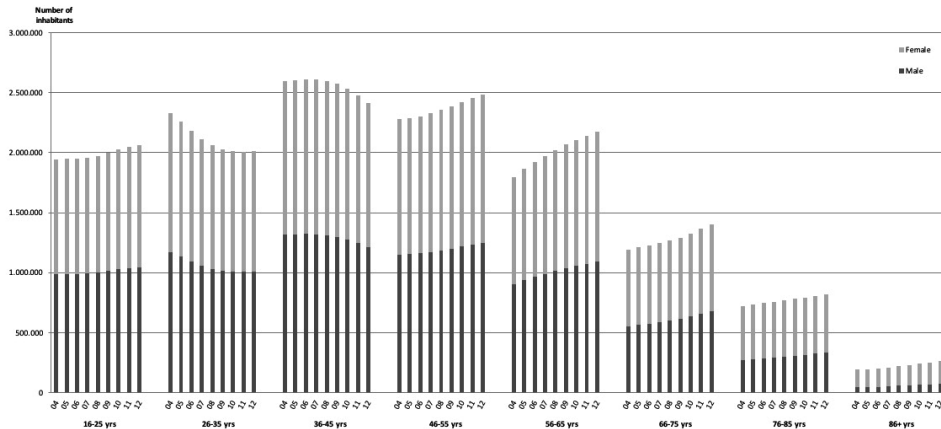


Figure 1: Mid-year population per age category in the Netherlands (Figure corresponds with table 1) For every year the growth per age category were calculated with a weighed binary regression analysis, with 2014 as reference category. For the total population a multinomial logistic regression analysis was used, with 2014 as reference category. source: Dutch Central Bureau of Statistics The 95% confidence intervals of 2012 compared to 2004, all with a P-value of < 0.001, were respectively: 1.018 [1.016 – 1.020] for age category 16-25 years; 0.798 [0.796 – 0.799] for age category 26-35 years; 0.867 [0.866 – 0.869] for age category 36-45 years; 1.050 [1.052 – 1.050] for age category 46-55 years; 1.191 [1.188 – 1.194] for age category 56-65 years; 1.136 [1.136 – 1.142] for age category 66-75 years; 1.093 [1.090 – 1.097] for age category 76-85 years; and 1.308 [1.300 – 1.315] for age category of 86 years and older. 1.004 [1.004 – 1.004] for the total population

Table 1: Mid-year population per age category in the Netherlands - Source: Dutch Central Bureau of Statistics

Age category	2004	2006	OR [95% CI]	2008	OR [95% CI]	2010	OR [95% CI]	2012	OR [95% CI]	P-value
16 - 25 yrs										
Number	1,943,057	1,952,652	0.997 [0.995 - 0.999]	1,974,580	0.999 [0.997 - 1.001]	2,027,876	1.013 [1.011 - 1.016]	2,061,970	1.018 [1.016 - 1.020]	< 0.001
Male n (%)	986,776 (51)	990,114 (51)	0.997 [0.993 - 1.001]	1,002,302 (51)	0.999 [0.995 - 1.003]	1,029,845 (51)	1.000 [0.996 - 1.004]	1,046,578 (51)	0.999 [0.995 - 1.003]	0.817
26 - 35 yrs										
Number	2,326,356	2,178,784	0.916 [0.959 - 0.963]	2,059,309	0.847 [0.845 - 0.848]	2,010,975	0.809 [0.808 - 0.811]	2,012,239	0.798 [0.796 - 0.799]	< 0.001
Male n (%)	1,173,076 (50)	1,092,286 (50)	0.988 [0.985 - 0.992]	1,029,544 (50)	0.983 [0.979 - 0.987]	1,008,549 (50)	0.989 [0.985 - 0.993]	1,010,246 (50)	0.991 [0.987 - 0.995]	< 0.001
36 - 45 yrs										
Number	2,594,389	2,610,982	0.999 [0.997 - 1.001]	2,597,907	0.981 [0.979 - 0.983]	2,532,150	0.933 [0.932 - 0.935]	2,415,823	0.867 [0.866 - 0.869]	< 0.001
Male n (%)	1,316,785 (51)	1,322,746 (51)	0.996 [0.993 - 1.000]	1,312,913 (51)	0.991 [0.988 - 0.995]	1,275,977 (50)	0.986 [0.982 - 0.989]	1,212,199 (50)	0.977 [0.974 - 0.981]	< 0.001
46 - 55 yrs										
Number	2,281,489	2,303,412	1.003 [1.001 - 1.005]	2,357,966	1.020 [1.018 - 1.022]	2,422,238	1.035 [1.033 - 1.037]	2,487,028	1.050 [1.052 - 1.050]	< 0.001
Male n (%)	1,153,237 (51)	1,160,898 (50)	0.994 [0.990 - 0.998]	1,186,262 (50)	0.990 [0.987 - 0.994]	1,218,355 (50)	0.990 [0.987 - 0.994]	1,251,553 (50)	0.991 [0.988 - 0.995]	< 0.001
56 - 65 yrs										
Number	1,795,089	1,920,887	1.073 [1.070 - 1.075]	2,018,511	1.125 [1.122 - 1.127]	2,105,724	1.162 [1.160 - 1.165]	2,177,779	1.191 [1.188 - 1.194]	< 0.001
Male n (%)	901,939 (50)	966,217 (50)	0.994 [0.990 - 0.998]	1,014,447 (50)	0.990 [0.989 - 0.994]	1,056,590 (50)	0.990 [0.987 - 0.994]	1,090,792 (50)	0.991 [0.988 - 0.995]	< 0.001
66 - 75 yrs										
Number	1,194,231	1,229,187	1.024 [1.021 - 1.027]	1,267,519	1.048 [1.046 - 1.051]	1,327,287	1.086 [1.083 - 1.088]	1,403,940	1.136 [1.136 - 1.142]	< 0.001
Male n (%)	552,893 (46)	576,116 (47)	1.023 [1.018 - 1.028]	601,370 (47)	1.047 [1.042 - 1.052]	636,528 (48)	1.069 [1.064 - 1.074]	678,721 (48)	1.086 [1.080 - 1.091]	< 0.001
76 - 85 yrs										
Number	719,262	749,179	1.036 [1.032 - 1.039]	770,429	1.057 [1.053 - 1.060]	792,509	1.072 [1.069 - 1.076]	817,825	1.093 [1.090 - 1.097]	< 0.001
Male n (%)	269,346 (37)	285,903 (38)	1.031 [1.024 - 1.038]	301,305 (39)	1.073 [1.066 - 1.080]	317,849 (40)	1.119 [1.111 - 1.126]	336,559 (41)	1.168 [1.161 - 1.176]	< 0.001

86 + yrs	Number	193,145	199,769	1,021	222,287	1,134	243,504	1,226	262,808	1,308	<
				[1.031 – 1.034]		[1.127 – 1.141]		[1.219 – 1.233]		[1.300 – 1.315]	0.001
	Male n	48,925	51,384	1,021	59,262	1,072	67,240	1,124	74,702	1,171	<
	(%)	(25)	(26)	[1.006 – 1.036]	(27)	[1.057 – 1.087]	(28)	[1.109 – 1.140]	(28)	[1.155 – 1.186]	0.001
Total	Number	13,047,018	13,144,852	1,001	13,268,508	1,002	13,462,263	1,003	13,639,412	1,004	<
population				[1.001 – 1.001]		[1.002 – 1.003]		[1.003 – 1.003]		[1.004 – 1.004]	0.001
	Male n	6,402,977	6,445,664	0.998	6,507,405	0.999	6,610,933	1.001	6,701,350	1.002	<
	(%)	(49)	(49)	[0.997 – 1.000]	(49)	[0.997 – 1.000]	(49)	[1.000 – 1.003]	(49)	[1.001 – 1.004]	0.001

Table 1 corresponds with Figure 1. For every year the growth per age category was calculated with a weighed binary regression analysis, with 2014 as reference category. For the total population, a multinomial logistic regression analysis was used, with 2014 as reference category. Source: Dutch Central Bureau of Statistics

Incidence

Figures 2 and 3 show the average incidence of fractures of the upper and lower extremities per age category. Overall, the incidence of extremity fractures is bimodal with peaks in both younger and older age categories. In younger age categories from 16-35 years, fractures of the extremities were more frequent in men than in women. Contrarily, in older age categories from 66 years and older, the incidences of fractures in women exceeded those in men.

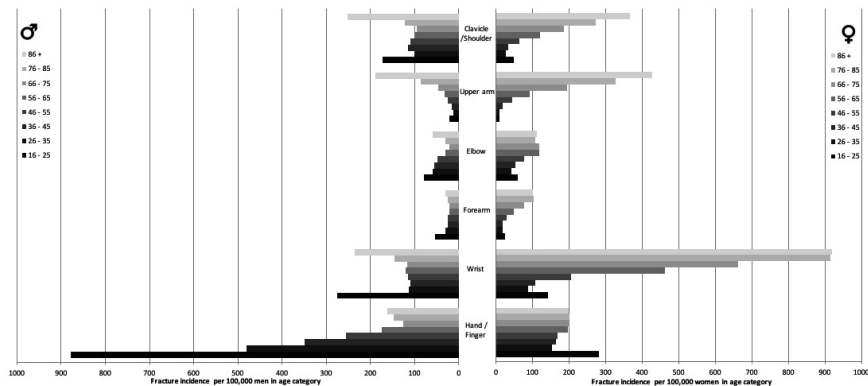


Figure 2: Average incidence of upper extremity fractures per sex and age category from the period 2004-2012. Source: Dutch Injury Surveillance System (DISS)

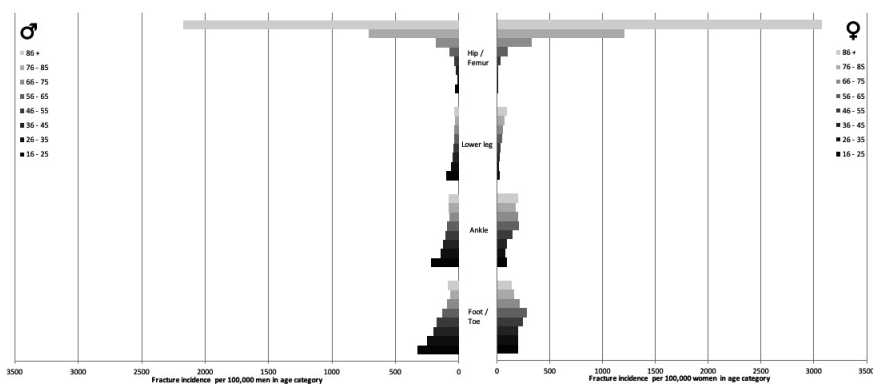


Figure 3: Average incidence of lower extremity fractures per sex and age category from the period 2004-2012. Source: Dutch Injury Surveillance System (DISS)

Table 2 and figures 4 and 5 show the incidence and absolute number of fractures in the study period, as well as the treatment facility (university versus non-university hospital) and type of treatment (surgical versus non-surgical). Figure 6 shows the incidence and absolute number of patients with one or more fractures in the study period, as well as the treatment facility (university versus non-university hospital) and type of treatment (surgical versus non-surgical).



During the study period, there was a significant increase in the absolute number of fractures in all types, except for forearm and lower leg fractures, which showed a decrease. The incidence in wrist, hand/finger, hip/upper leg, ankle and foot/toe fractures increased with 3-4% in 2012 compared with 2004.

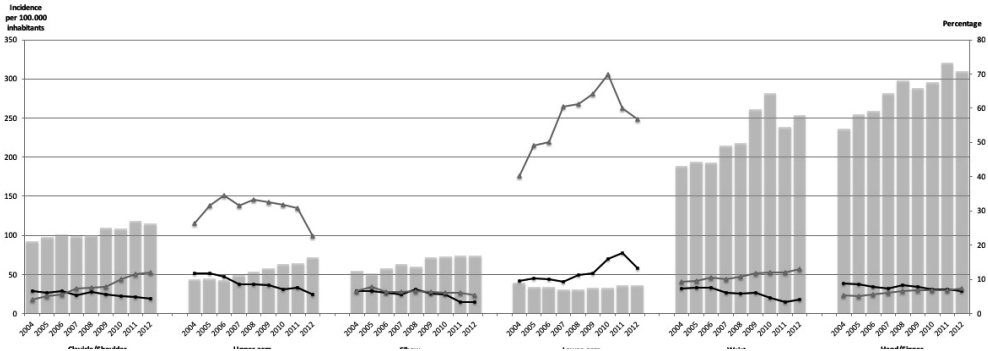


Figure 4: Incidence trends of upper extremity fractures (Figure corresponds with table 2) Incidence rates (left Y-axis), percentage patients treated in a university hospital (right Y-axis) & percentage surgically treated patients (right Y-axis) of upper extremity fractures in the period from 2004-2012 in the Netherlands

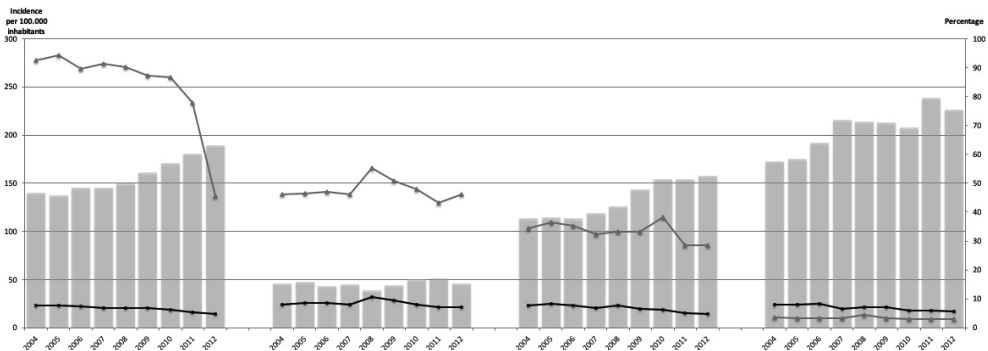


Figure 5: Incidence trends of lower extremity fractures (Figure corresponds with table 2) Incidence rates (left Y-axis), percentage patients treated in a university hospital (right Y-axis) & percentage surgically treated patients (right Y-axis) of lower extremity fractures in the period from 2004-2012 in the Netherlands.

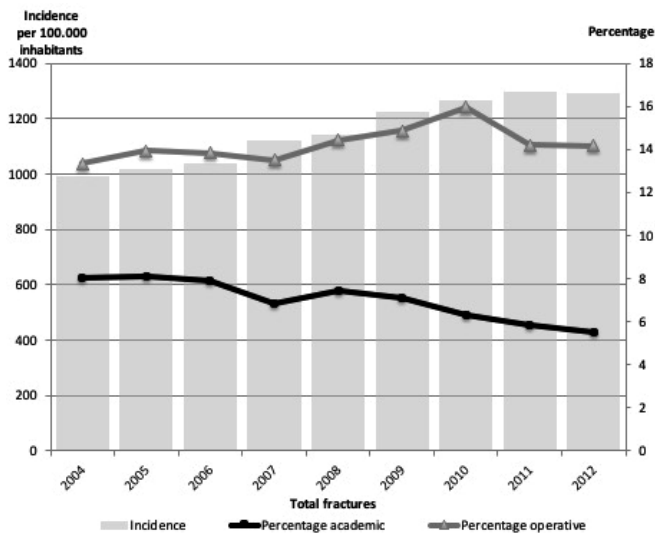


Figure 6: Incidence trend of the total of extremity fractures (Figure corresponds with table 2) Incidence rates (left Y-axis), percentage patients treated in a university hospital (right Y-axis) & percentage surgically treated patients (right Y-axis) of extremity fractures in the period from 2004-2012 in the Netherlands

Treatment location

Forearm fractures were treated more often in university hospitals (OR 1.430 [1.267 – 1.625] in 2012). For all other fracture types, a trend towards more treatments in non-university hospitals was seen.

Type of treatment

An increase was observed in both absolute and relative numbers of surgically treated clavicle/shoulder, forearm, wrist and hand fractures. The increase in surgical treatment of clavicle/shoulder fractures was most prominent (OR 3.168 [2.863 – 3.505] in 2012). Contrarily, treatment of lower extremity fractures remained more or less the same (lower leg fractures; 46-55% surgical treatment) or showed more non-surgical treatments. On top of an already apparent decrease of surgical treatment of hip and upper leg fractures over the years 2006-2010 (OR 0.688 – 0.528 in 2006-2010), an additional decrease was seen in 2012 (OR 0.068 [0.064-0.072]).

Table 2a: Epidemiology of upper extremity fractures – Sources: Dutch Injury Surveillance System (DISS), Statistics Netherlands, Dutch Hospital Data.

Fracture location	2004	2006	OR [95% CI]	2008	OR [95% CI]	2010	OR [95% CI]	2012	OR [95% CI]	P-value
Clavicle/Shoulder										
Number	12,115	13,264	1.09 [1.06 – 1.11]	13,348	1.08 [1.06 – 1.11]	14,606	1.17 [1.14 – 1.20]	15,738	1.24 [1.21 – 1.27]	< 0.001
Incidence	93	101	1.09 [0.82 – 1.44]	101	1.09 [0.82 – 1.44]	108	1.16 [0.88 – 1.53]	115	1.24 [0.94 – 1.63]	0.701
University hospital n (%)	799 (7)	880 (7)	1.01 [0.91 – 1.11]	844 (6)	0.96 [0.87 – 1.06]	744 (5)	0.76 [0.69 – 0.84]	691 (4)	0.65 [0.59 – 0.72]	< 0.001
Surgical treatment n (%)	505 (4)	731 (6)	1.34 [1.19 – 1.51]	1,003 (8)	1.87 [1.67 – 2.09]	1,480 (10)	2.59 [2.34 – 2.88]	1,906 (12)	3.17 [2.86 – 3.51]	< 0.001
Upper arm										
Number	5,770	5,678	0.98 [0.94 – 1.01]	7,098	1.21 [1.17 – 1.25]	8,497	1.43 [1.38 – 1.48]	9,849	1.63 [1.58 – 1.69]	< 0.001
Incidence	44	43	0.98 [0.64 – 1.49]	53	1.21 [0.81 – 1.80]	63	1.43 [0.97 – 2.11]	72	1.64 [1.13 – 2.38]	0.057
University hospital n (%)	682 (12)	616 (11)	0.91 [0.81 – 1.02]	604 (9)	0.69 [0.62 – 0.78]	597 (7)	0.56 [0.50 – 0.63]	563 (6)	0.45 [0.40 – 0.51]	< 0.001
Surgical treatment n (%)	1,529 (26)	1,960 (35)	1.46 [1.35 – 1.58]	2,358 (33)	1.38 [1.28 – 1.49]	2,706 (32)	1.30 [1.20 – 1.40]	2,234 (23)	0.81 [0.76 – 0.88]	< 0.001
Elbow										
Number	7,212	7,625	1.05 [1.02 – 1.08]	7,998	1.09 [1.06 – 1.13]	9,866	1.33 [1.29 – 1.37]	10,146	1.35 [1.31 – 1.39]	< 0.001
Incidence	55	58	1.06 [0.73 – 1.53]	60	1.09 [0.76 – 1.57]	73	1.33 [0.94 – 1.88]	74	1.35 [0.95 – 1.91]	0.298
University hospital n (%)	468 (6)	469 (6)	0.94 [0.83 – 1.08]	558 (7)	1.08 [0.95 – 1.23]	556 (6)	0.86 [0.76 – 0.98]	343 (3)	0.50 [0.44 – 0.58]	< 0.001
Surgical treatment n (%)	473 (7)	492 (6)	0.98 [0.86 – 1.12]	535 (7)	1.02 [0.90 – 1.16]	601 (6)	0.92 [0.82 – 1.05]	543 (5)	0.81 [0.71 – 0.91]	< 0.001
Forearm										
Number	5,149	4,480	0.86 [0.83 – 0.90]	4,100	0.78 [0.75 – 0.82]	4,430	0.83 [0.80 – 0.87]	4,906	0.91 [0.88 – 0.95]	< 0.001
Incidence	39	34	0.87 [0.55 – 1.38]	31	0.80 [0.50 – 1.27]	33	0.85 [0.53 – 1.35]	36	0.92 [0.59 – 1.45]	0.993
University hospital n (%)	493 (10)	453 (10)	1.06 [0.93 – 1.22]	466 (11)	1.21 [1.06 – 1.39]	714 (16)	1.82 [1.61 – 2.05]	647 (13)	1.44 [1.27 – 1.63]	< 0.001
Surgical treatment n (%)	2,072 (40)	2,249 (50)	1.50 [1.38 – 1.62]	2,509 (61)	2.34 [2.15 – 2.55]	3,095 (70)	3.45 [3.17 – 3.75]	2,787 (57)	1.95 [1.80 – 2.11]	< 0.001



Wrist	Number	24,613	25,432	1.03 [1.01 – 1.04]	28,903	1.16 [1.14 – 1.41]	37,945	1.50 [1.47 – 1.52]	34,666	1.39 [1.33 – 1.37]	< 0.001
	Incidence	189	193	1.02 [0.84 – 1.25]	218	1.15 [0.95 – 1.40]	282	1.49 [1.24 – 1.80]	254	1.35 [1.11 – 1.62]	< 0.001
	University hospital n (%)	1,816 (7)	1,952 (8)	1.04 [0.98 – 1.12]	1,670 (6)	0.77 [0.72 – 0.83]	1,773 (5)	0.62 [0.58 – 0.66]	1,417 (4)	0.54 [0.50 – 0.58]	< 0.001
	Surgical treatment n (%)	2,297 (9)	2,709 (11)	1.16 [1.09 – 1.23]	3,131 (11)	1.18 [1.12 – 1.25]	4,585 (12)	1.34 [1.27 – 1.41]	4,516 (13)	1.46 [1.38 – 1.54]	< 0.001
Hand/ Finger	Number	30,913	34,144	1.10 [1.08 – 1.11]	39,540	1.26 [1.24 – 1.28]	39,805	1.25b [1.23 – 1.27]	42,268	1.31 [1.29 – 1.33]	< 0.001
	Incidence	237	260	1.10 [0.92 – 1.31]	298	1.26 [1.06 – 1.49]	296	1.25 [1.05 – 1.48]	310	1.31 [1.11 – 1.55]	0.006
	University hospital n (%)	2,692 (9)	2,684 (8)	0.89 [0.85 – 0.95]	3,250 (8)	0.94 [0.89 – 0.99]	2,824 (7)	0.80 [0.76 – 0.85]	2,822 (7)	0.75 [0.71 – 0.79]	< 0.001
	Surgical treatment n (%)	1,671 (5)	1,935 (6)	1.05 [0.98 – 1.13]	2,560 (6)	1.21 [1.14 – 1.29]	2,722 (7)	1.29 [1.21 – 1.37]	3,063 (7)	1.37 [1.29 – 1.45]	< 0.001

P-values were calculated with a weighed binary regression analysis, with 2014 as reference category

Discussion

This study shows a significant increase in both incidence and absolute numbers of wrist, hand/finger, hip/upper leg, ankle and foot/toe fractures during a recent nine-year study period. In addition, there is a trend towards more surgical treatments of shoulder/clavicle and wrist/hand fractures. For lower extremity fractures a decrease in surgical treatment was observed. A trend towards treatment in non-university hospitals was observed for all except forearm fractures.

The increasing trends in surgical treatment reported in some extremity fractures are not unique for our country. The increase found in surgically treated upper extremity fractures is similar to a study from Finland in 2013, showing an increase of surgically treated clavicle fractures from 1.3 per 100,000 person years (n=48) in 1987 to 10.8 per 100,000 person years (n=462) in 2010.⁷

Additionally, the bimodal incidence across the different age categories are similar to those in a recent study by Court-Brown et al.⁹ Incidences reported in our study are higher than in a population-based epidemiologic study of the upper extremities in the USA, reporting a total of 677 per 100,000 upper extremity fractures in 2009 compared to 824 per 100,000 in our study.¹⁸ In contrast to the USA, in the Netherlands health insurance for all Dutch inhabitants was mandatory during the study period. Therefore, the threshold to seek help for extremity fractures may have been lower compared to the USA.

The increase in absolute numbers of fractures could be explained by the growth of our population. Changes in the incidences of specific extremity fractures are probably better explained by changes in the composition of our population. Most fractures have a peak incidence in the younger and older age categories. These age categories are growing, whereas the age categories less prone to fractures are actually decreasing in number.

Strengths of this study include the fact that this study gives a unique nationwide overview of all extremity fractures over a longer, continuous period. This distinguishes this study from the majority of similar epidemiological studies that focus on a specific fracture type 6,7,10,19–21 or describe the incidence within a single hospital.^{9,22}

Recently published Dutch insurance data on the incidence of distal radius fractures reported a total of 49,615 distal radius fractures in 2012, compared to 34,666 wrist fractures in our study.²³ Despite this difference in absolute numbers, the percentage of patients treated surgically is similar (9-10%). A potential explanation for the difference in incidence could be overestimation of the insurance data due to double registration, when patients are referred to other hospitals or specialties. Nonetheless, the similarity suggests this estimate approximates reality.

Additionally, we aimed to improve accuracy and facilitate verification of observed trends by combining different databases, which separately have shown to have a high level of accuracy and validity.^{15,16} Despite the high quality of the databases used, the use of their data has some limitations. For example, the DISS registers all injuries that are recorded at

Table 2b: Epidemiology of lower extremity and all patients with one or more extremity fracture – Sources: Dutch Injury Surveillance System (DISS), Statistics Netherlands, Dutch Hospital Data.

Fracture location		2004	2006	OR [95% CI]	2008	OR [95% CI]	2010	OR [95% CI]	2012	OR [95% CI]	P-value
Hip/ Up- per leg	Number	18,301	19,163	1.04 [1.02 – 1.06]	19,897	1.07 [1.05 – 1.09]	22,966	1.22 [1.19 – 1.24]	25,796	1.35 [1.32 – 1.36]	< 0.001
	Incidence	140	146	1.04 [0.83 – 1.32]	150	1.07 [0.85 – 1.35]	171	1.22 [0.98 – 1.53]	189	1.35 [1.09 – 1.68]	0.025
Lower leg	University hospital n (%)	1,395 (8)	1,410 (7)	0.96 [0.89 – 1.04]	1,342 (7)	0.88 [0.81 – 0.95]	1,431 (6)	0.81 [0.75 – 0.87]	1,205 (5)	0.59 [0.55 – 0.64]	< 0.001
	Surgical treatment n (%)	16,935 (93)	17,153 (90)	0.69 [0.64 – 0.74]	17,924 (90)	0.73 [0.68 – 0.79]	19,923 (87)	0.53 [0.44 – 0.56]	11,793 (46)	0.07 [0.06 – 0.07]	< 0.001
	Number	6,045	5,717	0.94 [0.91 – 0.97]	5,216	0.85 [0.82 – 0.88]	6,758	1.08 [1.05 – 1.12]	6,226	0.99 [0.95 – 1.02]	< 0.001
	Incidence	46	43	0.94 [0.62 – 1.42]	39	0.85 [0.55 – 1.30]	50	1.09 [0.73 – 1.62]	46	1.00 [0.66 – 1.51]	0.969
	University hospital n (%)	489 (8)	487 (9)	1.06 [0.93 – 1.21]	550 (11)	1.34 [1.18 – 1.52]	545 (8)	1.00 [0.88 – 1.13]	451 (7)	0.89 [0.78 – 1.01]	< 0.001
	Surgical treatment n (%)	2,793 (46)	2,691 (47)	1.04 [0.96 – 1.08]	2,888 (55)	1.44 [1.34 – 1.56]	3,229 (48)	1.07 [0.99 – 1.14]	2,882 (46)	1.00 [0.94 – 1.08]	< 0.001

Ankle	Number	14,803	14,961	1.00 [0.98 – 1.03]	16,711	1.11 [1.09 – 1.14]	20,744	1.36 [1.33 – 1.39]	21,487	1.39 [1.36 – 1.42]	< 0.001
	Incidence	113	114	1.01 [0.78 – 1.31]	126	1.12 [0.87 – 1.44]	154	1.36 [1.07 – 1.74]	158	1.40 [1.10 – 1.78]	0.005
	University hospital n (%)	1,135 (8)	1,162 (8)	1.01 [0.93 – 1.10]	1,309 (8)	1.02 [0.94 – 1.11]	1,276 (6)	0.79 [0.73 – 0.86]	1,060 (5)	0.63 [0.57 – 0.68]	< 0.001
	Surgical treatment n (%)	5,107 (35)	5,268 (35)	1.03 [0.98 – 1.08]	5,556 (33)	0.95 [0.90 – 0.99]	7,961 (38)	1.18 [1.13 – 1.24]	6,107 (28)	0.75 [0.72 – 0.79]	< 0.001
Foot/Toe	Number	22,568	25,218	1.11 [1.09 – 1.13]	28,379	1.24 [1.22 – 1.26]	28,022	1.20 [1.18 – 1.23]	30,844	1.31 [1.29 – 1.33]	< 0.001
	Incidence	173	192	1.11 [0.90 – 1.36]	214	1.24 [1.01 – 1.51]	208	1.20 [0.98 – 1.47]	226	1.31 [1.07 – 1.59]	0.016
	University hospital n (%)	1,832 (8)	2,128 (8)	1.04 [0.98 – 1.11]	2,028 (7)	0.87 [0.82 – 0.93]	1,690 (6)	0.73 [0.68 – 0.78]	1,748 (6)	0.68 [0.64 – 0.73]	< 0.001
	Surgical treatment n (%)	792 (4)	836 (3)	0.94 [0.85 – 1.04]	1,276 (4)	1.29 [1.18 – 1.42]	888 (3)	0.90 [0.82 – 0.99]	937 (3)	0.86 [0.78 – 0.95]	< 0.001
All Fractures	Number	129,188	136,519	1.05 [1.04 – 1.06]	151,293	1.15 [1.15 – 1.16]	170,673	1.28 [1.28 – 1.29]	176,129	1.31 [1.30 – 1.32]	< 0.001
	Incidence	990	1,039	1.05 [0.96 – 1.15]	1,140	1.15 [1.06 – 1.26]	1,268	1.28 [1.18 – 1.40]	1,291	1.31 [1.20 – 1.42]	< 0.001
	University hospital n (%)	10,406 (8)	10,831 (8)	0.98 [0.96 – 1.01]	11,280 (7)	0.92 [0.89 – 0.95]	10,719 (6)	0.7 [0.744 – 0.787]	9,741 (6)	0.67 [0.65 – 0.69]	< 0.001
	Surgical treatment n (%)	17,239 (13)	18,870 (14)	1.04 [1.10 – 1.07]	21,816 (14)	1.09 [1.07 – 1.12]	27,268 (16)	1.24 [1.21 – 1.26]	24,975 (14)	1.07 [1.05 – 1.10]	< 0.001

P-values were calculated with a weighed binary regression analysis, with 2014 as reference category

the ED but fails to register changes in diagnosis after the ED visit. The DHD uses only the main (often the most severe) diagnosis at discharge. In multiple injured patients, not all injuries are registered, potentially leading to an underestimation of fracture incidence. Correction for this under-registration allows extrapolation to national fracture incidences but could still slightly deviate from the actual number of fractures, treatment location and type.

Currently in the Netherlands, there is a trend to concentrate different types of care in specialized hospitals, leading to more referrals after primary presentation at the ED. Hip/upper leg fractures, for example, are preferably referred to non-university hospitals, while multiple injured patients are presented at university level-one hospitals. It is unclear how these changes in hospital logistics affect the representativeness of the DISS.

An unexpected additional decline was observed in an already decreasing trend in surgical treatment of hip/upper leg and upper arm fractures in 2012. The decreasing trend in surgical treatment could potentially be granted to successful osteoporosis prevention programs, leading to more stable fractures, not requiring surgery.¹² A second explanation for this sudden drop could be the effect of an additional 7% missing data in the DHD in 2012. These additional missing data were mainly from patients aged 70 years and older. Subsequently, these missing data could have biased our results about the management of fractures with high incidences in the elderly in 2012.

During the study period from 2004 to 2012, we observed an increasing incidence of extremity fractures and a trend towards surgical treatment mainly performed in non-university hospitals. If, in the future, these trends continue, policy makers would be well advised to anticipate changing demands in extremity fracture treatment and pro-actively adjust capacity and resources.

Table 3: ICD coding of fracture locations

Fracture location	ICD-codes	Fracture location	ICD-codes
Clavicle/Shoulder	810.00	Hip/Upper leg	820.00
	810.10		820.10
	810.20		820.20
	811.10		820.30
Upper arm	812.00		820.80
	812.10		820.90
	812.20		821.00
	812.30		820.10
Elbow	812.40		905.30
	812.50		823.00
Lower arm	813.00	823.10	
	813.10	823.20	
	813.30	Lower leg	
	813.80	823.30	
	813.90	823.80	
	813.40	823.90	
Wrist	813.50	824.00	
	814.00	824.10	
	814.10	824.20	
	814.70	824.30	
	814.70	824.40	
Hand/Finger	815.00	Ankle	
	815.10	824.50	
	816.00	824.60	
	816.10	824.70	
	817.00	824.80	
	817.10	824.90	
	817.10	825.00	
	825.10		
	Foot/Toe		
	825.20		
	825.30		
	826.00		
	826.10		

ICD-10-codes as used in both the Dutch Injury Surveillance System (DISS) as Dutch Hospital Data (DHD)

References

1. De Putter C.E., Selles R.W., Polinder S. Economic Impact of Hand and Wrist Injuries: Health-Care Costs and Productivity Costs in a Population-Based Study. *The Journal of Bone and Joint Surgery (American Volume)* 2012; 94: e56.
2. Meerding W.J., Mulder S., Van Beeck E.F. Incidence and costs of injuries in The Netherlands. *European Journal of Public Health* 2006; 16: 271–277.
3. Buckley R., Moran C.G., Apivattthakakul T. *AO Principles of fracture treatment*. Thieme Medical Publishers, 01/2011, 2018.
4. Polinder S., Haagsma J., Panneman M., et al. The economic burden of injury: Health care and productivity costs of injuries in the Netherlands. *Accident; Analysis and Prevention* 2016; 93: 92–100.
5. Court-Brown C.M., Aitken S., Hamilton T.W., et al. Nonoperative Fracture Treatment in the Modern Era. *The Journal of Trauma* 2010; 69, 699–707.
6. Mattila V.M., Huttunen T.T., Sillanpää P., et al. Significant change in the surgical treatment of distal radius fractures: A nationwide study between 1998 and 2008 in Finland. *The Journal of Trauma* 2011; 71: 939–42.
7. Huttunen T.T., Kannus P., Lepola V., et al. Surgical treatment of clavicular fractures in Finland – A register based study between 1987 and 2010. *Injury* 2013; 44: 1899–1903.
8. Mellstrand-Navarro C., Pettersson H.J., Tornqvist H., et al. The operative treatment of fractures of the distal radius is increasing: Results from a nationwide Swedish study. *The Bone & Joint Journal* 2014; 96-B: 963–9.
9. Court-Brown C.M., Caesar, B. Epidemiology of adult fractures: A review. *Injury* 2006; 37: 691–697.
10. Oskam J., Kingma J., Klasen H. J. Fracture of the distal forearm: Epidemiological developments in the period 1971-1995. *Injury* 1998; 29: 353–355.
11. Court-Brown C. M., Clement N.D., Duckworth A.D., et al. The spectrum of fractures in the elderly. *The Bone and Joint Journal (British volume)* 2014; 96-B: 366–72.
12. Hartholt K.A., Oudshoorn C., Zielinski S.M., et al. The Epidemic of Hip Fractures: Are We on the Right Track? *PloS one* 2011; 6: e22227.
13. Statistics Netherlands. Available at: <http://www.cbs.nl/nl-NL/menu/cijfers/default.htm>. (Accessed: 3rd of January 2016)
14. Dutch Injury Surveillance System. Available at: <https://www.veiligheid.nl/organisatie/wat-we-doen/onderzoek>. (Accessed: 3rd of January 2016)
15. Lyons R.A., Polinder S., Larsen C.F., et al. Methodological issues in comparing injury incidence across countries. *International Journal of Injury Control and Safety Promotion* 2006; 13: 63–70.
16. Meerding W.J., Polinder S., Lyons R.A., et al. How adequate are emergency department home and leisure injury surveillance systems for cross-country comparisons in Europe? *International Journal of Injury Control and Safety Promotion* 2010; 17: 13–22.

17. Dutch Hospital Data. Available at: <https://www.dhd.nl/klanten/Paginas/home.aspx>. (Accessed: 3rd of January 2016)
18. Karl J.W., Olson P.R., Rosenwasser M.P. The Epidemiology of Upper Extremity Fractures in the United States, 2009. *Journal of Orthopaedic Trauma* 2015; 29: e242–4.
19. Shauver M.J., Yin H., Banerjee M., et al. Current and future national costs to medicare for the treatment of distal radius fracture in the elderly. *The Journal of Hand Surgery (American volume)* 2011; 36: 1282–7.
20. Maravic M., Taupin P., Landais P., et al. Hospitalized wrist fractures in France: Incidence and burden trend changes. *Orthopaedics & Traumatology Surgery & Research* 2010; 9: 661–5.
21. De Putter C.E., Selles R.W., Polinder S., et al. Epidemiology and health-care utilisation of wrist fractures in older adults in The Netherlands, 1997–2009. *Injury* 2013; 44: 421–6.
22. Duckworth A.D., Clement N.D., Aitken S.A., et al. The epidemiology of fractures of the proximal ulna. *Injury* 2012; 43: 343–6
23. Walenkamp M.M.J., Mulders M.A.M., Goslings J.C., et al. Analysis of variation in the surgical treatment of patients with distal radial fractures in the Netherlands. *The Journal of Hand Surgery (European Volume)* 2017; 42: 39–44.



Part I

The radiologic evaluation of extremity fractures



Chapter 2

How to evaluate the quality of fracture
reduction and fixation of the wrist and
ankle in clinical practice:
A Delphi consensus

M.S.H. Beerekamp, R. Haverlag, D.T. Ubbink, J.S.K. Luitse,
K.J. Ponsen, J.C. Goslings

Archives of Orthopaedic Trauma Surgery, 2011; 131: 739-46

Abstract

Introduction

At present, there is no generally accepted scoring protocol to qualify the radiological outcome of fracture reduction and fixation of the wrist or ankle. However, anatomical fracture reduction is recommended for an optimal clinical outcome of intra-articular fractures of the extremities. Well-defined criteria are fundamental to attain interobserver agreement and comparability between studies. The aim of this study was to obtain a practice-based consensus on the most important criteria for radiological evaluation of the fracture reduction and fixation of the wrist and ankle in the Netherlands.

Methods

A Delphi study was conducted to obtain consensus on the most important criteria for the radiological evaluation of the reduction and fixation of the wrist and ankle. The Delphi study consisted of a bipartite online questionnaire, focusing on the interpretation of radiographs and CT scans of the wrist and the ankle. Questions addressed imaging techniques, aspects of the anatomy and fracture reduction and fixation. Agreement was expressed as the percentage of respondents with similar answers. Consensus was defined as an agreement of at least 90%.

Results

In three Delphi rounds, respectively, 64, 74 and 62 specialists, consisting of radiologists, trauma and orthopedic surgeons from the Netherlands responded. After three Delphi rounds, consensus was reached for three out of 14 (21%) imaging techniques proposed, 11 out of the 13 (85%) anatomical aspects and 13 of the 22 (59%) items for the fracture reduction and fixation. This Delphi consensus differs from existing scoring protocols in terms of the greater number of anatomical aspects and aspects of fracture fixation requiring evaluation and is more suitable in clinical practice due to a lower emphasis on measurements.

Conclusion

Based on the clinical experience of specialists from different disciplines in the Netherlands, a broad consensus has been reached on how to evaluate wrist and ankle fracture reduction and fixation. In contrast with previous scoring systems, measurements do not take a prominent place in our findings. Therefore, we suggest a more practice-based scoring protocol, based on this consensus, in which the different items can be evaluated visually.

Introduction

At present, there is no generally accepted scoring protocol for the radiological evaluation of the quality of wrist or ankle fracture reduction and fixation, despite various angle and distance measurements described in the literature. According to AO recommendations, anatomical fracture reduction is desired for an optimal clinical outcome of intra-articular fractures of the extremities.¹ For both ankle and wrist, there are also indications that anatomical fracture reduction gives a significantly better outcome.²⁻⁵ Unfortunately, there is no consensus on which parameters predict symptomatic malunion and post-traumatic arthrosis most securely. Therefore, it remains unclear which criteria should be used to assess optimal fracture reduction and fixation.

For the wrist, the most common radiological parameters and their generally accepted thresholds for the reduction to be acceptable are radial shortening (< 5 mm), radial inclination ($> 15^\circ$), sagittal tilt on lateral projection (between 15° dorsal tilt and 20° volar tilt), intra-articular step-off (< 2 mm) of the radiocarpal joint and articular incongruity (< 2 mm of the sigmoid notch of the distal radius).⁶⁻⁹ Various combinations and permutations of these indices have been converted into scoring systems.^{10,11} Most of these scoring systems lack clinical sensitivity, however, and are therefore used infrequently.¹⁰ Two exceptions are the anatomical radiological classification for distal radial fractures according to Lidström and the deformity scoring system according to Gartland and Werley.^{12,13} The latter contains an objective component, consisting of radiological, clinical and functional assessment, as well as a subjective evaluation.¹³ Lidström's classification evaluates the wrist after a Colles' fracture and merely consists of the radiological assessment of dorsal angulation, radial length and radial inclination. The restoration of the anatomy of the distal radius is subsequently classified as a poor, fair, good or excellent result based on the aforementioned radiological measurements.^{12,14,15}

To assess fracture reduction of the ankle, different radiological evaluation methods are described in the literature. One of these methods is rank order analysis of the congruency, taking into consideration the entire fracture pattern.¹⁶ In some studies different aspects such as anatomical reduction of the tibial articular surface, joint congruency, talar shift, talar tilt or syndesmotic diastasis were subjectively scored from perfect to poor.^{4,17,18} Avodia et al. developed a classification method which included distance measurements of the malleoli and the tertius fragment, mortise widening, talar tilt and talar displacement.¹⁹ This classification was adjusted by Teeny et al. by assigning points to the different items, generating an overall score.^{20,21}

Evaluation of fracture reduction is confounded by the high interobserver variance, especially in the evaluation of plain radiographs.^{6,15,20,22} Grainger et al. showed interobserver agreement was higher for measurements of distances than for measurements of angles.²³ In contrast, Kreder et al. demonstrated a particularly high interobserver variance for distance measurements of intra-articular step and gap.²² Because available evidence is scarce regarding which parameters of the anatomical reduction and fixation influence clinical outcome and inter-observer measurement variation is high, no internationally accepted criteria exist to judge the quality of fracture reduction and fixation. Currently

the radiological evaluation of ankle and wrist fractures is based on the experience of the surgeon and/or radiologist and on their frame of reference. Well-defined criteria are fundamental to attain interobserver agreement and comparability between studies. The aim of this study was to obtain a practice-based consensus on the most important criteria for radiological evaluation of the fracture reduction and fixation of the wrist and ankle in the Netherlands.

Methods

The Delphi method was developed by the Rand Corporation. This method is considered an effective way to measure and obtain group consensus.²⁴⁻²⁷ It is a structured, anonymous and repeated process requiring experts to respond to nonleading, unambiguous statements on items pertinent to the topic.²⁵ To assess the level of agreement on useful criteria in the radiological evaluation of the ankle and wrist, a list of items was composed based on literature data and on the experience of the surgeons and radiologists. These items were divided into three main topics: (1) imaging technique, (2) evaluation of anatomical aspects of the operated joint, (3) fracture reduction and position of the fixation material.

Invited medical specialists

In the daily routine of many hospitals, different disciplines are involved in the radiological evaluation of ankles and wrists in fracture surgery. In the Netherlands, both trauma and orthopedic surgeons perform fracture surgery.²⁸ In order to achieve a broad-based consensus, we approached 225 Dutch medical specialists, including 75 trauma surgeons, 80 orthopedic surgeons and 70 radiologists. This sample was chosen from surgeons and radiologists working in university hospitals (8) and training and non-training hospitals (12). Because radiologists and surgeons in university hospitals have a super-specialization, we only approached radiologists from university hospitals that had expertise in skeletal evaluation and surgeons with expertise in open reduction and internal fixation (ORIF) of fractures of the extremities. In the training and non-training hospitals, all radiologists, trauma surgeons and orthopedic surgeons were invited to participate. The same specialists were invited to participate in the three Delphi rounds.

Delphi procedure

Three Delphi rounds involving an online questionnaire were scheduled. The invitations, consisting of a statement to motivate participation in this study, an explanation of the Delphi procedure and a link to the URL of the online questionnaire, were sent by email. The private e-mail addresses were obtained from most specialists (n= 177). Other emails inviting participation were sent to the secretary of the particular department, who then forwarded the e-mail to the specialists. If the specialist did not reply, up to three reminders were sent every 2 weeks. The first questionnaire consisted of two parts. The first part contained questions about the ankle, while the second part pertained to the wrist. The questionnaire included both multiple-choice and open questions about the aforementioned criteria. The imaging questions were intended to identify how often the respondents, in case of a suspected fracture and after fracture surgery, used the imaging modalities and techniques. In the open questions, the specialists were asked to provide a top-six list of aspects of the joint, which, in their opinion, required evaluation.

In the remaining open questions, the respondents were given the opportunity to include remarks and suggestions for other criteria. Pictures of the different measurements were added for clarification.

The second questionnaire was constructed using the results of the first questionnaire, incorporating remarks and suggestions. As with the first questionnaire, this was a bipartite questionnaire with one section relating to the ankle and the other relating to the wrist. A histogram presenting the relevant results from the first questionnaire was included in the introduction of each question. Multiple-choice questions were used to ask about imaging techniques, the evaluation of the joint and reduction and fixation. Questions about the evaluation of aspects of the joint anatomy were divided into a main question about the importance of a particular aspect of the joint and a sub-question on how to evaluate this aspect.

The third questionnaire was fueled by the results of the second questionnaire and consisted of questions on which no consensus was reached yet. These questions were posed in the same manner and same order as the second questionnaire. In the introduction, the respondents were urged to reach agreement. If agreement on an item had been reached in the second questionnaire, this was reported and no new, similar question was posed.

Statistical analysis

The number of similar answers was divided by the number of respondents and expressed as a percentage. For the criteria concerning imaging technique and reduction and fixation, consensus was defined as an agreement of at least 90%. For the main evaluation of aspects of the anatomy, consensus was also defined as 90% agreement. Because there are different ways of assessing these aspects, a lower consensus was expected and therefore consensus on the sub-question on how to assess a particular anatomical aspect was defined as an agreement of at least 80%.

Results

Response rate

The first Delphi round started in August 2007. There were 64 respondents (Table 1). The experience as a specialist ranged from 0 years to more than 20 years, spread almost equally across five groups of years of experience (0–5; 5–10; 10–15; 15–20; >20 years). As summarized in Table 1, 141 specialists did not respond to the questionnaire, giving no reason for non-participation. Specialists, who replied that they did not want to participate, were removed from our mailing list. Reasons given for not participating were the lack of relevance of the wrist or ankle to their field of interest or lack of time. In the reminders of the first Delphi round we included a small incentive to reply (a dinner check was to be raffled), but with little result.

The second round started in January 2008 and the third in May 2008, using the same mailing list as the first round. In these rounds, respectively, 72 and 62 specialists responded to our questionnaire. A total of 42 specialists completed all three questionnaires.

Table 1: Response rate

Delphi Round	Response rate specialists (n)							Total invited
	Trauma Surgeon	Orthopaedic Surgeon	Radiologist	Unknown specialism	Delivery failure ¹	No participation ²	No response	
I	34	18	12	0	14	6	141	225
II	33	22	12	5	2	8	137	219
III	32	17	13	0	1	3	145	211

¹Delivery failure was due to incorrect email addresses or full inboxes. Specialists received a reminder, or the correct email address was obtained.

²Specialists who returned a mail to inform us they did not want to participate were removed from our mailing list.

Agreement regarding radiological evaluation of the wrist

An overview of the consensus on radiological evaluation of the wrist is given in Table 2. Posterior-Anterior (PA) radiographs and lateral radiographs are the required imaging techniques for the standard evaluation of the wrist. Consensus on these items was reached already in the second Delphi round. Although the majority of the respondents indicated that an oblique PA-view or a radiograph of the contralateral wrist is not required in the standard evaluation, this majority did not reach the 90% cut-off value. A small majority stated that both preoperative and postoperative CT scans are only required selectively. Reported indications for a preoperative CT scan included the need for greater insight into complicated intra-articular fractures or optimal operation planning. Indications for a postoperative CT scan included uncertainty about the fracture reduction or position of the fixation material.

For the evaluation of the wrist in general, no consensus could be reached on the necessity of measurements when assessing the anatomy of the wrist. The same held true for visual assessment. Consensus was already reached in the second Delphi round for all but one of the proposed evaluation criteria. Consensus could not be reached on the need to assess the relationship between the radius and the (meta)carpal bones, although there was 86% agreement on the importance of this aspect. In terms of the relationship between radial and ulnar length, it is interesting to note that consensus was only reached on the importance of measuring dorsal angulation. For other measurements associated with this criterion, such as ulnar variance, radial length and radial angulation, no consensus was reached. For carpal height ratio, carporadial distance ratio and carpo-ulnar distance there was consensus that these items are not required in the evaluation of the wrist. No consensus could be reached on measurement of the radioulnar distance, ulnar translocation and the scapholunar angle. The respondents indicated that all evaluation criteria could be assessed visually.

In terms of fracture reduction and position of fixation material in the wrist, consensus was only reached in the second Delphi round on the need to evaluate the absence of intra-articular steps, gaps and bone fragments. Only a minority of specialists believed it was necessary to assess the absence of these aspects if it existed extra-articular. Consensus was reached on the importance of evaluating the position of plates and screw length. Unexpectedly, agreement on the evaluation of the bicortical presence of screws dropped

from 86% in the second round to 73% in the third Delphi round. Evaluation of the absence of protruding screws and/or K-wires was only considered relevant for intra-articular protrusion. However, no consensus could be reached on how to assess intra-articular protrusion, although 79% of the respondents agreed evaluation could be performed visually.

Table 2: Consensus regarding the radiological evaluation of the wrist

Consensus regarding the radiological evaluation of the wrist	
Required imaging technique	<ul style="list-style-type: none"> • A PA-view • A lateral view
Evaluation of the anatomy	<ul style="list-style-type: none"> • Congruency of the wrist <ul style="list-style-type: none"> - Pay attention to width of joint spaces - Pay attention to the symmetry of the joint spaces - Pay attention to the configuration of the carpal bones - Visual assessment • Relation between radius and ulna (ulnar variance) <ul style="list-style-type: none"> - Measure dorsal angulation - Visual assessment • Distance between the radius and the ulna at DRUJ <ul style="list-style-type: none"> - Visual assessment • Position of the carpal bones <ul style="list-style-type: none"> - Visual assessment • Relation between the carpal bones <ul style="list-style-type: none"> - Visual assessment
Fracture reduction & position of the fixation material	<ul style="list-style-type: none"> • Absence of intra-articular bone fragments • Absence of intra-articular gaps • Absence of intra-articular steps • Position of fixation plate(s) <ul style="list-style-type: none"> - Visual assessment • The length of screws and/or K-wires • Absence of intra-articular protruding screws/K-wires

The dots indicate the items on which consensus (> 90% agreement) was reached. The lines indicate how to evaluate these items (> 80% agreement).

Agreement regarding radiological evaluation of the ankle

An overview of the consensus is given in Table 3. In terms of the imaging techniques required for standard evaluation of the ankle, consensus was only reached on the standard use of the lateral radiograph (100%). Although the 90% cut-off was not reached for the importance of a mortise view (79%), it was preferred over an AP view, either an AP view or a mortise view, or both. A small majority (65%) preferred not to take radiographs of the contralateral ankle. For both the preoperative and postoperative CT scan, opinions were divided between no CT scans at all and selective CT scans. The indications mentioned here were the same as those given for the wrist.

In contrast with the evaluation of the wrist, there was 86% agreement that the general assessment of the ankle could be performed visually. A majority of the respondents (58%) considered that angle and distance measurements were not relevant to the general assessment. Consensus was already reached in the second Delphi round for all but one of

the proposed evaluation criteria, namely the rotation of the talus (only 50% agreement). For the congruency of the joint and the symmetry of the joint space, there was even a consensus of 100%. Measurement of the distance between the tibia and fibula was not considered relevant, nor was the measurement of the talocrural angle to determine the length of the fibula. No consensus could be reached for the need to draw Shentons' line to determine joint congruency, to perform measurements of the width of the joint space or to measure the overlap of the tibia and fibula on a mortise projection. The respondents felt that all the evaluation criteria could be assessed visually, except for the rotation of the fibula. Although there was consensus on the importance of evaluating the rotation of the fibula, no consensus could be reached on how this should be carried out. Although a 68% majority believed that measurement of the proposed Axial Malleolar Index (AMI) was not necessary for the evaluation of the rotation of the fibula, 61% also stated visual assessment was not sufficient. No further suggestions were given, however, on how to evaluate this aspect.

The results of the evaluation of the fracture reduction and fixation material in the ankle were similar to those in the wrist. The only exception was that for the ankle there was a consensus of 92% on the importance of assessing the bicortical presence of screws and/or K-wires.

Table 3: Consensus regarding the radiological evaluation of the ankle

Consensus regarding radiological evaluation of the ankle	
Required imaging technique	<ul style="list-style-type: none"> • A Mortise view* • A lateral view
Evaluation of the anatomy	<ul style="list-style-type: none"> • Congruency of the ankle <ul style="list-style-type: none"> - <i>Visual assessment</i> • Symmetry of the joint space <ul style="list-style-type: none"> - <i>Visual assessment</i> • Width of the joint space <ul style="list-style-type: none"> - <i>Visual assessment</i> • Distance between the tibia and fibula at the syndesmosis <ul style="list-style-type: none"> - <i>Pay attention to lateralization of the fibula</i> - <i>Visual assessment</i> • Length of the fibula <ul style="list-style-type: none"> - <i>Visual assessment</i> • Rotation of the fibula
Fracture reduction & position of the fixation material	<ul style="list-style-type: none"> • Absence of intra-articular bone fragments • Absence of intra-articular gaps • Absence of intra-articular steps • Position of fixation plates <ul style="list-style-type: none"> - <i>Visual assessment</i> • Position of the screws and/or K-wires in general • Bicortical presence of screws/K-wires • Absence of intra-articular protruding screws/K-wires

The dots indicate the items on which consensus (> 90% agreement) was reached. The lines indicate how to evaluate these items (> 80% agreement).

*Only a 79% agreement was reached to perform a Mortise-view, which did not reach the 90% threshold for consensus. Because the authors believe only a lateral projection for the evaluation of the ankle is not sufficient, as an exception this item was taken up in the consensus.

Discussion

In the three Delphi rounds, approximately one-third of the specialists responded. This appears to be a low response rate, although the actual number of respondents is considerable compared with other Delphi studies in which a maximum of 55 respondents were reported.^{25,29,30} Reasons for the low response rate could be the timing of the questionnaire (during the summer holidays); the inability to obtain all private email addresses and the difficulty senior specialists might have with using the Internet. When we consider the reasons given for not participating in this consensus, it is unlikely that non-responders would have had significantly different opinions to those of the responders. In fact, those willing to participate have been shown to be representative of other colleagues in terms of qualifications, experience and speciality.³¹ Therefore, it can be assumed that the results of this Delphi consensus are representative of radiologists, orthopedic surgeons and trauma surgeons in the Netherlands.

In this Delphi study, consensus was reached on how to evaluate fracture reduction and fixation of the wrist and the ankle. Consensus on which items not to evaluate was scarce. Although full consensus could not be attained, a high level of agreement was reached as to the evaluation of the anatomy of the wrist and ankle. In the evaluation of fracture reduction, intra-articular aspects were considered important for both the wrist and the ankle. The attained consensus is that fixation should be assessed using three of the five proposed criteria for the wrist and four of the five criteria proposed for the ankle. There was little increase in agreement after the second Delphi round and for some items consensus even decreased after the second Delphi round. This suggests that no further agreement would have been reached if more Delphi rounds were conducted.

However, this Delphi study also showed that opinions differ in the imaging techniques that are required in the evaluation of especially the ankle. Consensus was reached for only one out of eight imaging techniques for the ankle. The fact that the threshold of 90% agreement for consensus could not be reached for either an AP- or a mortise projection is remarkable. Although undesirable, it can be due to the fact that in Dutch clinical practice not always a clear distinction is being made between the mortise and AP projection. An AP projection of the ankle in Dutch guidelines is often described with 20° endorotation.³² Another explanation can possibly be found in a difference between the desired imaging strategy and practical limitations. In clinical practice, it is not always possible to have an accurate mortise or AP projection due to the patient's inability to endorotate because of the injury. In these cases, the injury can usually be properly diagnosed based on the physical exam, even with a suboptimal mortise or AP projection.

For additional imaging like a CT-scan, opinions were ambivalent for both the wrist and the ankle. This may reflect the difference in imaging policy between different hospitals or even between different specialists within a hospital, despite recommendations given by the AO foundation for standard and additional imaging.¹ Our results largely correspond with their recommendations for the standard imaging of the wrist, but not for the ankle.

All items concerning intra-articular fracture reduction and position of the fixation material were incorporated in the final consensus for both the ankle and the wrist. In concordance with the AO recommendations, respondents tended to consider extra-articular fracture reduction and position of the fixation material to be less important, but no consensus could be reached on any of these items.¹ AO recommendations also make little mention of extra-articular fracture reduction other than to emphasize the need to strive for alignment.

Sometimes, conflicting answers arose due to the way in which the questions were phrased. There were questions on how to evaluate the aspects of the wrist or ankle anatomy. Respondents could choose to answer either 'yes' or 'no' but did not have to choose between the different evaluation methods. For example, in the evaluation of the relationship between the length of the radius and the ulna, respondents indicated that measurement of dorsal angulation was important, but they also reported that it could be assessed visually. In contrast, assessment of rotation of the fibula was considered important, but no consensus could be reached on how this should be evaluated. The majority of the specialists did not think this could be determined visually, nor did they think that it could be determined by measuring the axial malleolar index on a CT scan. In the third Delphi round, the respondents were asked to provide suggestions on how to evaluate the rotation, but none were given. As a result, it was not possible to propose a method to evaluate rotation of the fibula.

Traditionally, the various scoring systems available have been based on radiographic measurements.^{3,4,6-11,17-19,33} This is also true for the AO requirements for an acceptable fracture reduction of the wrist. These requirements are articular incongruity of less than 2 mm, radial shortening of less than 5 mm and residual dorsal tilt of less than 10°. For the ankle, one of the measurements mentioned is that of the talocrural angle.¹ It is interesting to note that in our consensus, with the exception of dorsal tilt measurement, no consensus could be reached on the necessity of most measurements. Moreover, there was actually consensus that some measurements were not necessary when assessing the ankle and wrist. According to this consensus, most of the aspects of the wrist and ankle anatomy can be assessed visually. This view is in marked contrast to the evaluation of the anatomy as described in the literature, but better usable in clinical practice. In addition, our respondents considered more aspects important in the evaluation of the wrist and ankle than the aforementioned scoring systems do. This implies that these scoring systems, either evidence-based or expert-based, do not reflect routine radiological practice in the Netherlands. Therefore, we suggest a more practice-based scoring protocol in which the different items can be evaluated visually. A Delphi study involving international specialists will have to be performed to investigate whether the results of this Dutch Delphi study are also representative for other countries regarding their routine policies and radiological evaluation. Consensus on imaging policy and radiological assessment of the wrist and ankle is important for creating more uniformity in the standard care of fractures of the wrist and ankle, within and between countries.

By means of this Delphi study based on the clinical experience of specialists from different disciplines in the Netherlands, a broad consensus has been reached on how to evaluate wrist and ankle fracture reduction and fixation. In contrast with previous scoring systems,

How to evaluate the quality of fracture reduction and fixation in clinical practice

measurements do not take a prominent place in our findings. Therefore, we suggest a more practice-based scoring protocol, based on this consensus, in which the different items can be evaluated visually. This scoring protocol can be used as an educational tool but can also be used to increase uniformity in the radiological evaluation of the wrist and ankle in clinical practice.

Acknowledgments

The authors thank the following participants in the Delphi study for their contribution in obtaining this consensus (in alphabetical order)

K.A. Bartlema, MD
L.F.M. Beenen, MD PhD
G.I.J.M. Beerhuizen, MD PhD
M. Bemelman, MD
B.P. Bertelink, MD
J.H.J.M. Bessems, MD
A.F.A. van Beurden, MD
J. Biert, MD PhD
F.W. Bloemers, MD PhD
A.L. Boerboom, MD
P.H. Breedveld, MD
M.W.G.A. Bronkhorst, MD
G. Bronsema, MD
R.W. Brouwer, MD PhD
S.K. Bulstra, MD PhD
L.A. Burghard, MD
A. Dalen, MD
R.L. Diercks, MD PhD
B.A. van Dijkman, MD
H.A.J. Dijkstra, MD
R.A. Droog, MD PhD
C. van Egmond, MD
L.H.G.J. Elmans, MD
C. Faber, MD
M.L.M. Falke, MD
A.J. Frima, MD
J.P. Froelke, MD PhD
A.Z. Ginai, MD PhD
J.W.H. Gabriëls, MD
J.C. Goslings, MD PhD
W. Haagh, MD
B.L.E.F. ten Have, MD
J.S. Harbers, MD
R. Haverlag, MD
W.H.J.C. van Heeswijk, MD
H.J.L. van der Heide, MD PhD
M.P. Heijboer, MD
S.H. van Helden, MD PhD
W.R. Hogeboom, MD PhD
M. Holla, MD
B. Huisman, MD PhD
P.F.J. Houben, MD
P.F. Hulstaert, MD
I.M.C. Jansen, MD
J.M.G.T. Jenner, MD PhD
Th.E.A.M. de Jong, MD
M.C. de Jonge, MD
A.J.M. Karthaus, MD PhD
R.P. Karthaus, MD
P. Kloen, MD PhD
K.A. Kolkman, MD
E. Krug, MD
P.H.W. Lubbert, MD PhD
P.A. van Luijt, MD
M. Maas, MD PhD
P.G.M. Maathuis, MD PhD
A.K. Mostert, MD PhD
H. Mul, MD
H.J. Oostenbroek, MD
P.P. Oprel, MD
P. Patka, MD PhD
K.J. Ponsen, MD PhD
S. Ploem, MD
P.A.M. Raaijmakers, MD
H. Rath, MD
S.J. Rhemrev, MD
M.G. Romijn, MD
G.R. Schaap, MD PhD
M.U. Schaфроth, MD PhD
I.B. Schippers, MD PhD
R.K.J. Simmermacher, MD PhD
W. van der Stappen, MD
E. Tan, MD PhD
J.L. Turkenburg, MD PhD
A. van der Veen, MD PhD
B. Veenings, MD
J.P.A.M. Verbruggen, MD PhD
C.C.P.M. Verheyen, MD PhD
M.H.J. Verhofstad, MD PhD
E.J.J.M. Verleisdonk, MD PhD
L.M.M. Vogels, MD
A.B. van Vugt, MD
M. Waleboer, MD
A.D.P. van Walsum, MD PhD
R. Weijers, MD PhD
K.W. Wendt, MD PhD
M.M.E.H. Witbreuk, MD
C.A.J. van der Worp, MD

References

1. Buckley R., Moran C.G., Apivattthakakul T. AO Principles of fracture treatment. *Thieme Medical Publishers*, 01/2011.
2. Catalano L.W., Cole R.J., Gelberman R.H., et al. Displaced intra-articular fractures of the distal aspect of the radius. Long-term results in young adults after open reduction and internal fixation *The Journal of Bone and Joint Surgery (American Volume)* 1997; 79: 1290–302.
3. Goldfarb C.A., Rudzki J.R., Catalano L.W., et al. Fifteen-year outcome of displaced intra-articular fractures of the distal radius. *The Journal of Hand Surgery (American Volume)* 2006; 31: 633–9.
4. Langenhuijsen J.F., Heetveld M.J., Ultee J.M., Steller E.P., et al. Results of ankle fractures with involvement of the posterior tibial margin. *The Journal of Trauma* 2002; 53: 55–60 (2002).
5. Lloyd J., Elsayed S., Hariharan K., et al. Revisiting the concept of talar shift in ankle fractures. *Foot & Ankle International* 2006; 27: 793–6.
6. Cole R.J., Bindra R.R., Evanoff B.A., et al. Radiographic evaluation of osseous displacement following intra-articular fractures of the distal radius: reliability of plain radiography versus computed tomography. *The Journal of Hand Surgery (American Volume)* 1997; 22: 792–800.
7. Goldfarb C.A., Yin Y., Gilula L.A., et al. Wrist Fractures : What the clinician wants to know. *Radiology*. 2001; 219: 11–28.
8. Knirk J.L., Jupiter J.B. Intra-articular fractures of the distal end of the radius in young adults. *The Journal of Bone and Joint Surgery (American Volume)* 1986; 68: 647–59.
9. Mann F.A., Wilson A.J., Gilula L.A. Radiographic evaluation of the wrist: What does the hand surgeon want to know? *Radiology* 1992; 184: 15–24.
10. Jaremko J.L., Lambert R.G.W., Rowe B.H., et al. Do radiographic indices of distal radius fracture reduction predict outcomes in older adults receiving conservative treatment? *Clinical Radiology* 2007; 62: 65–72.
11. Jeong G.K., Kaplan F.T.D., Liporace F., et al. An Evaluation of two scoring systems to predict instability in fractures of the distal radius. *The Journal of Trauma* 2004; 57: 1043–7.
12. Lidstrom A. Typical radius fracture. *Nordisk Medicin* 1955; 54: 1621–5.
13. Gartland J.J., Werley C.W. Evaluation of healed Colles' fractures. *The Journal of Bone and Joint Surgery (American Volume)* 1951; 33-A: 895–907.
14. Sarmiento A., Pratt G.W., Berry N.C., et al. Colles' fractures. Functional bracing in supination. *The Journal of Bone and Joint Surgery (American Volume)* 1975; 57: 311–7.
15. van Eerten P.V., Lindeboom R., Oosterkamp A.E., et al. An X-ray template assessment for distal radial fractures. *Archives of Orthopaedic and Trauma Surgery* 2008; 128: 217–21.

16. DeCoster T.A., Willis M.C., Marsh J.L., et al. Rank order analysis of tibial plafond fractures: Does injury or reduction predict outcome? *Foot & Ankle International* 1999; 20: 44–9.
17. Jaskulka R.A., Ittner G., Schedl R. Fractures of the posterior tibial margin: Their role in the prognosis of malleolar fractures. *The Journal of Trauma* 1989; 29: 1565–70.
18. Musgrave D.J., Fankhauser R.A. Intraoperative radiographic assessment of ankle fractures. *Clinical Orthopaedics and Related Research* 1998; 351: 186–90.
19. Ovadia D.N., Beals, R.K. Fractures of the tibial plafond. *The Journal of Bone and Joint Surgery (American Volume)* 1968; 68: 543–51.
20. Grose A., Gardner M.J., Hettrick C., et al. Open reduction and internal fixation of tibial pilon fractures using a lateral approach. *Journal of Orthopaedic Trauma* 2007; 21: 530–7.
21. Teeny S.M., Wiss D.A. Open reduction and internal fixation of tibial plafond fractures. Variables contributing to poor results and complications. *Clinical Orthopaedics and Related Research* 1993; 292: 108–17.
22. Kreder H.J., Hanel D.P., McKee M., et al. X-ray film measurements for healed distal radius fractures. *The Journal of Hand Surgery (American Volume)* 1996; 21, 31–9.
23. Grainger A.J., Duryea, J., Elliott J.M., et al. The evaluation of a new digital semi-automated system for the radiological assessment of distal radial fractures. *Skeletal Radiology* 2002; 31: 457–63.
24. Brown B.B. *A Methodology Used for the Elicitation of Opinions of Experts* 1968; available at <https://www.rand.org/pubs/papers/P3925.html> (Accessed: 1st of May 2020).
25. Holey E.A., Feeley J.L., Dixon J., et al. An exploration of the use of simple statistics to measure consensus and stability in Delphi studies. *BMC Medical Research Methodology* 2007; 7: 52.
26. Huisstede B.M.A., Miedema H.S., Verhagen A.P., et al. Multidisciplinary consensus on the terminology and classification of complaints of the arm, neck and/or shoulder. *Occupational and Environmental Medicine* 2007; 64: 313–9.
27. Murphy M.K., Black N.A., Lamping D.L., et al. Consensus development methods, and their use in clinical guideline development. *Health Technology Assessment* 1998; 2, i–iv, 1–88.
28. Goslings J.C., Ponsen K.J., Luitse J.S.K., et al. Trauma surgery in the era of nonoperative management: The Dutch model. *The Journal of Trauma* 2006; 61: 111–4; discussion 115.
29. Almansa C., Rey E., Bolaños E., et al. Spanish physicians point of view on irritable bowel syndrome (IBS). Results of a Delphi survey. *Revista Española de las Enfermedades Digestivas* 2007; 99: 210–7.
30. Bakx R., Emous M., Legemate D.A., et al. Categorization of major and minor complications in the treatment of patients with resectable rectal cancer using short-term pre-operative radiotherapy and total mesorectal excision: a Delphi round. *Colorectal Disease* 2006; 8: 302–8.
31. McKee M., Priest P., Ginzler M., et al. How representative are members of expert panels? *Quality Assurance in Healthcare* 1991; 3, 89–94.

How to evaluate the quality of fracture reduction and fixation in clinical practice

32. Brink P, van Mourik J, Simmermacher R, et al. Letsels van de enkel en de voet in Letsels van het steun- en bewegingsapparaat. *Elsevier Gezondheidszorg* 2007; 261–6.
33. Schneiders W, Biewener A, Rammelt S, et al. Distal radius fracture. Correlation between radiological and functional results. *Unfallchirurg* 2006; 109: 837–44.



Chapter 3

Evaluation of quality of fracture reduction and fixation of the calcaneus in clinical practice: An international Delphi consensus

M.S.H. Beerekamp, J.S.K. Luitse, D.T. Ubbink,
N.W.L. Schep, J.C. Goslings

Archives of Orthopaedic Trauma Surgery 2013; 133: 1377-84.

Abstract

Background

Postoperative radiological assessment of the quality of reduction and fixation of calcaneal fractures is essential when evaluating treatment success. However, a universally accepted radiological evaluation protocol is currently unavailable. The aim of this study was to obtain an expert-based consensus on the most important criteria for the radiological assessment of the quality of reduction and fixation of calcaneal fractures.

Methods

The Delphi method, consisting of three rounds, was used to obtain consensus. Each round focused on four main topics of calcaneal fracture evaluation: imaging technique (38 items), anatomical landmarks (21 items), fracture reduction (16 items) and position of the fixation material (9 items). We invited ten radiologists and 44 surgeons from the USA and Europe (all calcaneus experts) to complete online questionnaires. They were asked which aspects require evaluation to determine the quality of fracture reduction and fixation. Agreement was expressed as the percentage of respondents with identical answers. Consensus was defined as an agreement of at least 80 %.

Results

All experts were invited for the three Delphi rounds and 16, 18, and 15 specialists responded per round, respectively. Agreement was reached for 23/38 (60%) items regarding imaging techniques, 20/21 (95%) anatomical landmarks, 13/16 (8%) items regarding fracture reduction and 8/9 items (89%) regarding fracture fixation.

Conclusion

This Delphi consensus shows that more aspects require evaluation than currently used in radiological evaluation protocols. With this consensus, we provide the basis for a universal evaluation protocol to assess the radiological outcome of calcaneal fracture treatment.

Introduction

Anatomical reduction and subsequent operative fixation of calcaneal fractures are considered as the best foundation for an optimal functional outcome.¹ Because the quality of fracture reduction and fixation is considered to greatly influence functional outcome, radiological evaluation seems essential in determining treatment success. Although the importance of radiological assessment is acknowledged, an international consensus on the optimal assessment of the quality of fracture reduction and fixation is currently unavailable.

Although, computer tomography is the unquestionable imaging modality of choice in terms of preoperative fracture assessment, the best technique to visualize and evaluate the result of calcaneal fracture reduction and fixation remains controversial.²⁻⁷ There is lack of consensus concerning imaging modality and technique of choice in the evaluation of radiological outcome. In a study of Parmer et al., comparing calcaneal fracture treatment, postoperative CT scans were performed to evaluate treatment result.⁸ They reported that there were no satisfactory methods to grade the quality of the reduction based on CT scans in the operated group, since then others have introduced CT-based measurements.^{9,10} However, most current measurements, like those of the commonly used Böhler's angle and Gissane's critical angle, are not one of them and only based on radiographs.^{1,3,5,11-15} This is probably due to the difficulty of capturing all anatomical landmarks needed to measure these angles in one slice. Moreover, individual studies use different thresholds of Böhler's angle, step-off and gaps that are considered acceptable.^{5,6,10,12,13,16} Intra-articular gaps and step-offs remain better visualized with the use of CT scans.¹⁰

In addition, available literature on the reliability of the above-mentioned measurements is scarce. Clint et al. found that inter-observer agreement of the postoperative measurement of Böhler's angle in children was excellent, in contrast to Gissane's critical angle which was only fair to poor.¹⁷ To our knowledge, reliability of subjective evaluation criteria of anatomical landmarks has not been investigated. However, Basile showed that subjective evaluation of the anatomic reduction of the PTC-joint can have prognostic value for the clinical outcome.¹⁸

These apparent differences in radiological evaluation prevent a good comparison between different study results and reduce reproducibility. Therefore blinded, independent radiological assessment should be standard, as was stated in a systematic review of Richards and Bridgman.⁵ However, no recommendations were given about the radiological parameters to be assessed. Well-defined criteria for evaluation are fundamental to be able to compare treatment results. The purpose of this study was to obtain an expert-based consensus on the most important radiological criteria for the assessment of the quality of fracture reduction and fixation of the calcaneus, which can be used in clinical practice.

Methods

The Rand Corporation developed the Delphi method to measure and obtain group consensus.^{19–22} In this structured, anonymous and repeated process, experts are being asked to respond to non-leading, unambiguous statements on items relevant to the topic.²⁰ We used this effective method to obtain consensus among specialists in this study.

To assess the level of agreement on useful criteria in the radiological evaluation of the calcaneus, a list of possible criteria was composed based on literature data and on the authors' experience.^{1,3,5,13–16,23} These items were divided into four main topics: (1) imaging technique, (2) evaluation of anatomical landmarks of the operated joint, (3) reduction of fracture fragments and (4) position of the fixation material.

Medical specialists invited

Experts in treating patients with calcaneal fractures were selected by approaching research groups from Europe and the USA that have published papers on calcaneal fractures. In addition, we approached the president of the European Ankle and Foot Society as well as the president of the AO Foot and Ankle Association and asked them to recommend experts and spread the invitation among their committee members. The email addresses of three experts thus selected could not be acquired. Finally, a total of 54 international experts, 44 surgeons and 10 radiologists, were invited to participate by email.

Study procedure

Online questionnaires were used for all three Delphi rounds. All experts received an invitation containing a motivational statement to participate in this study, an explanation of the Delphi procedure, and a link to the URL of the online questionnaire. Up to three reminders were sent every 2 weeks in case the invited expert did not respond. The complete questionnaires can be found on the internet.^{24–26}

The questionnaires generally consisted of multiple-choice questions regarding the imaging technique, evaluation of anatomical landmarks of the operated joint, reduction of fracture fragments and position of the fixation material. Answer options to the requirement of an item were 'yes', 'no' or 'selective'. Examples of the imaging technique or measurements were added to most of the questions for clarification. The questions regarding imaging technique focused on requirement of imaging modalities and techniques during the pre-, intra and postoperative evaluation. On the subject of anatomical landmarks, the experts were asked if certain features required evaluation for the determination of the quality of fracture reduction and fixation of calcaneal fractures. If the answer to the question was 'yes', a follow-up question appeared asking the experts which method of evaluation they considered most appropriate, e.g. a distance/angle measurement or visual assessment. A free text field was always available to specify other evaluation methods when necessary. Each section ended with open questions, asking if the experts had suggestions for additional criteria or other remarks.

The second and third rounds were constructed by incorporating remarks and suggestions of the previous round, as is required by the Delphi method. We included a histogram presenting the relevant results from the previous round in the introduction of each

question. If the 80% threshold of agreement on an item had been reached in the previous round, this was reported to the experts and the question was omitted in the next round.

Statistical analysis

The number of identical answers was divided by the number of respondents and expressed as a percentage. For every question, consensus was defined as an agreement of at least 80%.

Results

Respondents

The invitations of the first Delphi round were sent in May 2010. Of the 54 invitees, 30% (16 experts) eventually completed the questionnaire. An additional 13% (7 experts) responded by email; they did not want to participate because of lack of time or interest. These experts were removed from our mailing list and not approached for further Delphi rounds. The second round started in July 2011 and generated a response rate of 38% (18 experts) of the 47 invitees. In this round, two experts replied that they did not want to participate due to lack of time. The final round commenced in October 2011 to which 33% (15 experts) of the 45 invitees responded (Table 1). Ten experts completed all Delphi rounds, seven experts participated in two Delphi rounds, and three experts participated in one Delphi round.

Approximately, 30% of the responding experts were radiologists, 70 % were surgeons (Table 2). The number of years in practice ranged from less than 5 years to more than 20 years, while the majority (61%) had more than 15 years of experience. Almost all experts were employed by a university hospital (84%).

Table 1: Response rate of the specialists

Delphi Round	Response rate specialists (n)			Total invited
	Experts responded	No participation	No response	
I	30% (16)	13% (7)	57% (31)	100% (54)
II	38% (18)	4% (2)	57% (27)	100% (47)
III	33% (15)	0% (0)	66% (30)	100% (45)

Table 2: Characteristics of the respondents

Characteristic	Delphi round I (n=16)	Delphi round II (n=18)	Delphi round III (n=15)
Specialty			
Surgeon	69% (11)	72% (13)	73% (11)
Radiologist	31% (5)	28% (5)	27% (4)
Years of experience			
0 - 5 years	25% (4)	6% (1)	7% (1)
5 - 10 years	0% (0)	11% (2)	20% (3)
10 - 15 years	19% (3)	17% (3)	13% (2)
15 - 20 years	25% (4)	22% (4)	7% (1)
>20 years	31% (5)	44% (8)	53% (8)
Type of hospital*			
University hospital	88% (14)	83% (15)	80% (12)
Urban hospital	19% (3)	17% (3)	20% (3)
Suburban hospital	0% (0)	0% (0)	7% (1)
Rural hospital	0% (0)	0% (0)	0% (0)
Private clinic	6% (1)	17% (3)	7% (1)

*Respondents could indicate that they are working in more than one type of hospital if applicable

Agreement regarding the imaging of the calcaneus

A consensus on the role of different imaging modalities in preoperative, intraoperative and postoperative evaluation of calcaneal fractures was obtained for 23 of the 38 proposed techniques after three Delphi rounds (Table 3). The percentage of agreement for each item can be found in online Appendix 1. A lateral projection of the ankle and axial projection of the calcaneus were considered mandatory in the pre-, intra- and postoperative evaluation of calcaneus fractures. Consensus on these items was reached in the first Delphi round. An additional 20° Brodén radiograph was also found necessary in the intra-operative evaluation.

A CT scan with reconstructions in the anatomical sagittal, coronal and axial planes was considered mandatory in the preoperative evaluation of calcaneus fractures. Although a majority of the experts thought intra-operative 3D-imaging (73 %) or a postoperative CT scan (68 %) is required, no consensus was reached.

Agreement regarding the evaluation of anatomical landmarks

Consensus was obtained for all but one of the proposed anatomical landmarks (Table 4). The congruency of the three articulations (calcanocuboid (CC), anterior talocalcaneal (ATC) and posterior talocalcaneal (PTC) joints), Böhler's angle, Gissane's angle and the position of the tuber were considered the only anatomical landmarks of the calcaneus that required evaluation (Figure 1).

Böhler's angle can only be evaluated by angle measurement on a lateral X-ray. However, no consensus could be obtained on the method of evaluation of Gissane's angle, as 50% of the experts preferred angle measurement and 50% preferred visual evaluation. Visual evaluation was considered sufficient for the remaining anatomical landmarks.

Table 3: Results of the Delphi consensus regarding the imaging of calcaneal fractures

	Imaging technique is required (≥ 80% agreement)	Imaging technique is NOT required (≥ 80% agreement)
Preoperative	<ul style="list-style-type: none"> • X-ray <ul style="list-style-type: none"> - Lateral projection of the ankle - Axial projection of the calcaneus • CT-scan <ul style="list-style-type: none"> - Sagittal reconstructions - Coronal reconstructions - Axial reconstructions 	<ul style="list-style-type: none"> • X-ray <ul style="list-style-type: none"> - Mortise projection of the ankle - Medial oblique projection of the foot - Projection of the contra lateral joint • MRI-scan
Intra-operative	<ul style="list-style-type: none"> • 2D-fluoroscopy <ul style="list-style-type: none"> - Lateral projection of the ankle - Axial projection of the calcaneus - 20° Brodén projection of the calcaneus 	<ul style="list-style-type: none"> • 2D-fluoroscopy <ul style="list-style-type: none"> - Anteroposterior projection of the ankle - Mortise projection of the ankle - Valgus stress projection of the ankle - Lateral oblique projection of the foot - Projection of the contra lateral joint
Postoperative	<ul style="list-style-type: none"> • X-ray <ul style="list-style-type: none"> - Lateral projection of the ankle - Axial projection of the calcaneus 	<ul style="list-style-type: none"> • X-ray <ul style="list-style-type: none"> - Anteroposterior projection of the ankle - Medial oblique projection of the foot - Lateral oblique projection of the foot - Projection of the contra lateral joint • MRI-scan

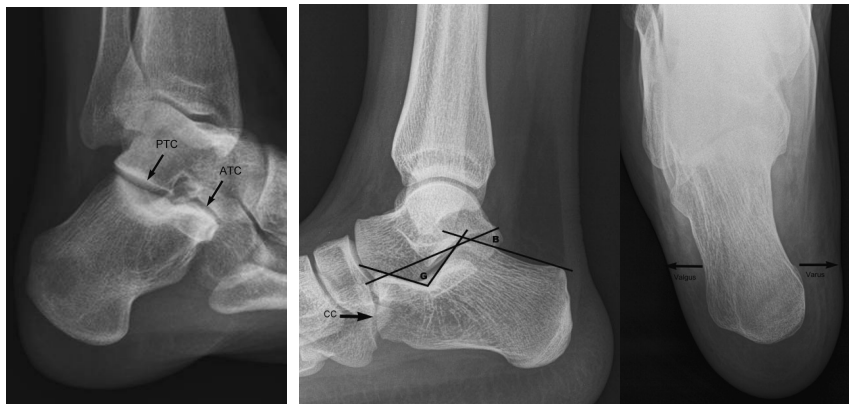

Figure 1: Brodén, lateral and axial view of the calcaneus

- Left image - Brodén view: PTC: Posterior talocalcaneal joint
ATC: Anterior talocalcaneal joint
- Middle image - Lateral view: CC: Calcaneocuboidal joint
G: Gissane's critical angle - the angle between the line tangent to the articular surface of the medial posterior facet and the line tangent to the dorsal surface of the calcaneal neck.
B: Böhler's angle - angle between the line from the highest point on the anterior process to the highest point on the posterior edge of the posterior facet, and the line tangent to the superior surface of the tuberosity.
- Right image - Axial view: Displacement of the tuber calcanei in the direction of one of the arrows indicates a varus or valgus position of the tuber calcanei

Table 4: Results of the Delphi consensus regarding the evaluation of the quality of fracture reduction and fixation of the calcaneus

	Item is required in the evaluation (≥ 80% agreement)	Item is NOT required in the evaluation (≥ 80% agreement)
Anatomical landmarks	<ul style="list-style-type: none"> • Congruency of the CC-joint* • Congruency of the PTC-joint* • Congruency of the ATC-joint* • Böhler's angle[^] • Gissane's angle • Varus/Valgus position of the tuber calcanei* 	<ul style="list-style-type: none"> • Heel height • Fat pad height • Achilles tendon fulcrum • Talocalcaneal angle • Calcaneal inclination angle • Tibiotalar angle • Talar horizontal angle • Talar declination angle • Calcaneal facet height • Calcaneal facet inclination angle • Arch angle • Length of the calcaneus • Fibulocalcaneal distance
Reduction	<ul style="list-style-type: none"> • Presence of Step-offs <ul style="list-style-type: none"> - In the CC- joint* - In the PTC- joint - In the Processus Anterior* ★ Threshold for acceptability of step-off ≤ 2 mm • Presence of gaps <ul style="list-style-type: none"> - Presence of Gaps in the CC- joint* - Presence of Gaps in the PTC- joint - Presence of Gaps in the Processus Anterior* - Threshold of acceptability of gaps ≤ 2 mm • Presence of bone fragments <ul style="list-style-type: none"> - In the CC-joint* - In the ATC-joint* - In the PTC-joint* 	<ul style="list-style-type: none"> • Presence of Extra-articular step-offs • Presence of Extra-articular gaps
Fixation	<ul style="list-style-type: none"> • Position of the fixating plate* • The presence of too short screws* • Grip of screws in the sustentaculum tali* • Presence of protruding screws <ul style="list-style-type: none"> - In the CC-joint* - In the ATC-joint - In the PTC-joint* - Through the Medial wall* - Through the Tuber Calcanei* 	

* This item requires evaluation by visual assessment

[^] This item requires evaluation by angle measurement

Agreement regarding reduction of fracture fragments

Consensus was reached for 13 of the 16 proposed aspects of evaluation of the reduction of fracture fragments of the calcaneus (Table 4). Postoperative assessment of the presence of intra-articular step-offs and gaps in the CC- and PTC-joint was considered necessary. The same holds for steps and gaps in the processus anterior. A step-off or gap of no more than 2 mm was deemed acceptable. Although a majority (60%) of the experts also considered assessment of the presence of a step-off or gap in the ATC-joint essential, no agreement was reached. Assessment of extra-articular step-offs and gaps was not

considered necessary. According to the experts, the presence of intra-articular bone fragments should be evaluated. No agreement could be reached on the assessment of extra-articular bone fragments.

Agreement regarding fracture fixation

Consensus was reached for all but one of the proposed items regarding the evaluation of fracture fixation (Table 4). Although a majority (73%) of the experts agreed that the grip of screws, i.e. protrusion of screws in the opposite cortex, in the processus anterior requires evaluation, no consensus was reached. The experts agreed that correct positioning of the fixation plate on the lateral wall, adequate length of the screws (i.e. not too short), grip of the screws in the sustentaculum tali, presence of protruding screws in the CC-, ATC- and PTC-joint as well as protrusion of screws in the medial wall and the tuber calcanei need to be assessed.

Discussion

By means of this Delphi study, consensus among experts was reached which imaging techniques, anatomical landmarks, fracture reduction and position of the fixation material should and should NOT be used in the postoperative evaluation of calcaneus fractures. This international consensus could form the basis for a universal evaluation protocol to assess the radiological outcome of treatment of calcaneal fractures.

For almost all proposed items of the evaluation of anatomical landmarks, fracture reduction and fixation, consensus was reached. For more than half of the proposed items concerning imaging technique consensus was reached. Lateral and axial radiographs of the calcaneus were considered required in the pre-, intra- and postoperative evaluation. In addition to radiographs, the experts also deemed a CT scan necessary in the pre-operative evaluation of the fracture. For the intra-operative evaluation, an additional radiograph with a 20° Brodén projection of the calcaneus is required. Surprisingly, for the postoperative evaluation, only two radiographic projections (lateral and axial) were considered mandatory by our experts, even though postoperative intra-articular irregularities, particularly in the ATC- and PTC-joint, can be difficult to detect on plain radiographs.

The large majority of the proposed anatomical landmarks were not considered essential to evaluate in clinical practice. Although some of the items, like the tibiotalar angle, have shown to be correlated with the clinical outcome.³⁰ For wrist and ankle fractures, such landmarks appeared more relevant.⁵ Anatomical landmarks of the calcaneus that require evaluation according to our experts, like Böhler's and Gissane's angle, are the ones most frequently mentioned in the literature.^{5,6,12,13,16} There is a difference in the method of evaluation of these anatomical landmarks: In contrast to the other items, which can be assessed visually, Böhler's angle requires to be measured. Surprisingly, no agreement could be reached on the evaluation method of Gissane's critical angle, even though this angle is frequently measured in the literature.

As expected, extra-articular step-offs and gaps do not require evaluation when assessing the quality of calcaneus fracture reduction and fixation. The generally accepted cut off point for acceptability of a step-off or gap that requires treatment lies at 2 mm.¹ However, since CT scanning is used for the postoperative evaluation also some evaluation protocols use lower thresholds.^{1,10,13} In this consensus, only one expert found a lower threshold acceptable (<1 mm).

Although some studies reporting on intra-operative imaging specifically score the accuracy of screw placement, to our knowledge fixation has not been part of an evaluation protocol of treatment result.^{27,28} However, in this Delphi consensus, our experts considered the position of the fixating plate and adequate length of the screws important in the evaluation of the quality of the position of the fixation material.

The limited number of experts participating might be considered a limitation even though this number is comparable to other Delphi consensus studies.^{20,29} No prior invitation had been sent to the experts to preselect experts willing to participate. Retrieving personal email addresses, particularly from some internationally renowned senior specialists of calcaneal fractures, was more difficult than we had anticipated. In addition, experts tend to get overwhelmed by questionnaires and, therefore, lack time or willingness to participate. Although the characteristics of the non-responding experts in this study are not known, it has been shown that characteristics of non-responders do not differ in terms of qualifications, experience and specialty.³⁰ Therefore, similar results for this Delphi study are to be expected with more experts participating.

Second, the reliability of this evaluation protocol has yet to be determined as well as the prognostic value for the patients' clinical outcome of the (combination of) items found in this consensus. Currently, we are performing a prospective multicenter study to determine the effectiveness of intra-operative 3D-fluoroscopy.³¹ In this study, patients with calcaneal fractures are included and followed until 5 years after open reduction and internal fixation of their calcaneal fracture. The postoperative radiological parameters of the evaluation protocol will be determined on both radiographs and a CT scan by three experts. Both intra- and interobserver agreement will be determined for the evaluation of these experts. In addition, the evaluation of the subjective radiological parameters can be correlated to the clinical parameters like range of motion and self-reported questionnaires.

In conclusion, this Delphi consensus shows that current evaluation protocols are not comprehensive. Adding items that require evaluation, namely, the position of the tuber calcanei and the position of the fixation material, i.e. fixating plate and presence of intra-articular protruding screws need to be considered.^{9,10,28} In addition, most aspects could be assessed visually, although angle or distance measurements have frequently been advocated in the literature.^{5,6,10,12,16} Similar conclusions were drawn when studying criteria for wrist and ankle fractures.³² With this Delphi consensus, we have provided the basis for a universal evaluation protocol to assess the radiological outcome in association with clinically relevant outcomes of the treatment of calcaneal fractures.

Acknowledgments

We would like to thank the following experts for their participation in this Delphi Study:

A. Witteveen, MD, Orthopaedic Surgeon,
Prof. Dr. B. Hintermann, MD Ph.D, Orthopaedic Surgeon,
D. Den Hartog, MD PhD Trauma Surgeon,
Prof. Thodarson, MD PhD, Orthopaedic Surgeon,
Dr. H. Goost, MD PhD, Trauma Surgeon,
Dr. M. Poeze, MD PhD, Trauma Surgeon,
Prof. dr. P. Brink, MD PhD, Trauma Surgeon,
Dr. S. Rammelt, MD PhD, Trauma Surgeon,
Dr. I.G. Winson, MD PhD, Orthopaedic Surgeon,
Dr. W.J. Harries, MD PhD, Orthopaedic Surgeon,
Dr. J.B. Gerstner, MD PhD, Orthopaedic Surgeon,
M. Andoljsek, MD, Trauma Surgeon,
Dr. A. Karantanas, MD PhD, Radiologist,
Dr. D.J. Wilson, MD PhD, Radiologist,
Dr. F. Vanhoenacker, MD PhD, Radiologist,
M. Obradov, MD, Radiologist,
S.A. Schreinemachers, MD, Radiologist,
Dr. O. Schoierer, MD PhD, Trauma Surgeon.

References

1. Ruedi T.P., Buckley R.E., Moran C.G. AO Principles of fracture management. *Thieme Medical Publishers, 01/2011*.
2. Badillo K., Pacheco J.A., Padua S.O., et al. Multidetector CT Evaluation of Calcaneal Fractures. *Radiographics* 2011; 31: 81-92
3. Bajammal S., Tornetta P., Sanders D., et al. Displaced intra-articular calcaneal fractures. *Journal of Orthopaedic Trauma* 2005; 19: 360–4.
4. Dhillon M.S., Bali K., Prabhakar S. Controversies in calcaneus fracture management: A systematic review of the literature. *Musculoskeletal Surgery* 2011; 95, 171–81.
5. Richards P.J., Bridgman S. Review of the radiology in randomised controlled trials in open reduction and internal fixation (ORIF) of displaced intraarticular calcaneal fractures. *Injury* 2001; 32: 633–636.
6. Sanders R. Displaced intra-articular fractures of the calcaneus. *The Journal of Bone and Joint Surgery (American Volume)* 2000; 82: 225–50.
7. Swanson S.A., Clare M.P., Sanders R.W. Management of intra-articular fractures of the calcaneus. *Foot and Ankle Clinics* 2008; 13: 659–78.
8. Parmar H.V, Triffitt P.D., Gregg P.J. Intra-articular fractures of the calcaneum treated operatively or conservatively. A prospective study. *The Journal of Bone and Joint Surgery (British Volume)* 1993; 75: 932-7.
9. Gupta A., Ghalambor N., Nihal A., et al. The modified Palmer lateral approach for calcaneal fractures: Wound healing and postoperative computed tomographic evaluation of fracture reduction. *Foot & Ankle International* 2003; 24: 744–53.
10. Kurozumi T., Jinno Y., Sato T., et al. Open reduction for intra-articular calcaneal fractures: evaluation using computed tomography. *Foot & Ankle International* 2003; 24: 942–8.
11. Sengodan V.C., Amruth K.H., Karthikeyan. Böhler's and Gissane Angles in the Indian Population. *Journal of Clinical Imaging Science* 2012; 2: 77-9.
12. Böhler L. Diagnosis, pathology and treatment of the os calcis. *The Journal of Bone and Joint Surgery (British Volume)* 1931; 75: 196–201.
13. Buckley R., Tough S., McCormack R., et al. Operative compared with nonoperative treatment of displaced intra-articular calcaneal fractures: A prospective, randomized, controlled multicenter trial. *The Journal of Bone and Joint Surgery (American Volume)* 2002; 84-A: 1733–44.
14. Daftary A., Haims A.H., Baumgaertner M.R. Fractures of the Calcaneus: A review with emphasis on CT. *RadioGraphics* 2005; 25: 1215–1226.
15. Walde T.A., Sauer B., Degreif J., et al. Closed reduction and percutaneous Kirschner wire fixation for the treatment of dislocated calcaneal fractures: Surgical technique, complications, clinical and radiological results after 2-10 years. *Archives of Orthopaedic and Trauma Surgery* 2008; 128: 585–591.
16. Schepers T., Ginai A.Z., Mulder P.G.H., et al. Radiographic evaluation of calcaneal fractures: To measure or not to measure. *Skeletal Radiology* 2007; 36: 847-52.

17. Clint S.A., Morris T.P., Shaw O.M., et al. The reliability and variation of measurements of the os calcis angles in children. *The Journal of Bone and Joint Surgery (British Volume)* 2010; 92: 571–5.
18. Basile A. Subjective results after surgical treatment for displaced intra-articular calcaneal fractures. *The Journal of Foot and Ankle Surgery* 2012; 51: 182–6.
19. Brown B.B. *A Methodology Used for the Elicitation of Opinions of Experts* 1968; available at <https://www.rand.org/pubs/papers/P3925.html> (Accessed: 1th of May 2020).
20. Holey E.A., Feeley J.L., Dixon J., et al. An exploration of the use of simple statistics to measure consensus and stability in Delphi studies. *BMC Medical Research Methodology* 2007; 7: 52.
21. Huisstede B.M.A., Miedema H.S., Verhagen A.P., et al. Multidisciplinary consensus on the terminology and classification of complaints of the arm, neck and/or shoulder. *Occupational and Environmental Medicine* 2007; 64: 313–9.
22. Murphy M.K., Black N.A., Lamping D.L., et al. Consensus development methods, and their use in clinical guideline development. *Health Technology Assessment* 1998; 2, i–iv, 1–88.
23. Paley D., Hall H. Intra-articular fractures of the calcaneus. A critical analysis of results and prognostic factors. *The Journal of Bone and Joint Surgery (American Volume)* 1993; 75: 342–54.
24. Beerekamp M.S.H., Luitse J.S.K. Calcaneus - Delphi round 1. (2012). Available at: http://www.enqueteviainternet.nl/Delphi_consensus_cal-caneus_round_1.
25. Beerekamp M.S.H., Luitse J.S.K. Calcaneus - Delphi round 2. (2012). Available at: http://www.enqueteviainternet.nl/Delphi_consensus_cal-caneus_round_2.
26. Beerekamp M.S.H., Luitse J.S.K. Calcaneus - Delphi round 3. (2012). Available at: http://www.enqueteviainternet.nl/Delphi_consensus_cal-caneus_round_3.
27. Queitsch C., Schulz A.P., Haustedt N., et al. Improved therapy of calcaneal fractures by intraoperative 3D-fluoroscopy and locked-screw plate fixation. *European Journal of Trauma* 2006; 32: 471–476.
28. Rübberdt A., Feil R., Stengel D., et al. The clinical use of the ISO-C(3D) imaging system in calcaneus fracture surgery. *Unfallchirurg* 2006; 109: 112–8.
29. Bakx R., Emous M., Legemate D.A., et al. Categorization of major and minor complications in the treatment of patients with resectable rectal cancer using short-term pre-operative radiotherapy and total mesorectal excision: a Delphi round. *Colorectal Disease* 2006; 8: 302–8.
30. McKee M., Priest P., Ginzler M., et al. How representative are members of expert panels? *Quality Assurance in Healthcare* 1991; 3, 89–94.
31. Beerekamp M.S.H., Ubbink D.T., Maas M., et al. Fracture surgery of the extremities with the intra-operative use of 3D-RX: a randomized multicenter trial (EF3X-trial). *BMC Musculoskeletal Disorders* 2011; 12: 151.
32. Beerekamp M.S.H., Haverlag R., Ubbink D.T., et al. How to evaluate the quality of fracture reduction and fixation of the wrist and ankle in clinical practice: a Delphi consensus. *Archives of Orthopaedic Trauma Surgery* 2011; 131: 739–46.



Chapter 4

Systemic CT evaluation of reduction
and hardware positioning of
surgically treated calcaneal fractures:
A reliability analysis

R.J.O. De Muinck Keizer, M.S.H. Beerekamp, D.T. Ubbink,
L.F. Beenen, T. Schepers, J.C. Goslings

Archives of Orthopaedic Trauma Surgery 2017; 137: 1667-75.

Abstract

Introduction

Up to date, there is a lack of reliable protocols that systematically evaluate the quality of reduction and hardware positioning of surgically treated calcaneal fractures. Based on international consensus, we previously introduced a 23-item scoring protocol evaluating the reduction and hardware positioning in these fractures based on postoperative computed tomography. The current study is a reliability analysis of the described scoring protocol.

Methods

Three raters independently and systematically evaluated anonymized postoperative CT scans of 102 surgically treated calcaneal fractures. A selection of 25 patients was scored twice by all individual raters to calculate intra-rater reliability. The scoring protocol consisted of 23 items addressing quality of reduction and hardware positioning. Each of these four-option questions was answered as: 'optimal', 'suboptimal (but not needing revision)', 'not acceptable (needing revision)' or 'not judgeable'. We used intraclass correlation coefficients (ICC's) to calculate inter- and intra-rater reliability.

Results

Inter-rater reliability of the overall 23-item protocol was good (ICC 0.66, 95% CI 0.64–0.69). Individual items that scored an inter-rater ICC 0.60 included evaluation of the calcaneocuboid joint, the posterior talocalcaneal joint, the anterior talocalcaneal joint, the position of the plate and sustentaculum screws and screws protruding the tuber and medial wall. The intra-rater reliability for the overall protocol was good for all three individual raters with ICC's between 0.60 and 0.70.

Conclusion

Our scoring protocol for the radiological evaluation of operatively treated calcaneal fractures is reliable in terms of inter- and intra-rater reliability.

Introduction

The main goal of surgical treatment of calcaneal fractures is to restore the anatomy. Intra-articular incongruences are associated with posttraumatic osteoarthritis of the subtalar joint and poor clinical outcomes.¹⁻³ To adequately restore the anatomy, different surgical techniques have been proposed.⁴ To compare the radiological results of these techniques, a blinded, independent radiological assessment with a fixed set of reliable criteria should be standard.

Unfortunately, there is lack of a validated scoring protocol on the qualitative assessment of calcaneal fracture reduction and hardware positioning.⁵⁻¹⁰ As evaluation of plain radiography seems insufficient¹¹, different computed tomography (CT) based measurements have been proposed.^{12,13} Individual studies use different thresholds to specify acceptability of angles or intra-articular congruity.^{8,11,13-16} Additionally, reliability of these measurements is only seldom reported.

A recently published international Delphi consensus on how to evaluate postoperative results of surgically treated calcaneal fractures showed that in addition to the quality of reduction, the quality of hardware positioning also requires evaluation.¹⁷ Additionally, it showed that measurements were performed scarcely in clinical practice; evaluation of both reduction and hardware positioning is mostly performed by expert opinion.

Based on this international consensus, a fixed set of criteria for the assessment of the quality of fracture reduction and hardware positioning of the calcaneus has been composed. The aim of the current study was to determine the inter- and intra-rater reliability of this radiological scoring protocol.

Methods

To determine the inter- and intra-rater reliability of the scoring protocol, we used postoperative CT scans of 100 patients with 102 surgically treated calcaneal fractures. These patients had been enrolled in the EF3X-trial, a multicenter randomized clinical trial exploring the clinical value of additional 3D fluoroscopic imaging in the treatment of calcaneal fractures.¹⁸

Postoperative CT scans were anonymized and systematically evaluated with use of the scoring protocol by three independent raters [an experienced foot- and ankle surgeon (TS), a radiologist with specialty in musculoskeletal trauma (LFB), and a surgical trainee in orthopedic surgery and PhD candidate with 4 years of research experience in calcaneal fractures (RJDMK)]. No three-dimensional (volume rendering) reconstructions were available.

The scoring protocol used was developed after Delphi consensus between 18 international experts in the field (both surgeons and radiologists) and previously published in this journal.¹⁷ The protocol consists of 23 items addressing post-operative reduction and hardware positioning of the most important anatomical landmarks of the calcaneus (Table 1).

Table 1: The scoring protocol, based on an international Delphi consensus

Anatomy					
1. Böhler's angle	Anatomical	Not anatomical, but acceptable	Not anatomical, not acceptable	Not judgeable	Not judgeable
2. Gissane's angle					
3. Varus/valgus position of the tuber					
CC-joint					
4. Length of the calcaneus	Anatomical	Shortened, but acceptable	Shortened, not acceptable	Not judgeable	Not judgeable
5. Symmetry/width of the CC-joint	Anatomical	Not anatomical, but acceptable	Not anatomical, not acceptable	Not judgeable	Not judgeable
6. Presence of steps in CC-joint					
7. Presence of gaps in CC-joint	No	≤ 2 mm (acceptable)	> 2 mm (not acceptable)	Not judgeable	Not judgeable
8. Presence of bone fragments in CC-joint					
PTC-joint					
9. Intra-articular protrusion of screws/K-wires in the CC joint	No	Subchondral (acceptable)	Yes, not acceptable	Not judgeable	Not judgeable
10. Symmetry/width of PTC-joint space	Anatomical	Not anatomical, but acceptable	Not anatomical, not acceptable	Not judgeable	Not judgeable
11. Presence of steps in PTC-joint space					
12. Presence of gaps in PTC-joint space	No	≤ 2 mm (acceptable)	> 2 mm (not acceptable)	Not judgeable	Not judgeable
13. Presence of bone fragments in PTC-joint space					
14. Intra-articular protrusion of screws/K-wires in the PTC joint	No	Subchondral (acceptable)	Yes, not acceptable	Not judgeable	Not judgeable

Table 1: (continued)

ATC-joint	15. Presence of steps in ATC-joint space	No	≤ 2 mm (acceptable)	> 2 mm (not acceptable)	Not judgeable
	16. Presence of gaps in ATC-joint space	No	≤ 2 mm (acceptable)	> 2 mm (not acceptable)	Not judgeable
	17. Presence of bone fragments in ATC-joint space	No	Subchondral (acceptable)	Yes, not acceptable	Not judgeable
Hardware	18. Intra-articular protrusion of screws/K-wires in the ATC joint	No	Moderate	Poor	Not judgeable
	19. Position of fixation plate(s)	Good	Moderate	Poor	Not judgeable
	20. Grip of screws/K-wires in sustentaculum	Exactly right	Quite near	Not at all	Not judgeable
	21. Grip of screws in anterior process	Exactly right	Quite near	Not at all	Not judgeable
	22. Protrusion of screws/K-wires in the medial wall	No	Yes, but acceptable	Yes, not acceptable	Not judgeable
	23. Medial protrusion of screws / K-wires in the tuberosity	No	Yes, but acceptable	Yes, not acceptable	Not judgeable
	24. Based on the radiologic evaluation alone, do you think a revision in reduction or fixation is indicated	No	Yes	Yes	Yes

Each of these multiple-choice questions was answered as: ‘optimal’, ‘suboptimal (but acceptable)’, ‘not acceptable (revision required)’ or ‘not judgeable’. In case of gaps and steps a threshold of 2 mm was held for acceptability.¹⁹ After scoring 23 items separately, a concluding dichotomous question was answered about whether any of the findings required correction (i.e. Yes or No). Statistical analyses were performed with SPSS (IBM SPSS Statistics for Windows, Version 22.0. Armonk, NY, USA).

Inter-rater reliability

We used a two-way random, average measures, absolute agreement intraclass correlation coefficient (ICC) to determine the degree of agreement amongst raters, including its 95% confidence interval (CI). As we used a fully crossed design (all subjects were rated by all raters) we chose a two-way model.²⁰ As we intended to generalize the results to a larger population of clinicians, we chose a random effects model.²¹ A good inter-rater reliability (IRR) was characterized by absolute agreement and not by consistency in the ratings. Concerning interpretation, we expect the protocol to be used in a clinical research environment where postoperative results are scored by more than one rater. Consequently, we primarily calculated the average-measures ICC. We used cutoffs as provided by Cicchetti et al., with reliability being ‘poor’ for ICC values less than 0.40, ‘fair’ for values between 0.40 and 0.59, ‘good’ for values between 0.60 and 0.74, and ‘excellent’ for values between 0.75 and 1.0.²² An ICC ≥ 0.60 was set as minimally acceptable level of agreement.²²

Intra-rater reliability

After a minimum of 30 days of scoring, raters were asked to again evaluate a selected subset of 25 CT scans that they had seen before but had been given a new study ID. These cases were selected to represent the full range of postoperative results, i.e. from anatomical reduction and correct screw positioning to large intra-articular step-offs, malreduced Böhler’s angle and intra-articular screws—and everything in between. Scoring results of both sessions were combined in a database per rater to analyze the degree of agreement within the observations (i.e. intra-rater reliability). In contrast to the inter-rater reliability, we used a two-way mixed, absolute agreement, single measures ICC. Because we wanted to determine the degree of agreement with the rater’s own ratings and do not intend to extrapolate this to a different rater.²¹ As for the inter-rater reliability, a good reliability was characterized by absolute agreement and not by consistency in the ratings. Again, cutoffs were used as provided by Cicchetti et al.²²

Table 2: Inter- and intra-rater reliability per item

	Inter-rater ICC (95% CI)	Intra-rater ICC (95% CI)			
		Rater 1	Rater 2	Rater 3	
Anatomy/ Reduction	Böhlers angle	0.49 (0.19-0.67)	0.62 (0.31-0.81)	0.47 (0.09-0.73)	0.72 (0.47-0.87)
	Gissanes angle	0.36 (0.13-0.55)	0.53 (0.19-0.76)	0.52 (0.16-0.76)	0.62 (0.29-0.81)
	Length of the calcaneus	0.11 (0.11-0.32)	0.00 (0.39-0.389)	0.57 (0.22-0.78)	0.30 (-0.10-0.61)
	Varus/varus of the tuber	0.21 (0.09- 0.44)	0.00 (0.33-0.36)	0.73 (0.48-0.87)	0.17 (-0.23-0.52)

Table 2: Continued

		Inter-rater ICC (95% CI)	Intra-rater ICC (95% CI)		
			Rater 1	Rater 2	Rater 3
CC joint	Symmetry/width	0.75 (0.65-0.82)	0.37 (0.01-0.66)	0.73 (0.48-0.87)	0.73 (0.48-0.87)
	Intra-articular steps	0.75 (0.65-0.83)	0.49 (0.12-0.74)	0.56 (0.24-0.78)	0.72 (0.46-0.87)
	Intra-articular gaps	0.63 (0.48-0.74)	0.65 (0.35-0.83)	0.45 (0.07-0.71)	0.71 (0.45-0.86)
	Intra-articular fragments	0.25 (0.73-0.86)	0.00 (-0.39-0.34)	0.47 (0.09-0.73)	Zero variance
	Intra-articular screws	0.80 (-0.31-0.34)	Zero variance	0.04 (-0.35-0.42)	0.00 (-0.39-0.39)
PTC joint	Symmetry/width	0.73 (0.62-0.81)	0.82 (0.64-0.92)	0.30 (-0.12-0.62)	0.51 (0.13-0.75)
	Intra-articular steps	0.76 (0.67-0.83)	0.86 (0.70-0.94)	0.75 (0.52-0.88)	0.61 (0.30-0.81)
	Intra-articular gaps	0.74 (0.63-0.82)	0.97 (0.93-0.99)	0.66 (0.37-0.84)	0.75 (0.52-0.88)
	Intra-articular fragments	0.46 (0.25-0.62)	0.01 (-0.40-0.40)	-0.04 (-0.44-0.36)	-0.02 (-0.41-0.37)
	Intra-articular screws	0.80 (0.72-0.86)	0.43 (0.05-0.71)	0.65 (0.35-0.83)	1.000
ATC joint	Intra-articular steps	0.38 (0.15-0.56)	0.77 (0.54-0.89)	0.65 (0.34-0.83)	0.51 (0.16-0.75)
	Intra-articular gaps	0.33 (0.09-0.52)	0.48 (0.10-0.73)	0.28 (-0.13-0.61)	0.18 (-0.23-0.54)
	Intra-articular fragments	0.41 (0.19-0.59)	1.00	0.65 (0.35-0.83)	0.22 (-0.16-0.55)
	Intra-articular screws	0.76 (0.66-0.84)	0.60 (0.29-0.80)	0.83 (0.65-0.92)	0.81 (0.61-0.91)
Positioning of	Plate	0.74 (0.63-0.81)	0.48 (0.13-0.73)	0.92 (0.82-0.96)	0.64 (0.33-0.82)
	Sustentaculum screws	0.64 (0.50-0.75)	0.51 (0.16-0.75)	0.49 (0.14-0.74)	0.47 (0.11-0.73)
	Anterior Process screws	0.26 (0.02-0.47)	0.30 (-0.11-0.62)	0.42 (0.05-0.70)	0.64 (0.32-0.82)
Screws protruding	Medial wall	0.70 (0.58-0.79)	0.34 (-0.06-0.64)	0.42 (0.03-0.70)	0.93 (0.84-0.97)
	Tuberosity	0.68 (0.55-0.77)	0.18 (-0.24-0.54)	0.68 (0.40-0.85)	0.89 (0.76-0.95)
Revision indicated		0.62 (0.46-0.73)	0.61 (0.29-0.80)	0.58 (0.25-0.79)	0.71 (0.46-0.86)
Overall		0.66 (0.64-0.69)	0.60 (0.55-0.65)	0.62 (0.56-0.66)	0.70 (0.66-.74)
Overall (only items with ICC ≥0.60 combined)		0.77 (0.74-0.79)	-	-	-

Bold items indicate an ICC ≥ 0.60

Results

The inter-rater reliability of the overall 23-item protocol was good: ICC of 0.66 (95% CI 0.64–0.69) (Table 2). Individual items that scored an inter-rater ICC ≥ 0.60 included the calcaneocuboid (CC) joint (symmetry/width, intra-articular steps, gaps and screws), the posterior talocalcaneal (PTC) joint (symmetry/width, intra-articular steps, gaps and screws), the anterior talocalcaneal (ATC) joint (intra-articular screws), the position of the plate and the sustentaculum screws and screws protruding the tuber and medial wall. Items that did not score acceptable interrater agreement (ICC < 0.60) included Böhler's and Gissane's angles, length of the calcaneus and varus/valgus position of the tuber, intra-articular fragments in CC, PTC or ATC joints, intra-articular gaps and step-offs in the ATC and the positioning of anterior process screws. When only the items that scored an acceptable ICC (ICC ≥ 0.60) were combined, the protocol scored 14 items (Table 2, marked grey) and had an excellent overall inter-rater reliability with an ICC of 0.77.

The intra-rater reliability for the overall protocol was good for all three individual raters with ICC's between 0.60 and 0.70. Individual raters scored acceptable ICC's for an average of 11 items. Items that scored an ICC ≥ 0.60 for all three raters included steps and gaps in the PTC joint and presence of intra-articular screws in the ATC joint. Items that did not score acceptable ICC's with any of the raters included length of the calcaneus, intra-articular fragments and screws in the CC joint, fragments in the PTC joint and gaps in the ATC joint.

Discussion

Our scoring protocol assessed quality of both reduction and hardware positioning and showed a good inter-rater reliability based on 300+ observations, suggesting sufficient reliability for use in clinical and research settings. It can aid future studies in the structural comparison of treatment results in the field of operatively treated calcaneal fractures, where there is currently no practicable alternative.

Calcaneal fractures are often complex and classification systems typically show poor to moderate inter-rater reliability.²³ Scoring protocols on the postoperative evaluation of these fractures are numerous, but often do not mention data on reliability or only focus on (parts of) fracture reduction.

In 2003, Gupta et al. used pre- and postoperative CT scans to measure seven displacement parameters in 32 calcaneal fractures. Measurements were done by a single rater without providing intra-rater reliability.¹² Sahota et al. focused on the postoperative alignment of the posterior facet.²⁴ They reported excellent inter-rater reliability between three independent raters by comparing ten postoperative CT scans. Kurozumi et al. evaluated parameters of calcaneal deformity by comparing postoperative CT images of both the injured and healthy contralateral side.¹³ They found better reduction of the posterior facet and better reduction of the calcaneocuboid joint to be prognostic factors of functional outcome but did not provide data on reliability of their measurements. In 2010, Magnan et al. performed postoperative CT analysis of 54 patients with calcaneal fractures using the

Score Analysis of Verona (SAVE).^{4,25} The SAVE scoring system was specifically designed for CT evaluation of calcaneal fractures and describes five displacement parameters.^{4,25} After a mean follow-up of 49 months, parts of the score showed statistical correlation with the clinical outcome. This was judged by the Maryland Foot Score: better clinical outcomes showed a significant association with vertical/longitudinal realignment and restoration of the calcaneal height.²⁵ Despite its correlation with clinical outcome, data on the reliability of the SAVE scoring system is currently unavailable. Finally, in 2014, Sanders et al. described a long-term follow-up of 108 surgically treated patients with his well-known Sanders classification.²⁶ In addition to his traditional fracture classification, he added measurements of posterior facet congruity, dividing the extent of anatomic reduction in four categories.²⁷ They confirmed that after 10–20 years of follow-up, the classification was still prognostic for outcome, as worsening outcome occurred with higher Sanders fracture types. However, included patients only had one of two types (Sanders II vs Sanders III). No data on reliability were published.

Although all abovementioned scoring systems were specifically designed for post-operative evaluation, none of them assessed hardware positioning such as presence of intra-articular or medially protruding screws. We have chosen to base this scoring protocol on CT imaging as it is currently the golden standard with respect to the visualization of intra-articular gaps, step-offs and hardware positioning.¹³ Nonetheless, despite its qualities, some measurements might be poorly visible on CT imaging. Böhler's and Gissane's angle measurements were originally designed for lateral radiographs. We hypothesized that estimation of these angles could be done by scrolling through the sagittal reconstructions of the CT-scan. In addition, as mentioned by Kurozumi et al., Böhler's angle comprises multiple factors: anterior lateral wall, PTC, and tuber displacement: all of which are evaluated separately with CT imaging.¹³ Still, in line with the existing literature, we did not produce high reliability of Böhler's and Gissane's angle measurements on CT.^{23,28}

The posterior talocalcaneal (PTC) is widely regarded as having the largest impact on post-operative complaints.^{8,29–32} In contrast to measurements of Böhler's angle, measurements of the PTC joint scored good agreement on four out of five items. The presence or absence of intra-articular bone fragments scored only fair agreement, possibly due to disagreement with regard to the posterior limits of the PTC joint.

On a statistical note, reliability analyses are frequently reported by the percentage that raters agree in their ratings, often referred to as percentage agreement. However, this measure systematically overestimates the level of agreement by not correcting for agreement that would be expected by chance alone.²⁰ The intraclass correlation or ICC is a measure that is suitable for ordinal, interval and ratio variables. It incorporates the magnitude of disagreement as does a weighted kappa but has the advantage that it can handle more than two raters.³³

To accurately calculate inter-rater reliability, sufficient variance in the observed cohort is indispensable. For instance, very low prevalence of intra-articular screws in the CC joint can cause a low ICC. The low variance for this item is expressed by a broad range of the 95% confidence interval, suggesting a low representability of the ICC.

Some items have a high inter-rater (> 0.6) but a low (<0.6) intra-rater reliability within individual raters. Raters can agree with each other at a certain moment, but not with themselves the next. This variability is inherent to classification systems, and in our case, does not hamper the good overall reliability of the scoring protocol.

Instead of exact measurements that are mostly performed in research settings, we have used subjective evaluations (e.g. good, moderate or poor). Subjective evaluation dismisses the need for tedious measurements, thereby allowing for a broader, more extensive evaluation without extending the burden of the task. In addition, subjective (categorical) and objective (numerical values) evaluations have previously proven to have a good correlation.³⁴ Moreover, during surgery no measurements can be performed and all the surgeon can do is estimate the quality of reduction and fixation, based on his experience with the acceptable angle measurements and distances.

This is also, where a potential underestimation of the inter-rater reliability comes in: we used raters with sufficient expertise, but a different background. A radiologists' perspective is likely to be different to that of a foot and ankle surgeon, especially when asked for a subjective opinion; e.g. the term "acceptable" could have different meanings for the two based on (a lack of) surgical experience. Undoubtedly, inter-rater reliability suffers from this phenomenon and is expected to be higher when rating is performed solely by experienced foot and ankle surgeons.

In the original study published in this journal we concluded that more items required evaluation than traditionally used in scoring protocols.¹⁷ However, the current study shows that many of the 23 items scored do not show sufficient inter-rater reliability. If we would design a protocol using only the items that scored an inter-rater reliability of 0.6 or higher, this protocol would evaluate 14 items and have an excellent reliability with an ICC of 0.77. This would, however, discard the previously mentioned consensus and potentially ignore items with high predictive value of functional outcome. Future studies should focus on identifying which items indeed correlate with functional outcome to help optimize the reliability and usability of the current protocol.

In conclusion, the results of the present study show that our previously developed scoring protocol for the radiological evaluation of operatively treated calcaneal fractures is reliable in regard to inter- and intra-rater reliability. The scoring protocol can be used in future clinical research settings that focus on the radiological comparison of operatively treated fractures of the calcaneus.

Acknowledgements

We would like to thank S. van Dieren (Clinical Epidemiologist, Department of Surgery, Academic Medical Center, Amsterdam) for her contribution to the statistical analysis of the data.

References

1. Franke J., Wendl K., Suda A.J., et al. Intraoperative three-dimensional imaging in the treatment of calcaneal fractures. *The Journal of Bone and Joint Surgery (American Volume)* 2014; 96: e72
2. Thordarson D.B., Krieger L.E. Operative vs. nonoperative treatment of intra-articular fractures of the calcaneus: A prospective randomized trial. *Foot & Ankle International* 1996; 17: 2–9.
3. Basile A. Subjective results after surgical treatment for displaced intra-articular calcaneal fractures. *The Journal of Foot and Ankle Surgery* 2012; 51: 182–6.
4. Sampath Kumar V., Marimuthu K., Subramani S., et al. Prospective randomized trial comparing open reduction and internal fixation with minimally invasive reduction and percutaneous fixation in managing displaced intra-articular calcaneal fractures. *International Orthopaedics* 2014; 38: 2505–12.
5. Bajammal S., Tornetta P., Sanders D., et al. Displaced intra-articular calcaneal fractures. *Journal of Orthopaedic Trauma* 2005; 19: 360–4.
6. Badillo K., Pacheco J.A., Padua S.O., et al. Multidetector CT Evaluation of Calcaneal Fractures. *Radiographics* 2011; 31: 81-92.
7. Dhillon M.S., Bali K., Prabhakar S. Controversies in calcaneus fracture management: A systematic review of the literature. *Musculoskeletal Surgery* 2011; 95, 171–81.
8. Sanders R. Displaced intra-articular fractures of the calcaneus. *The Journal of Bone and Joint Surgery (American Volume)* 2000; 82: 225–50.
9. Swanson S.A., Clare M.P., Sanders R.W. Management of intra-articular fractures of the calcaneus. *Foot and Ankle Clinics* 2008; 13: 659–78.
10. Parmar H.V., Triffitt P.D., Gregg P.J. Intra-articular fractures of the calcaneum treated operatively or conservatively. A prospective study. *The Journal of Bone and Joint Surgery (British Volume)* 1993;75: 932-7.
11. Schepers T., Ginai A.Z., Mulder P.G.H., et al. Radiographic evaluation of calcaneal fractures: To measure or not to measure. *Skeletal Radiology* 2007; 36: 847-52.
12. Gupta A., Ghalambor N., Nihal A., et al. The modified Palmer lateral approach for calcaneal fractures: Wound healing and postoperative computed tomographic evaluation of fracture reduction. *Foot & Ankle International* 2003; 24: 744–53.
13. Kurozumi T., Jinno Y., Sato T., et al. Open reduction for intra-articular calcaneal fractures: evaluation using computed tomography. *Foot & Ankle International* 2003; 24: 942–8.
14. Böhler L. Diagnosis, pathology and treatment of the os calcis. *The Journal of Bone and Joint Surgery (British Volume)* 1931; 75: 196–201.
15. Buckley R., Tough S., McCormack R., et al. Operative compared with nonoperative treatment of displaced intra-articular calcaneal fractures: A prospective, randomized, controlled multicenter trial. *The Journal of Bone and Joint Surgery (American Volume)* 2002; 84-A: 1733–44.

16. Richards P.J., Bridgman S. Review of the radiology in randomised controlled trials in open reduction and internal fixation (ORIF) of displaced intraarticular calcaneal fractures. *Injury* 2001; 32: 633–636.
17. Beerekamp M.S.H., Luitse J.S.K., Ubbink D.T., et al. Evaluation of reduction and fixation of calcaneal fractures: A Delphi consensus. *Archives of Orthopaedic Trauma Surgery* 2013; 133: 1377-84.
18. Beerekamp M.S.H., Ubbink D.T., Maas M., et al. Fracture surgery of the extremities with the intra-operative use of 3D-RX: a randomized multicenter trial (EF3X-trial). *BMC Musculoskeletal Disorders* 2011; 12: 151.
19. Rammelt S., Zwipp H. Calcaneus fractures: Facts, controversies and recent developments. *Injury* 2004; 35: 443–61.
20. Hallgren K.A. Computing inter-rater reliability for observational data: An overview and tutorial. *Tutorials in Quantitative Methods for Psychology* 2012; 8: 23–34.
21. McGraw K., Wong S. Forming inferences about some intraclass correlation coefficients. *Psychological Methods* 1996; 1: 30–46.
22. Cicchetti D.V. Multiple comparison methods: establishing guidelines for their valid application in neuropsychological research. *Journal of Clinical and Experimental Neuropsychology* 1994; 16: 155–61.
23. Veltman E.S., van den Bekerom M.P., Doornberg J.N., et al. Three-dimensional computed tomography is not indicated for the classification and characterization of calcaneal fractures. *Injury* 2014; 45: 1117-20.
24. Sahota R.K., Fleming J.J., Malay D.S. Reliability of a rating scale for assessing alignment of the posterior facet after surgical repair of joint depression fractures of the calcaneus. *The Journal of Foot and Ankle Surgery* 2014; 53: 259–264.
25. Magnan B., Samaila E., Regis, D., et al. Association between CT imaging at follow-up and clinical outcomes in heel fractures. *Musculoskeletal Surgery* 2010; 94: 113–17.
26. Sanders R., Vaupel Z., Erdogan M., et al. The Operative Treatment of Displaced Intra-articular Calcaneal Fractures (DIACFs): Long Term (10-20 years) results in 108 fractures using a prognostic CT Classification. *Journal of Orthopaedic Trauma* 2014; 28: 551-63.
27. Sanders R. Intra-articular fractures of the calcaneus: Present state of the art. *Journal of Orthopaedic Trauma* 1992; 6: 252–65.
28. Ogawa B.K., Charlton T.P., Thordarson D.B. Radiography versus Computed Tomography for Displacement Assessment in Calcaneal Fractures. *Foot & Ankle International* 2009; 30: 1005–1010.
29. Jin C., Weng D., Yang W., et al. Minimally invasive percutaneous osteosynthesis versus ORIF for Sanders type II and III calcaneal fractures: A prospective, randomized intervention trial. *Journal of Orthopaedic Surgery and Research* 2017; 12: 10.
30. Crosby L.A., Fitzgibbons T. Computerized tomography scanning of acute intra-articular fractures of the calcaneus. A new classification system. *The Journal of Bone and Joint Surgery (American Volume)* 1990; 72: 852–9.
31. Crosby L.A., Fitzgibbons T. Intraarticular calcaneal fractures. Results of closed treatment. *Clinical Orthopaedics and Related Research* 1993; 290: 47–54.

32. Rosenberg Z.S., Feldman F., Singson R.D. Intra-articular calcaneal fractures: computed tomographic analysis. *Skeletal Radiology* 1987; 16: 105–13.
33. Norman G.R., Streiner D.L. Biostatistics: The Bare Essentials. *BC Decker Inc, 2008*.
34. Heiney J.P., Redfern R.E., Wanjiku S. Subjective and novel objective radiographic evaluation of inflatable bone tamp treatment of articular calcaneus, tibial plateau, tibial pilon and distal radius fractures. *Injury* 2013; 44: 1127–34.

Part II

Intra-operative 3D-imaging in extremity fracture surgery



Chapter 5

Accuracy and consequences of 3D-fluoroscopy in upper and lower extremity fracture treatment – A systematic review

M.S.H. Beerekamp, G.S. Sulkers, D.T. Ubbink, M. Maas,
N.W.L. Schep, J.C. Goslings

European Journal of Radiology 2012; 81: 4019-28

Abstract

Objectives:

The aim of this systematic review was to compare the diagnostic accuracy, subjective image quality and clinical consequences of 3D-fluoroscopy with standard imaging modalities (2D-fluoroscopy, X-ray or CT) during reduction and fixation of intra-articular upper and lower extremity fractures.

Methods:

A systematic literature search was performed in MEDLINE, EMBASE and the Cochrane library. In total 673 articles were identified (up to March 2012). The 19 included studies described patients/cadavers with intra-articular upper/lower extremity fractures and compared 3D-fluoroscopy to standard imaging. The study was performed in accordance with the Quality Assessment of Diagnostic Accuracy Studies (QUADAS) guidelines. Diagnostic accuracy was defined by the quality of fracture reduction or implant position and, if possible, expressed as sensitivity and specificity; subjective image quality was determined by the quality of depiction of bone or implants; clinical consequences were defined as corrections in reduction or implant position following 3D-fluoroscopy.

Results:

Ten cadaver and nine clinical studies were included. A meta-analysis was not possible, because studies used different scoring protocols to express diagnostic accuracy and reported incomplete data. Based on the individual studies, diagnostic accuracy of 3D-fluoroscopy was better than 2D-fluoroscopy and X-ray, but similar to CT-scanning. Subjective image quality of 3D-fluoroscopy was inferior compared to all other imaging modalities. In 11–40% of the operations, additional corrections were performed after 3D-fluoroscopy, while the necessity for these corrections were not recognized based on 2D-fluoroscopic images.

Conclusions:

Although subjective image quality is rated inferior compared to other imaging modalities, intra-operative use of 3D-fluoroscopy is a helpful diagnostic tool for improving the quality of reduction and implant position in intra-articular fractures.

Introduction

Three-dimensional (3D)-fluoroscopic imaging was introduced in the late 1990s.¹⁻³ This imaging technique consists of a mobile C-arm unit, modified to provide a motorized rotational movement, combined with a workstation. This system provides multiplanar 3D-reconstruction of bony structures next to 2-dimensional (2D) fluoroscopic images.

3D-fluoroscopy was developed to gain more insight in fracture patterns and position of implants during fracture surgery. Traditional 2D-fluoroscopy alone often underestimates the degree of intra-articular fracture displacement and may not reveal the exact position of implants.^{4,5} Consequently, incorrectly positioned screws or incongruences can only be accurately detected on postoperative CT-scans, the current golden standard.^{6,7} The use of 3D-fluoroscopy may possibly solve these problems and provide the surgeon with accurate information on fracture reduction and implant position during the operation.

Only since the introduction of 3D-fluoroscopy in fracture surgery, more attention is given to the diagnostic accuracy of intraoperative imaging. Several cadaveric and clinical studies have been published describing the diagnostic accuracy and clinical use of 3D-fluoroscopy in fracture reduction and implant position. The first results of 3D-fluoroscopic images with high contrast phantom and fracture models are promising. The high contrast resolution of 3D-fluoroscopy was comparable to CT-scanning.^{3,8} In addition, the quality of fracture classification of the extremities was similar between 3D-fluoroscopy and CT-scanning.²

Hence, a systematic review of the available evidence on the additional diagnostic value of 3D-fluoroscopy and, if possible, a meta-analysis of these studies was considered timely. Therefore, the aim of this systematic review was to compare the diagnostic accuracy, subjective image quality and clinical consequences of 3D-fluoroscopy with standard imaging modalities (2D-fluoroscopy, X-rays or CT) during reduction and fixation of intra-articular upper and lower extremity fractures.

Materials and methods

This diagnostic systematic review was performed in accordance with the Quality Assessment of Diagnostic Accuracy Studies (QUADAS) statement.⁹

Search strategy and inclusion criteria

In collaboration with a clinical librarian, two authors (MSB and GS) jointly performed a formal computer-assisted search of the medical databases MEDLINE, EMBASE and the Cochrane Central Register of Controlled trials (up to March 2012). The search strategy was used for MEDLINE and adapted for each database (Table 1). Eligibility criteria were: diagnostic randomized controlled trials, diagnostic cohort or experimental studies; description of patients or cadavers with intra-articular upper or lower extremity fractures; assessment of the quality of fracture reduction and/or implant position by 3D-fluoroscopy and compared to a reference test such as 2D-fluoroscopy, X-ray, CT-scan or autopsy. Because implants influence the image quality, only studies describing reduction retained with implants were included. Studies describing a navigation technique were excluded.

Reported outcomes for diagnostic accuracy were sensitivity and/or specificity, expressing the correctness of reduction or implant position. In addition, other methods of expressing the diagnostic accuracy like quality of reduction or implant position in an ordinal scale (e.g. poor-good) or measurements of the size of gaps or step-offs were included. Fractures had to be fixated with any type of implant; e.g. fixation plate, screws, or K-wires. There were no restrictions for the type of material; e.g. stainless steel or titanium.

Clinical consequences after 3D-fluoroscopy were defined as a correction anticipated or performed in order to improve fracture reduction and/or implant position, based on the 3D-fluoroscopic images. Subjective image quality was determined by the quality of depiction of bone structures and implants. As there is no reporting standard for subjective image quality, any type of ordinal scoring was included in this review. The final decision about inclusion was based on the full text of the article. Disagreement was resolved by the consultation of a third reviewer.

Table 1: Search strategy

Key words	Synonyms used in search strategy
Fracture	((fracture) OR (fracture*))
AND	
3D-fluoroscopy	((3D-fluoroscopy) OR (three dimensional imaging) OR (3D imaging) OR (3-D rotational x-ray) OR (iso-c 3D) OR (image processing) OR (cone beam computed tomography) OR (cone beam CT) OR (3D-RX) OR (isocentric) OR (3D C-arm) OR (computer assisted image processing))
AND	
Intra-operative OR Cadaver	((intra-operative) OR (intraoperative) OR (per-operative) OR (peroperative) OR (peri-operative) OR (perioperative) OR (inter-operative) OR (interoperative) OR (cadaver) OR (cadaver*))

The search strategy in this table was used for MEDLINE and adapted for EMBASE and the Cochrane Central Register of Controlled trials. No limits as to language, year, publication type and status were applied. A manual search with cross-references of the eligible articles was performed to identify additional relevant articles.

Quality assessment

Two authors (MSB and GS) independently assessed the methodological quality of the included studies, using the 14 items of the QUADAS tool.⁹ All items were scored independently by the two reviewers, after which consensus was obtained in a meeting. The proportion of agreement between the two reviewers was expressed in percentages per item.

Data collection and statistical analysis

For all included studies, the first two authors (MSB and GS) extracted the data independently and, in case of disagreement, consensus was obtained. In order to determine diagnostic accuracy of the fracture reduction and implant position contingency tables were extracted, if possible. Hereby, the CT-scan or autopsy was used as reference test. In case

both a CT-scan as well as an autopsy was performed, the accuracy of the CT-scan was also cross tabulated with autopsy as reference standard. When data on sensitivity and/or specificity were missing, the authors of the studies were contacted by in order to retrieve the raw data. Unfortunately, the authors of the studies of interest did not respond or were unable to provide the raw data. If the quality of reduction and/or fixation was determined by an ordinal scoring protocol or measurements, the protocol description and the results were extracted.

We planned to pool data and calculate a mean sensitivity and specificity with its 95% confidence interval using the bivariate random effects model in a Bayesian algorithm (Openbugs, version 3.2.1).¹⁰ This model takes into account the differences in precision by which sensitivity and specificity have been measured within and across studies, and it incorporates and estimates the amount of between-study variability in both sensitivity and specificity. Data on image quality and clinical consequences were not expected to be standardized and were therefore not taken into account for further analysis but described separately.

Results

Literature search and quality assessment

The results of the literature search, study in- and exclusion are summarized in Figure 1. The results of the quality assessment are summarized in Figure 2. The third reviewer was consulted for one article, which was excluded.⁴ The cadaveric studies fulfilled on average 85% of the QUADAS criteria and the clinical studies 68%. Cadaver studies fulfilled most of the criteria, however in these studies uninterpretable results and withdrawals were not described. The proportion of agreement between the two reviewers ranged from 26% to 94%. Agreement was over 80% for four items and lower than 50% for two items. In the clinical studies, 3D-fluoroscopy was not performed independently of the results of 2D-fluoroscopy. The surgeon was aware of the results of 2D-fluoroscopy when evaluating the 3D-fluoroscopic images. In these studies, 3D-fluoroscopy formed part of the reference standard for the need of corrections in reduction or implant position.

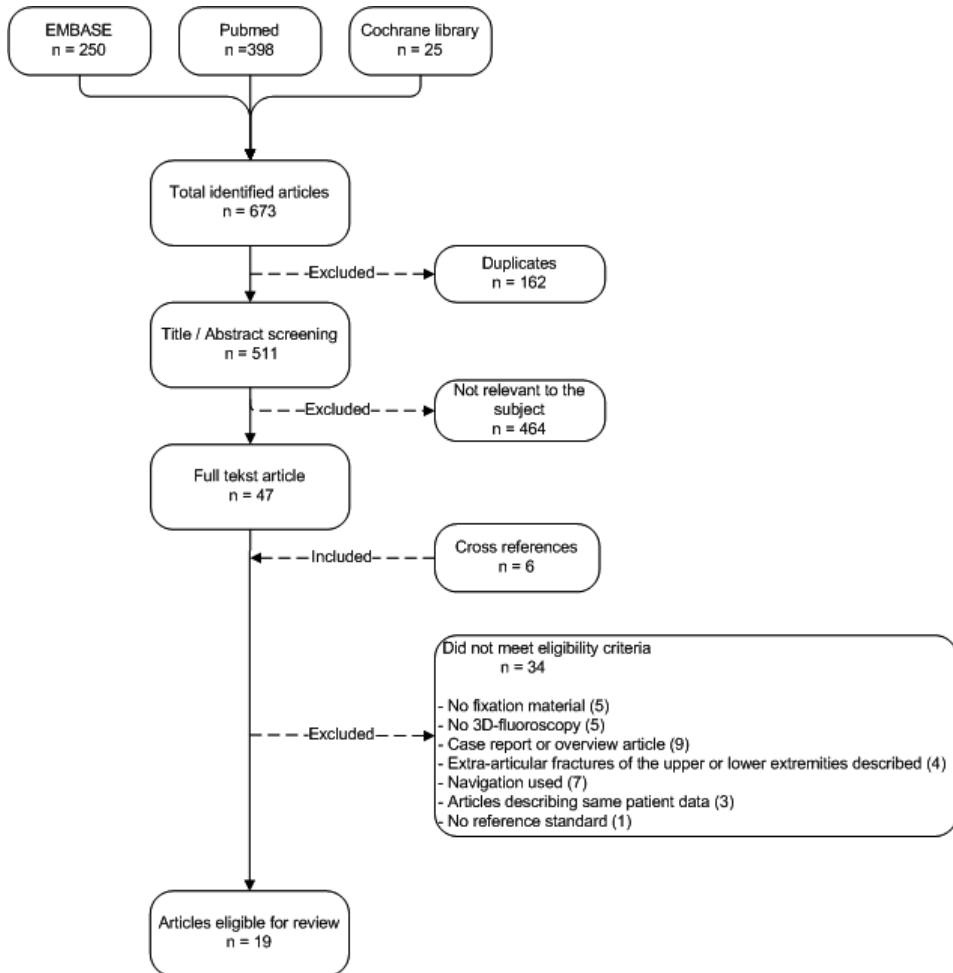


Figure 1: Results of the literature search
Flow diagram of articles in- or excluded in the systematic review

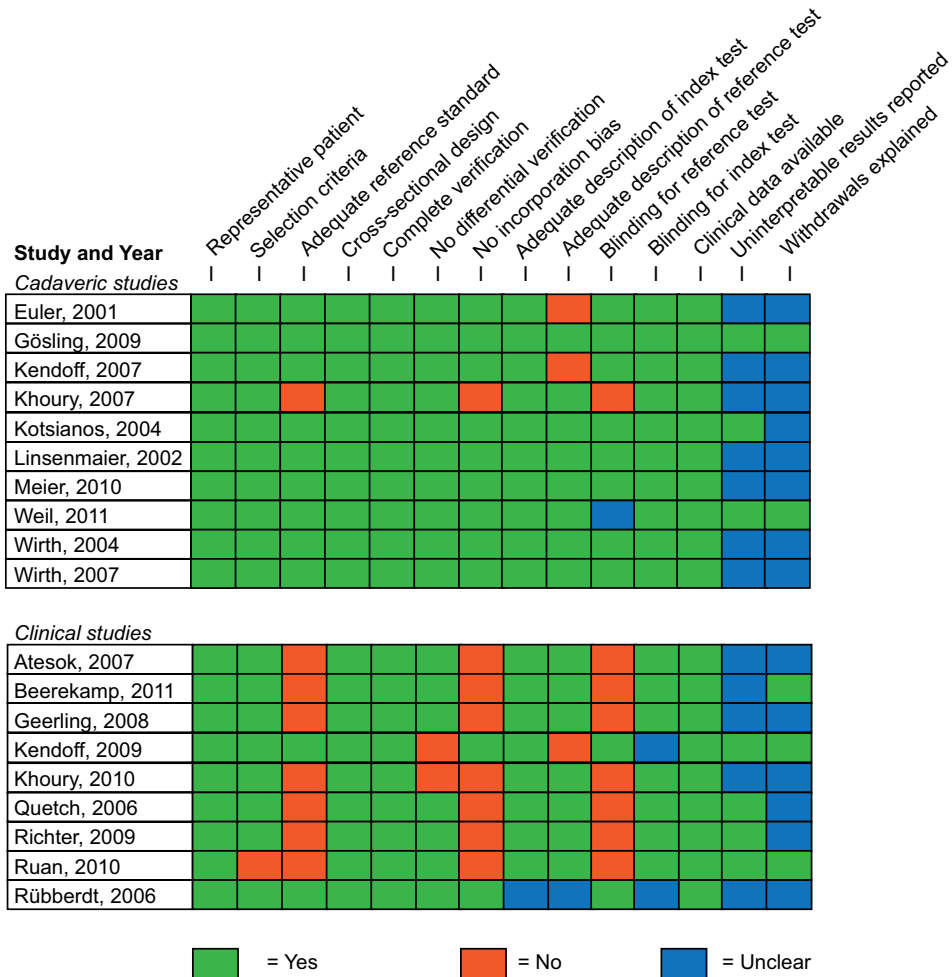


Figure 2: Quality Assessment of Diagnostic studies (QUADAS-tool)

Description of the studies

Of the 19 included studies, 10 were cadaver studies^{1,11-19} and 9 were clinical studies.²⁰⁻²⁸ The study characteristics are summarized in Table 2.

Cadaver studies

Fractures were created in six studies. In the studies of Gösling et al., Weil et al., and Meier et al., a cylinder of bone was removed from the articular surface with a channel reamer^{11,14,19} and in the study of Kendoff et al. a part of the calcaneus was osteotomized.¹² In these four studies, different amounts of step-offs were prepared under direct view. In the studies of Khoury et al. and Wirth et al. forces resembling the trauma mechanism were applied. Hereafter reduction was performed under 2D-fluoroscopy and the joint was dissected after imaging with the other modalities as described in Table 2.^{16,18} Kotsianos et al. used



cadaver knees of deceased trauma victims whose tibia plateau fractures were operatively reduced and fixated.¹⁷

Implant position was evaluated in seven studies (Table 2). Euler et al. and Linsenmaier et al. evaluated implant position in an intact talus.^{1,15} Khoury et al. inserted screws under direct vision, while the other studies inserted implants, both correct, and intentionally protruding through the articular surface, under 2D-fluoroscopic guidance and dissected after imaging.^{1,13,15-17}

3D-fluoroscopic scanning was performed according to the manufacturer's recommendations in all but two studies. These two studies, using the Siremobil Iso-C-3D, experimented with the rotation speed (slow or fast) and rotation arc (ranging from 120° to 190°), consequently leading to differences in the number of images made during the rotation and radiation dose. Gössling et al. used four different combinations of speed and rotation arc and Meier et al. six combinations.^{11,14}

Clinical studies

In all clinical studies patients requiring operative treatment for intra-articular extremity fractures were included. The affected joints are summarized in Table 2. Reduction and insertion of implants was performed under 2D-fluoroscopic guidance. 3D-fluoroscopy was used after reduction and final fixation in the studies of Geerling et al., Kendoff et al., and Ruan et al.^{20,24,25} Rübberdt et al. used 3D-fluoroscopy only after reduction.²² The other five clinical studies used 3D-fluoroscopy after reduction and temporal fixation or after final fixation depending on the surgeons' decision.^{21,23,26-28} In case corrections were performed after 3D-fluoroscopy a second 3D-scan was obtained at all times in the studies of Ruan et al. and Queitsch et al.^{20,23} The use of a second 3D-scan after corrections was dependent on the surgeons' insight in the four other clinical studies. Only in the study of Beerekamp et al. data on the number and type of corrections performed were collected retrospectively.²⁷

Diagnostic accuracy

Data reporting and analysis

Contingency tables to calculate sensitivity and/or specificity could only be extracted from data reported by the three cadaver studies of Kendoff et al., Wirth et al., and Linsenmaier et al. Kendoff et al. and Wirth et al. reported these data for both reduction as well as implant position.^{12,16} Linsenmaier et al. only reported on the latter.¹³ The results are summarized in Figure 3. In addition, the clinical study from Rübberdt et al. also reported on sensitivity and specificity of reduction and implant position, however from the reported data no contingency tables could be extracted, because data on true and false positives/negatives were not described clearly enough.²²

Figure 3 shows that only the study of Kendoff et al.¹² reported on both sensitivity and specificity of fracture reduction and Wirth et al. and Linsenmaier et al. of implant position.^{13,16} A meta-analysis was therefore not possible, because of incomplete data

reporting. Both cadaver studies of Gössling et al. and Weil et al. described the diagnostic accuracy by determining the deviation of the size of step-offs measured on the different modalities with the predefined step-off.^{11,14}

Euler et al., Wirth et al., and Meier et al. developed their own scoring protocol.^{1,15,19} Euler et al. and Wirth et al. scored the implant position on an ordinal scale as 'correct, unclear or misplaced'. In addition, the reviewers of the images were asked to make a final statement for the need to reposition or replace a screw, or that further imaging was necessary to determine the 'quality of diagnosis'. The correctness of the clinical consequence of the final statement led to a 'sum score', which was determined for the different imaging modalities and compared. Meier et al. also scored whether the reduction was 'correct, unclear or incorrect' and compared these among the different imaging modalities.

Table 2a: Study characteristics – Cadaveric studies

First author, year	Fractures included (nr)	Nr. of reviewers	Type of implants	C-arm type ^Δ	Studied errors		Diagnostic imaging modalities used				
					Reduction	Implant position	2D-fluoroscopy	3D-fluoroscopy	X-ray	CT-scan	Autopsy
Euler, 2001	Talus (4)	20	Screws	Siremobil Iso-C3D	-	✓	✓	✓	✓	✓	✓ [†]
Gösling, 2009	Tibia plateau (11)*	3	Screws	Siremobil Iso-C3D	✓	-	✓	✓	-	✓	✓ [†]
Kendoff, 2007	Calcaneus (8)**	3	K-wires & screws	Siremobil Iso-C3D	✓	✓	✓	✓	-	✓	✓ [†]
Khourry, 2007	Tibia plateau (3)	1	K-wires	Powermobil Iso-C-3D	✓	-	✓ [†]	✓	-	-	-
Kotsianos, 2004	Tibia plateau (8)***	7	External Fixator, Plates & screws (titanium or steel)	Siremobil Iso-C3D	-	✓	-	✓	-	✓ [†]	-
Linsenmaier, 2002	Talus (4)***	20	Screws	Siremobil Iso-C3D	-	✓	-	✓	-	✓ [†]	-
Meier, 2010	Distal radius (10)	4	Screw	Siremobil Iso-C3D	✓	✓	✓	✓	✓	✓	✓ [†]
Weil, 2011	Tibia plateau (6)****	1	Proximal tibia plate & screws	Siremobil Iso-C3D & C-insight	✓	-	-	✓	-	✓ [†]	-
Wirth, 2004	Talus (4)	20	Screws	Siremobil Iso-C3D	-	✓	✓	✓	✓	✓	✓ [†]
Wirth, 2007	Distal radius (4)	19	Volar plate & screws (stainless steel)	Siremobil Iso-C3D	✓	✓	✓	✓	✓	-	✓ [†]

* The same cadaver specimen was scanned with four different scoring protocols, differing in rotation speed (slow or fast) and rotational arc (120° or 190°)

** The same cadaver specimen was used in 7 trials with different sized step-offs

*** In the study more cadaver specimen were described; for this review only the ones with fixation material were included.

**** 10 scans were performed for each cadaver specimen and imaging modality

† Image modality used as reference standard

^Δ The Siremobil Iso-C-3D, Arcadisorbic 3D and the Powermobil Iso-C-3D are produced by Siemens, Erlangen, Germany. The BVPulsera with 3D-RX is produced by Philips Healthcare, Best, the Netherlands. The C-insight software is developed by Mazor Surgical Technologies, Caesarea, Israel

Table 2b: Study characteristics - Clinical studies

First author, year	Fractures included (nr)	Nr. of reviewers	Type of implants	C-arm type ^A	Studied errors				Diagnostic imaging modalities used		
					Reduction	Implant position	2D-fluoroscopy	3D-fluoroscopy	X-ray	CT-scan	Autopsy
Atesok, 2007	Various (72) Calcaneus, ankle, tibial plafond, tibial plateau, femoral head, acetabulum, distal radius	-	Screws & plates	Siremobil Iso-C3D	✓	✓	✓†	✓	-	-	-
					✓	✓	✓†	✓	-	-	-
Beerekamp, 2011	Various (94) shoulder, elbow, wrist, hand, knee, ankle, calcaneus, foot	Operating surgeon	Screws, plates & K-wires	BV Pulsera with 3D-RX	✓	✓	✓†	✓	-	-	-
					✓	✓	✓†	✓	-	-	-
Geerling, 2009	Calcaneus (32)	Operating surgeon	Screws & Plates	Siremobil Iso-C3D	✓	✓	✓†	✓	-	-	-
Kendoff, 2009	Various (129) Forefoot, Calcaneus, ankle, tibial plafond, tibial plateau, knee, pelvis, wrist or spine	-	Plates, Screws & K-wires	Siremobil Iso-C3D	✓	✓	✓	✓	-	-	✓†
					✓	✓	✓	✓	-	-	✓†
Khoury, 2010	Ankle (15)	Operating surgeon	K-wires & Screws	Siremobil Iso-C3D	✓	✓	✓†	✓	-	-	-
Quetsch, 2006	Calcaneus (58)	Operating surgeon	K-wires, screws & plates	Arcadis orbitc3D	✓	✓	✓†	✓	-	-	-
					✓	✓	✓†	✓	-	-	-
Richter, 2009	Various (124) Ankle, talus, hindfoot, cuboid and forefoot	Operating surgeon	K-wires, screws & plates	Siremobil Iso-C3D & Arcadis orbic 3D	✓	✓	✓†	✓	-	-	-
					✓	✓	✓†	✓	-	-	-
Ruan, 2011	Tibia plateau (30)	-	K-wires, screws & plates	Arcadis orbitc3D	✓	✓	✓†	✓	-	-	-
Rüberdt, 2006	Calcaneus (73)	2	K-wires, screws & plates	Siremobil Iso-C3D	✓	✓	✓	✓	-	-	✓†
Atesok, 2007	Various (72) Calcaneus, ankle, tibial plafond, tibial plateau, femoral head, acetabulum, distal radius.	-	Screws & plates	Siremobil Iso-C3D	✓	✓	✓†	✓	-	-	-
					✓	✓	✓†	✓	-	-	-

Legend for Table 2b (previous page)

△ The Siremobil Iso-C-3D, Arcadis orbic 3D and the Powermobil Iso-C-3D are produced by Siemens, Erlangen, Germany. The BV Pulsara with 3D-RX is produced by Philips Healthcare, Best, the Netherlands. The C-insight software is developed by Mazor Surgical Technologies, Caesarea, Israel

† Image modality used as reference standard

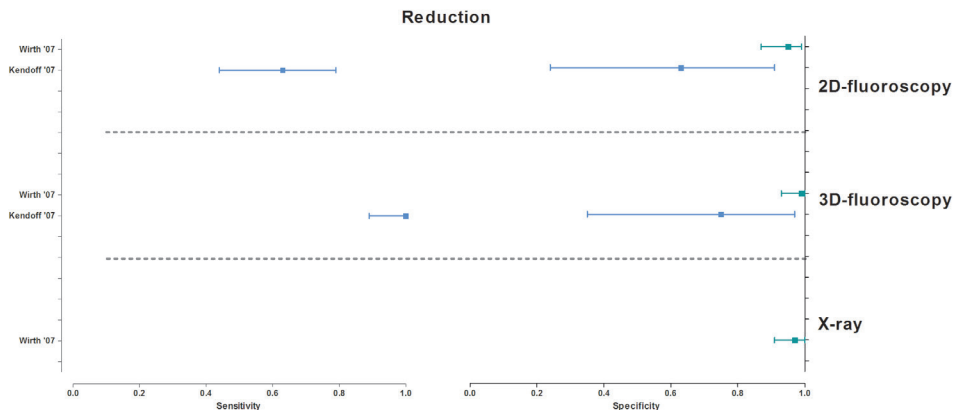


Figure 3a: Forest plots of the sensitivity and specificity of studies addressing fracture reduction. Sensitivity and/or specificity were determined by the correct assessment of the presence of intra-articular step-offs. The reference test is CT-scanning or autopsy as indicated in Table 2.

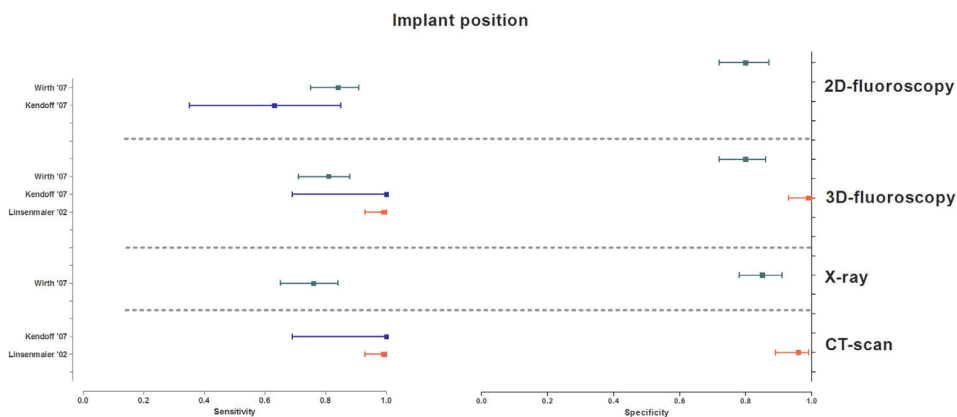


Figure 3b: Forest plots of the sensitivity and specificity of studies addressing implant placement. Sensitivity and/or specificity were determined by the correct assessment of the presence of intra-articular protrusion of screws. The reference test is CT-scanning or autopsy as indicated in Table 2.

Comparison 1: 2D-fluoroscopy versus 3D-fluoroscopy (6 studies)

Five cadaver studies evaluated implant position (Table 3). Three of these studies compared the correctness of the clinical consequences with their own ordinal scoring protocol. They all reported that diagnostic accuracy of 3D-fluoroscopy was significantly better with a significance level of $p < 0.001$.^{1,15,19} The cadaver study of Kendoff et al. showed that the sensitivity of 2D-fluoroscopy for the reduction (0.63, 95% confidence interval [0.44–0.79]) was significantly inferior ($p < 0.05$) to 3D-fluoroscopy (1.0 [0.89–1.0]). In contrast, specificity did not differ significantly (respectively, 0.63 [0.24–0.91] and 0.75 [0.35–0.97]). For detection of an intraarticular implant position, Kendoff described the sensitivity alone for both 2D-fluoroscopy (0.63 [0.35–0.85]) and 3D-fluoroscopy (1.0 [0.69–1.0]). This did not differ significantly (Figure 3).¹² Wirth et al. found no significant differences between 2D-fluoroscopy (0.95 [0.87–0.99]) and 3D-fluoroscopy (0.99 [0.93–1.0]) for the specificity of the reduction. The same holds for the sensitivity and specificity of the implant position which was, respectively, 0.81 [0.71–0.88] and 0.8 [0.72–0.87] for 2D-fluoroscopy and, respectively, 0.76 [0.65–0.84] and 0.8 [0.72–0.86] for 3D-fluoroscopy.¹⁶ Gössling et al. measured step-offs in the articular surface at five different reduction levels. He found that the absolute differences in millimeter were significantly more precise when measured with 3D-fluoroscopy ($p < 0.001$).¹¹

Comparison 2: X-ray versus 3D-fluoroscopy (4 studies)

Euler et al. and Wirth et al., reported that the diagnostic accuracy for the correctness of the clinical consequences, with their own ordinal scoring protocol, of X-rays for implant position is inferior to 3D-fluoroscopy with a significance level of $p < 0.001$.^{1,16} The studies of Wirth et al. and Rübberdt et al. reported data on sensitivity and/or specificity. Wirth et al. (Figure 3) showed that X-ray has a sensitivity (0.76 [0.65–0.84]) and specificity (0.85 [0.78–0.91]) when detecting intra-articular implant position, which was comparable to 3D-fluoroscopy (respectively, 0.81 [0.71–0.88] and 0.80 [0.72–0.86]). The same holds for the specificity of the reduction of X-ray (0.97 [0.91–1.0]) and 3D-fluoroscopy (0.99 [0.93–1.0]).¹⁶ Rübberdt et al. only described the likelihood ratios (LRs) for fracture gaps and steps. The positive LR for detecting gaps of 3D-fluoroscopy ($LR+ = 53.87 [5.74–19.81]$) was significantly better than X-ray ($LR+ = 4.56 [4.57–11.51]$). No other significant differences in positive and negative LR were found.²²

Table 3: Diagnostic accuracy of the different imaging modalities compared to 3D-fluoroscopy

First author, year	Method of describing diagnostic accuracy	2D-fluoroscopy	X-ray	CT-scan
Euler, 2001	‡Correctness of clinical consequence (ordinal) after evaluation of screw position and diagnostic certainty	<	<	=
Gösling, 2009	Precision of the estimated compared to given step-off (mm)	<	-	=*
Kendoff, 2007	Sensitivity and specificity; • Articular step-off (both quantitative as qualitative) • Intra-articular screw placement	< =	- -	= =
Linsenmaier, 2002	Sensitivity and specificity of intra-articular screw placement	-	-	=
Meier, 2010	‡Correctness of placement of the tip of the screw	<	-	=
Weil, 2011	Comparison of absolute differences between estimated and given step-off (mm)	-	-	=
Wirth, 2004	‡Correctness of intra-articular screw position and clinical consequence (ordinal)	<	<	=
Wirth, 2007	‡Sensitivity and specificity, calculated from ordinal scoring protocol of intra-articular screw placement and step-off	=	=	=
Rübberdt, 2006	Sensitivity and specificity; Likelihood ratio's Measurement of steps and gaps (mm)	- -	** -	- =

>: The study found that the diagnostic accuracy of this image modality was significantly better than 3D-fluoroscopy.

<: The study found that the diagnostic accuracy of this image modality was significantly worse than 3D-fluoroscopy.

=: The study found no significant differences for the diagnostic accuracy of this image modality compared to 3D- fluoroscopy

‡ Scoring protocol developed by authors

* One out of four 3D-fluoroscopic scanning protocols was significantly imprecise than CT

** Only the positive likelihood ratio for detecting gaps of 3D-fluoroscopy was significantly better than X-ray.

Comparison 3: CT-scan versus 3D-fluoroscopy (9 studies)

Figure 3b shows that both sensitivity and specificity for the assessment of implant position in 3D-fluoroscopy and CT-scan are similar. Linsenmaier et al. reported the same sensitivity for the implant position of both 3D-fluoroscopy and CT-scanning (0.99 [0.93–1.0]). Specificity of 3D-fluoroscopy (0.99 [0.93–1.0]) differed slightly from CT-scanning (0.96 [0.89–0.99]).¹³ Kendoff et al. reported only sensitivity, with the same results for both modalities (1.0 [0.69–1.0]).¹² Although Wirth et al. also found no significant differences between 3D-fluoroscopy and CT-scanning, values for both sensitivity and specificity were lower than the other two studies. For CT-scanning a sensitivity of 0.76 [0.65–0.84] and specificity of 0.85 [0.78–0.91] for implant position was found versus a sensitivity of 0.81 [0.71–0.88] and specificity of 0.80 [0.72–0.86] for 3D-fluoroscopy.¹⁶ No differences were found in the sum score of the correctness of the clinical consequences in the studies of Euler et al., Wirth et al., and Meier et al.^{1,15,19} Of the four different 3D-fluoroscopic scanning

protocols investigated by Gössling, only the deviations from the given step-off of the fast protocol with a rotational arc of 120° (0.5 mm) differed significantly from CT-scanning (0.3 mm). In the study of Weil, 11/20 measurements were similar between 3D-fluoroscopy and CT-scanning. The large majority of these differences were within 1–2 mm.¹⁴ Rübberdt et al. also measured the size of step-offs in different sectors of the posterior talocalcaneal joint and only found a significant mean difference in gap measurement in only one sector.²²

Subjective image quality

Data reporting and analysis

Four cadaver studies and one clinical study compared the subjective image quality of 3D-fluoroscopy with another modality (Table 4).^{1,13,15,17,20} In all these studies an ordinal scoring protocol was used. However, every study group had developed their own scoring protocol. Hereby image quality from different items like depiction of different bone structures and image noise of metal were scored par example from 'unacceptable to perfect'. Euler et al., Wirth et al., and Ruan et al. calculated a sum score of the subjective image quality scored on the different items separately.^{1,15,20}

The cadaver studies of Euler et al. and Wirth et al. on talus fractures compared the subjective image quality of 3D-fluoroscopy with 2D-fluoroscopy, X-ray and CT-scan.^{1,15} They concluded that the subjective image quality was significantly lower than these modalities.^{1,15} However in the clinical study of Ruan et al. the contrary was true for 2D-fluoroscopy: subjective image quality of 3D-fluoroscopy was significantly better.²⁰ The studies of Kotsianos et al. and Linsenmaier et al. both underpinned the conclusion that image quality of CT-scanning was superior to 3D-fluoroscopy.^{1,13,15,17}

Clinical consequences (10 studies)

One cadaver study and nine clinical studies reported on the (anticipated) clinical consequences after 3D-fluoroscopy (Table 5). Corrections after 3D-fluoroscopy are performed additional to corrections after 2D-fluoroscopy. Therefore, necessary corrections performed after 3D-fluoroscopy was not previously recognized on 2D-fluoroscopy. Reasons for additional corrections were malpositioned screws or unacceptable gaps and/or step-offs in the articular surface after reduction. After 3D-fluoroscopy additional corrections were performed in 11–40% of the procedures.^{18,20-28} Corrections in reduction were performed in 3- 40% of the procedures; corrections in implant position in 6-26% and corrections in a combination of both in 3–8% of the procedures.

Only four clinical studies reported the number of revision operations, following the initial operation, because of unacceptable fracture reduction and/or fixation. Despite the use of 3D-fluoroscopy, revision operations were still performed in 0–4% of the patients.^{23,25-27}

Table 4: Subjective image quality of the different imaging modalities compared to 3D-fluoroscopy

First author, year	Method of describing image quality	2D-fluoroscopy	X-ray	CT-scan
Euler, 2001	[‡] Sum score of ordinal scoring protocol; scoring image quality of cortical bone, spongy bone, image noise and artefacts.	>	>	>
	Ordinal scoring protocol; scoring the ability to correctly asses			
Kotsianos, 2004	<ul style="list-style-type: none"> • Depiction of bone structures * • Depiction of osteosynthesis* • Depiction of metal artefacts* • Depiction of system artefacts* 	-	-	>
	Adapted scoring protocol for image quality from Bahner et al. ³²			
Linsenmaier, 2002	<ul style="list-style-type: none"> • Subjective image noise • Delineation of cortical bone • Delineation of spongy bone • Delineation of joint surfaces 	-	-	>
Wirth, 2004	[‡] Ordinal scoring protocol; scoring image quality from unacceptable to perfect and quality of diagnosis	>	>	>
Ruan, 2011	[‡] Depiction of tibia plateau and screw placement	<	-	-

>: The study found that the subjective image quality of the image modality was significantly better than 3D-fluoroscopy.

<: The study found that the subjective image quality of the image modality was significantly worse than 3D-fluoroscopy.

[‡] Scoring protocol developed by authors

Table 5: The number of intra-operative corrections after 2D- & 3D fluoroscopy and the number of revision operations

First author, year	After 2D-fluoroscopy Percentage (n /total N)	After 3D-fluoroscopy Percentage (n /total N)				Revision operations Percentage (n /total N)
		Reduction	Implant position	Both	Total	
Khourry, 2007	33% (1/3)	33% (1/3)	-	-	33% (1/3)	-
Atesok, 2007	-	3% (2/72)	6% (4/72)	3% (2/72)	11% (8/72)	0% (0/72)
Beerekamp, 2011	24% (20/85)	-	-	-	15% (13/85)	1% (1/85)
Geerling, 2009	-	13% (4/32)	22% (7/32)	3% (1/32)	38% (12/32)	-
Kendoff, 2009	-	8% (20/248)	11% (26/248)	-	19% (46/248)	4% * (5/129)
Khoury, 2010	-	40% (6/15)	-	-	40% (6/15)	-
Quetsch, 2006	-	38% (22/58)	25% (1/4)	-	40% (22/58)	0%
Richter, 2009						
Iso-C-3D		19% (12/62)	26% (16/62)	7% (4/62)	39% (24/62)	-
Arcadis Orbit		15% (10/62)	26% (16/62)	8% (5/62)	34% (21/62)	-
Ruan, 2011	-	13% (4/30)	7% (2/30)	-	20% (6/30)	-
Rübberdt, 2006	-	7% (6/82)	12% (10/82)	-	20% (16/82)	-

*Postoperative CT-scans were performed in 50% of the patients

Discussion

With this systematic review, we evaluated the performance of 3D-fluoroscopy during treatment of intra-articular fractures of the upper and lower extremities compared to standard imaging techniques, in terms of diagnostic accuracy, subjective image quality and clinical consequences.

The diagnostic accuracy of 3D-fluoroscopy appears to be higher than 2D-fluoroscopy and X-ray and similar to CT-scanning for both reduction and implant position. The studies, using measurements or ordinal scoring protocols, support this finding.^{1,11-15,19} Unfortunately, a meta-analysis, calculating summary sensitivity and specificity values, was not possible due to heterogeneity of reported outcomes, and incomplete reporting of data by the individual studies.

However, the subjective image quality of 3D-fluoroscopy appears to be inferior to all other imaging modalities. Still, the actual and anticipated correction rate after 3D-fluoroscopy indicates that this modality provides more information than both 2D-fluoroscopy and X-ray to detect unacceptable reduction and malpositioned screws.^{18,21-29} The subjective quality of 3D-fluoroscopy was scored inferior to all other imaging modalities by two German studies, while the diagnostic accuracy was superior.^{1,15} An explanation for this controversy could be that every image modality has its own maximum achievable quality. Subjective image quality provides information about the degree of the focus of the image, even though the image(s) itself provides less information. In the presence of fixation material, the focus of 3D-fluoroscopic images decreases relatively more, due to scattering and artifacts of implants, which yields lower ratings than with 2D-fluoroscopy.

The overall quality of the included studies was good. Both cadaver (85%) and clinical (68%) studies fulfilled most of the QUADAS criteria. However, in the clinical studies there was a clear risk of incorporation bias, because the results of the 3D-fluoroscopy were incorporated in the reference standard. Besides, like any other systematic review, this review was subject to potential publication bias. No attempt was made to identify unpublished studies.

Although the cadaver studies were designed to represent the clinical setting, still the diagnostic accuracy could potentially be overestimated. In these research settings, optimal circumstances could be created, while in clinical practice influences like time pressure, suboptimal positioning or the use of an OR-table with metal sidebars could negatively influence the diagnostic accuracy. In order to make sure that the procedure in the cadaver studies represents the clinical setting, we only included studies evaluating fracture reduction retained by implants. This is a better reflection of clinical practice in which 3D-fluoroscopy is used after internal fixation of the fracture with stainless steel or titanium implants and not in the preoperative planning.

It was expected that the diagnostic accuracy would be similar for the different joints of the extremities. However, differences in diagnostic accuracy between 2D- and 3D-fluoroscopy and the clinical consequences can also be explained by differences in size and/or complexity

of the joint. In the study of Wirth et al., describing distal radius fractures no differences in diagnostic accuracy were found.¹⁶ In addition, the number of extra corrections was higher when only ankle and calcaneus fractures were investigated.^{21,23,24,28}

An important finding contributing to the heterogeneity of outcome parameters is the absence of consensus in the literature on how to evaluate reduction and fixation. The same holds for the cut-off point that should be used for a suboptimal operation result. All authors of the included studies developed their own radiological scoring protocol that covered different aspects of the fracture reduction and/or fixation. The reason that these scoring protocols are not widely accepted might indicate that they are not blankets. Therefore, we propose a consensus-based scoring protocol for each joint separately to increase uniformity in the radiological evaluation and outcome parameters of intraarticular fractures. The basis for a scoring protocol has already been proposed for wrist and ankle fractures by the authors.³⁰ In addition, technical improvements of the 3D-C-arms should be made to improve the image quality and decrease image noise due to fixation material.

For now, intra-operative 3D-fluoroscopy is a promising and helpful diagnostic tool in the reduction and fixation of intra-articular fractures of the upper and lower limbs. Complete reporting of data on sensitivity and specificity is necessary to enable an accurate estimation of the sensitivity and specificity of 3D-fluoroscopy. In addition, uniform outcome scoring of the quality of fracture reduction, for each joint separately is desirable to enable comparison between studies. Our research group is performing a multicenter randomized trial, the EF3X-trial (extremity fractures with the intra-operative use of 3D-RX-imaging), to accurately estimate the diagnostic accuracy of 3D-fluoroscopy in clinical practice. In addition, the patient related outcomes will be reported to determine the clinical effectiveness of intra-operative 3D-fluoroscopy in intra-articular wrist, ankle and calcaneus fractures (Dutch Trial Register: NTR 1902).³¹

Acknowledgements

We would like to thank Prof. A.H. Zwinderman of the Clinical Research Unit of the Academic Medical Center in Amsterdam (NL) for his help in determining the best method for the meta-analysis. We are very grateful for the help of Hanny Vriends (clinical librarian in the Academic Medical Center in Amsterdam), who provided assistance with the study search.

References

1. Euler E., Wirth S., Linsenmaier U., et al. Comparative study of the quality of C-arm based 3D imaging of the talus. *Unfallchirurg* 2001; 104: 839–46.
2. Kotsianos D., Rock C., Euler E., et al. 3-D imaging with a mobile surgical image enhancement equipment (ISO-C-3D). Initial examples of fracture diagnosis of peripheral joints in comparison with spiral CT and conventional radiography. *Unfallchirurg* 2001; 104: 834–8 (2001).
3. Rock C., Linsenmaier U., Brandl R., et al. Introduction of a new mobile C-arm/CT combination equipment (ISO-C-3D). Initial results of 3-D sectional imaging. *Unfallchirurg* 2001; 104: 827–33.
4. Carelsen B., Haverlag R., Ubbink D.T., et al. Does intraoperative fluoroscopic 3D imaging provide extra information for fracture surgery? *Archives of Orthopaedic Trauma Surgery* 2008; 128: 1419–24.
5. Ebraheim N., Sabry F.F., Mehalik J.N. Intraoperative imaging of the tibial plafond fracture: a potential pitfall. *Foot & Ankle International* 2000; 21: 67–72.
6. Johnston G.H., Friedman L., Kriegler J.C. Computerized tomographic evaluation of acute distal radial fractures. *The Journal of Hand Surgery (American Volume)* 1992; 17: 738–44.
7. Rozental T.D., Bozentka D.J., Katz M.A., et al. Evaluation of the sigmoid notch with computed tomography following intra-articular distal radius fracture. *The Journal of Hand Surgery (American Volume)* 2001; 26: 244–51.
8. Rock C., Kotsianos D., Linsenmaier U., et al. Studies on image quality, high contrast resolution and dose for the axial skeleton and limbs with a new, dedicated CT system (ISO-C-3 D). *Rofo* 2002; 174: 170–6.
9. Whiting P., Rutjes A.W.S., Reitsma J.B., et al. The development of QUADAS: a tool for the quality assessment of studies of diagnostic accuracy included in systematic reviews. *BMC Medical Research Methodology* 2003; 3: 25.
10. Bipat S., Zwinderman A.H., Bossuyt P.M.M., et al. Multivariate random-effects approach: For meta-analysis of cancer staging studies. *Academic Radiology* 2007; 14: 974–84.
11. Gösling, T., Klingler K., Geerling J, et al. Improved intra-operative reduction control using a three-dimensional mobile image intensifier - a proximal tibia cadaver study. *The Knee* 2009; 16: 58–63.
12. Kendoff D., Citak M., Gardner M., et al. Three-dimensional fluoroscopy for evaluation of articular reduction and screw placement in calcaneal fractures. *Foot & Ankle International* 2007; 28: 1165–71.
13. Linsenmaier U., Rock C., Euler E., et al. Three-dimensional CT with a modified C-arm image intensifier: Feasibility. *Radiology* 2002; 224: 286–92.
14. Weil Y.A., Liebergall M, Mosheiff R., et al. Assessment of two 3-D fluoroscopic systems for articular fracture reduction: A cadaver study. *International Journal of Computer Assisted Radiology and Surgery* 2011; 6: 685–92.

15. Wirth S., Euler E., Linsenmaier U., et al. C-arm-based mobile computed tomography: A comparison with established imaging on the basis of simulated treatments of talus neck fractures in a cadaveric study. *Computer Aided Surgery* 2004; 9: 27–38.
16. Wirth S., Euler E., Kotsianos D., et al. Comparison of C-arm CT and standard imaging in osteosyntheses of fractured distal radius specimens. *Unfallchirurg* 2007; 110: 41–8.
17. Kotsianos D., Wirth S., Fischer T., et al. 3D imaging with an isocentric mobile C-arm comparison of image quality with spiral CT. *European Radiology* 2004; 14: 1590–5.
18. Khoury A., Siewerdsen J.H., Whyne C.M., et al. Intraoperative cone-beam CT for image-guided tibial plateau fracture reduction. *Computer Aided Surgery* 2007; 12: 195–207.
19. Meier R., Geerling J., Hüfner T., et al. The isocentric C-arm. Visualization of fracture reduction and screw position in the radius. *Unfallchirurg* 2011; 114: 587–90.
20. Ruan Z., Luo C., Feng D., et al. Intraoperative three-dimensional imaging in tibial plateau fractures with complex depressions. *Technology and Health Care* 2011; 19: 71–7.
21. Khoury A., Atesok K., Liebergall M., et al. The role of ISO-C3D in crush injuries to the distal lower syndesmosis. *Current Orthopaedic Practice* 2011; 22: 167–170.
22. Rübberdt A., Feil R., Stengel D., et al. The clinical use of the ISO-C(3D) imaging system in calcaneus fracture surgery. *Unfallchirurg* 2006; 109: 112–8.
23. Queitsch C., Schulz A.P., Haustedt N., et al. Improved therapy of calcaneal fractures by intraoperative 3D-fluoroscopy and locked-screw plate fixation. *European Journal of Trauma* 2006; 32: 471–476.
24. Geerling J., Kendoff D., Citak M., et al. Intraoperative 3D imaging in calcaneal fracture care-clinical implications and decision making. *The Journal of Trauma* 2009; 66: 768–73.
25. Kendoff D., Citak M., Gardner M.J., et al. Intraoperative 3D imaging: Value and consequences in 248 cases. *The Journal of Trauma* 2009; 66: 232–8.
26. Atesok K., Finkelstein J., Khoury A., et al. The use of intraoperative three-dimensional imaging (ISO-C-3D) in fixation of intraarticular fractures. *Injury* 2007; 38: 1163–9.
27. Beerekamp M.S.H., Haverlag R., Luitse J.S.K.; Ubbink D.T., Goslings J.C. Het peroperatieve gebruik van 3D-beeldvorming bij fracturen aan de extremiteiten. *Nederlands Tijdschrift voor Trauma* 2011; 2–8.
28. Richter M., Zech S. Intraoperative 3-dimensional imaging in foot and ankle trauma - Experience with a second-generation device (ARCADIS-3D). *Journal of Orthopaedic Trauma* 2009; 23: 213–220.
29. Ruan Z., Luo C., Shi Z., et al. Intraoperative reduction of distal tibiofibular joint aided by three-dimensional fluoroscopy. *Technology and Health Care* 2011; 19: 161–6.
30. Beerekamp M.S.H., Haverlag R., Ubbink D.T., et al. How to evaluate the quality of fracture reduction and fixation of the wrist and ankle in clinical practice: a Delphi consensus. *Archives of Orthopaedic Trauma Surgery* 2011; 131: 739–46.

31. Beerekamp M.S.H., Ubbink D.T., Maas M., et al. Fracture surgery of the extremities with the intra-operative use of 3D-RX: a randomized multicenter trial (EF3X-trial). *BMC Musculoskeletal Disorders* 2011; 12: 151.
32. Bahner M.L., Reith W., Zuna I., et al. Spiral CT vs incremental CT: Is spiral CT superior in imaging of the brain? *European Radiology* 1998; 8: 416–20.



Chapter 6

Effects of intra-operative fluoroscopic 3D-imaging on perioperative strategy in calcaneal fracture surgery

M.S.H. Beerekamp, M. Backes, N.W.L. Schep, D.T. Ubbink,
J.S.K. Luitse, T. Schepers, J.C. Goslings

Archives of Orthopaedic Trauma Surgery 2017; 137: 1667-75.

Abstract

Introduction

Previous studies demonstrated that intra- operative fluoroscopic 3D-imaging (3D-imaging) in calcaneal fracture surgery is promising to prevent revision surgery and save costs. However, these studies limited their focus to corrections performed after 3D-imaging, thereby neglecting corrections after intra-operative fluoroscopic 2D-imaging (2D-imaging). The aim of this study was to assess the effects of additional 3D-imaging on intra-operative corrections, peri-operative imaging used, and patient-relevant outcomes compared to 2D-imaging alone.

Patients and methods

In this before–after study, data of adult patients who underwent open reduction and internal fixation (ORIF) of a calcaneal fracture between 2000 and 2014 in our level-I Trauma center were collected. 3D-imaging (BV Pulsera with 3D-RX, Philips Healthcare, Best, The Netherlands) was available as of 2007 at the surgeons' discretion. Patient and fracture characteristics, peri-operative imaging, intra-operative corrections and patient-relevant outcomes were collected from the hospital databases. Patients in whom additional 3D-imaging was applied were compared to those undergoing 2D-imaging alone.

Results

A total of 231 patients were included of whom 107 (46%) were operated with the use of 3D-imaging. No significant differences were found in baseline characteristics. The median duration of surgery was significantly longer when using 3D-imaging (2:08 vs. 1:54 h; $p = 0.002$). Corrections after additional 3D-imaging were performed in 53% of the patients. However, significantly fewer corrections were made after 2D-imaging when 3D-imaging was available (Risk difference (RD) -15% ; 95% Confidence interval (CI) -29 to -2). Peri-operative imaging, besides intra-operative 3D-imaging, and patient-relevant outcomes were similar between groups.

Conclusion

Intra-operative 3D-imaging provides additional information resulting in additional corrections. Moreover, 3D-imaging probably changed the surgeons' attitude to rely more on 3D-imaging, hence a 15%-decrease of corrections performed after 2D-imaging when 3D imaging was available. No substantiation for cost reduction was found through reduction in perioperative imaging or in terms of improved patient-relevant outcomes.

Introduction

Restoration of anatomy to optimize functional outcome and lower the rate of secondary fusions is the main goal in calcaneal fracture surgery. Several research groups have described different pre-operative radiological fracture characteristics and measurements related to functional outcome.¹⁻³ Others have evaluated postoperative restoration of anatomy in relation to functional outcome.^{4,5}

Intra-operative fluoroscopic 3D-imaging (3D-imaging), providing a reconstruction in slice images in the axial, coronal and sagittal planes as well as 3D volume rendering, in addition to conventional intra-operative fluoroscopic 2D-imaging (2D-imaging), may help evaluate the restoration of the anatomy and implant position. Since its introduction, more attention is given to the effect of the available intra-operative imaging modalities.⁶ Most authors have focused solely on the number and type of corrections performed after additional 3D-imaging⁷⁻¹⁵, suggesting that these additional corrections prevent revision surgery and reduce costs. However, little is known about the effect of the availability of intra-operative 3D-imaging on the surgeons' attitude towards intra-operative 2D-imaging. In addition, little is known about the effects of intra-operative 3D-imaging on peri-operative imaging strategies, in terms of the evaluation of fracture characteristics, planning of the surgical procedure, postoperative evaluation of restoration of anatomy and implant position, and patient outcome.¹⁶

Hence, the aim of this study was to assess the effects of intra-operative use of fluoroscopic 3D-imaging in patients with a calcaneal fracture on the number and type of intra-operative corrections of reduction and implant position, pre- intra- and postoperative (peri-operative) imaging used, and patient-relevant outcomes in terms of revision surgery, secondary fusions and infectious complications.

Methods

In this before–after study, data of all patients with open reduction and internal fixation (ORIF) of a displaced intra-articular calcaneal fracture admitted to our academic level-1 trauma center from January 2000 until June 2014 were retrospectively collected. Potential eligible patients were detected with the corresponding operative procedure code. Patients were eligible for this study when ORIF was performed with the aim to restore anatomy. Patients younger than 18 years of age and patients with primary arthrodesis, revision of ORIF performed elsewhere and patients participating in a randomized trial (the EF3X-trial) that influenced the imaging strategy, were excluded.¹⁷ Intra-operative fluoroscopic 3D-imaging was clinically available in our hospital in 2007. 3D-imaging was applied intra-operatively at the surgeons' discretion and the availability of the 3D-C-arm. Patient and fracture characteristics were collected from the hospitals electronic databases. This included age, gender, Body Mass Index (BMI), American Society of Anesthesiologists (ASA) classification and relevant risk factors like diabetes mellitus and smoking. Other variables were the trauma mechanism, Injury Severity Score (ISS), fracture side, presence of an open fracture, bilateral fracture and presence of a fracture of the ipsilateral foot/ankle. Calcaneal fractures were classified according to the Sanders classification.¹⁸ The time between the fracture and surgery was recorded and expressed in days.

Types of pre- and postoperative radiological exams of the calcaneus were extracted from the patients' radiology charts. Surgery reports were reviewed to determine duration of surgery, types of intra-operative imaging used, and the number and type of surgical corrections performed during the same procedure following 2D- and 3D- fluoroscopic imaging. Both 2D- and 3D-imaging could be used at the surgeons' discretion at any time during surgery when 3D-imaging was available. Corrections were defined as a description of a revision of the reduction (for example intra-articular step-off, gap or tuber position) or a revision of the fixation (for example plate position or screw length or position). In case the implants had to be removed to correct the reduction, this was only counted as a correction in reduction. Patient outcomes, defined as the number of revision operations, wound complication rates, implant removal and number of secondary arthrodesis were determined by reviewing the patient chart until October 2015, resulting in a minimum follow-up duration of 15 months.

Intra-operative fluoroscopic imaging

Both intra-operative fluoroscopic 2D- and 3D-imaging were performed with the BV Pulsera with 3D-RX (3-Dimensional Rotational X-ray).⁹ The BV Pulsera (Philips Healthcare, Best, the Netherlands) consists of a mobile C-arm unit modified to provide a motorized rotational movement and is combined with a Philips 3D-RA workstation. For a single 3D scan, a series of 225 2D-fluoroscopic images is acquired over a period of 30 s during a 200° rotation of the C-arm (Figure 1). The projection images are used to reconstruct a 3D data set. Both volume-rendering and slice images in the axial, coronal and sagittal planes were available. The slice images were considered to provide the best information and were used solely in clinical practice (Figure 2). From autumn 2005, 3D-imaging of the BV Pulsera was used in a research setting; from 2007, the BV Pulsera was clinically available. From 2009, the images could be enhanced by coloring the metal implants present (Titanview software, Philips Health-care, Best, the Netherlands).

The radiation exposure of each image in the scanning run is dynamically adjusted to provide the best combination of low dose and optimal image quality. The maximum equivalent dosage of a 3D scan of the calcaneus with the BV Pulsera is 17 mSv. Because 3D-imaging is more time-consuming and requires additional preparation to remain sterility, 3D-imaging was used additional to 2D-imaging at the surgeon's preference.

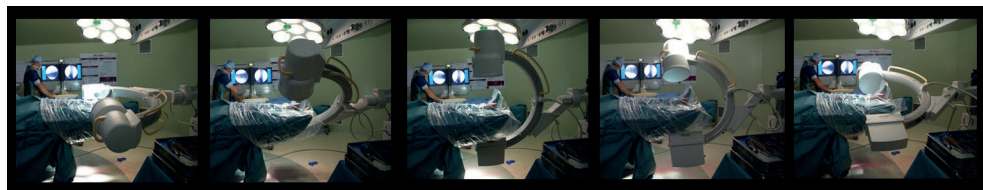


Figure 1: Rotation of the 3D-RX-system

For a single 3D-scan with the BV Pulsera (Philips Medical Systems, Best, the Netherlands) a series of 225 2D-fluoroscopic images are acquired over a period of 30 seconds during a motorized 200° rotation of the C-arm. The projection images are used to reconstruct a 3D dataset.

Statistical analysis

Descriptive statistics were applied to analyze baseline and peri-operative characteristics and patient outcomes using the Statistical Package for the Social Sciences (SPSS version 23, IBM, Armonk, NY, USA) and Openepi (version 3.01, online resource).¹⁹ Patients were divided into two groups depending on whether or not intra-operative fluoroscopic 3D-imaging was conducted (No-3D group, 3D group). Continuous data with a normal distribution were expressed as means with standard deviations. Mean differences with their 95% confidence intervals were calculated. Non-normally distributed data were expressed as medians with their range and tested with the Mann-Whitney *U* test. A *p*-value of <0.05 was considered significant. Proportional data of the categorical data were given and expressed as risk differences and risk ratios, both with 95% confidence intervals.

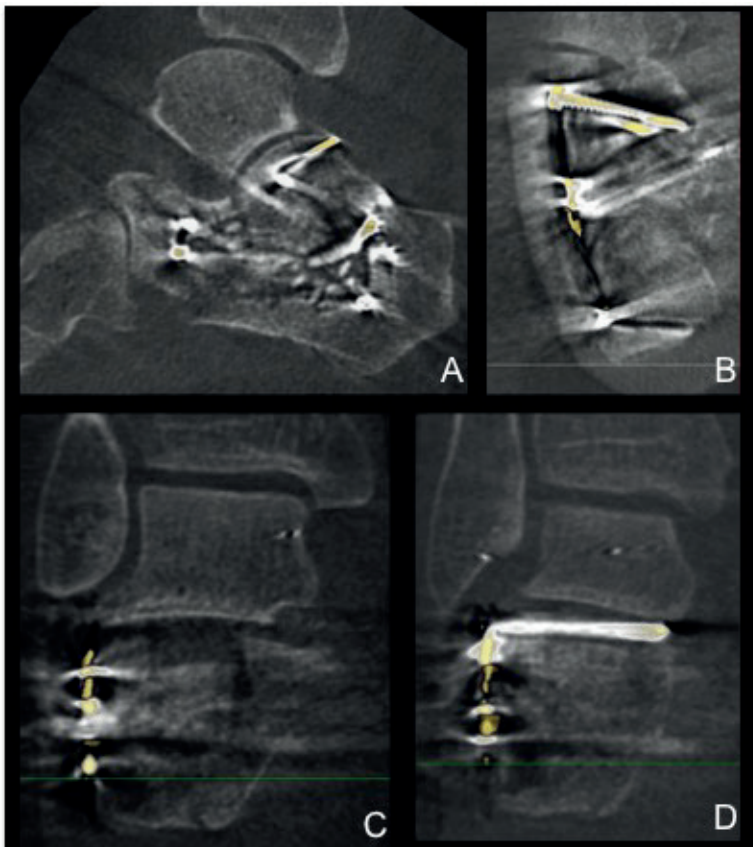


Figure 2: 3D-images of intra-articular step, gap and implant position of the calcaneus Sagittal(A), axial (B) and coronal slice images (C and D) of intra-operative fluoroscopic 3D-imaging. Titanview software is used to color the metal implants present (Titanview software, Philips Healthcare, Best, the Netherlands).
 A: Step-off in calcaneocuboid (CC) joint
 B: Gap in calcaneocuboid (CC) joint
 C: Step-off in posterior talocalcaneal (PTC) joint
 D: Intra-articular position of a screw in the posterior talocalcaneal (PTC) joint

Results

Patient inclusion

During the inclusion period, 388 patients were identified (Figure 3), of whom 171 were excluded because of their age (<18 years), a primary arthrodesis, participation in another trial or because of a previous ORIF of the calcaneus elsewhere. In 107 of the 231 included patients (46%) intra-operative 3D-imaging was used.

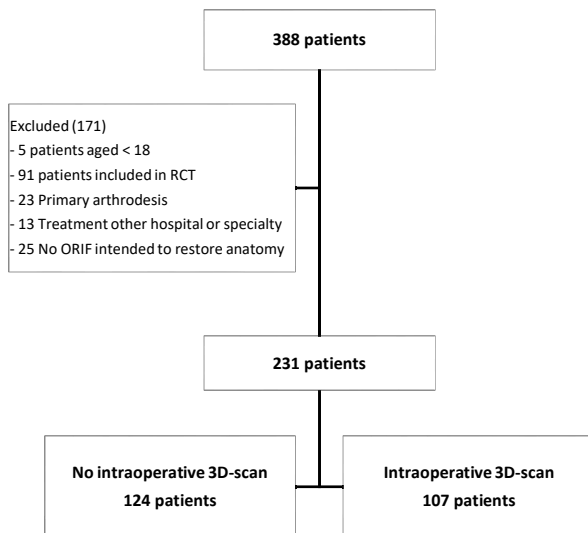


Figure 3: Flowchart of patient inclusion

Baseline characteristics

No differences were found in baseline characteristics between the two patient groups (Table 1). Patients in the No-3D- and 3D-groups had a mean age of 43 versus 45 years, respectively [mean difference 1.87 (95% CI -4.4 to 3.0)]. No significant differences were found in age, gender, ASA- classification and relevant risk factors like diabetes or smoking. Most patients had fallen from a height (70 vs. 60%) or from the stairs (27 vs. 26%). Eleven percent of patients in the No-3D-group had an ISS > 16, compared to 7% in the 3D group (RD -4.7%, 95% CI -12.0 to 2.5). In the 3D-group, the duration of surgery was significantly longer with a median time of 2:08 h (range 1:06–8:44) compared to 1:54 h (range 0:52–6:45) ($p = 0.002$) in the no-3D-group.

Table 1: Patient, fracture and operation characteristics

Characteristic	No-3D n (%)	3D n (%)	Mean diff [95% CI]	Risk difference % [95% CI]	Risk ratio [95% CI]	P-value
Gender male	73 (59)	72 (67)		8.4 [-4.0 to 20.8]	1.1 [0.9 to 1.4]	
Age (mean)	43 (41–45)	45 (42–47)	1.87 [-4.4-3.0]			0.723
Body Mass Index (BMI)				-1.3 [-4.1 to 1.5]	1.0 [0.8 to 1.3]	
< 18,5	7 (6)	2 (2)		-4.1 [-9.3 to 1.1]	0.3 [0.1 to 1.5]	
18,5 – 25	64 (56)	55 (56)		-0.6 [-14.0 to 12.8]	1.0 [0.8 to 1.3]	
25-30	28 (25)	35 (35)		10.8 [-1.5 to 23.1]	1.4 [0.9 to 2.2]	
30-35	13 (11)	4 (4)		-7.4 [-14.4 to -0.3]	0.4 [0.1 to 1.1]	
> 35	2 (2)	3 (3)		1.3 [-2.9 to 5.4]	1.7 [0.3 to 10.1]	
ASA				-1.5 [-5.3 to 2.4]	1.0 [0.8 to 1.1]	
1	86 (69)	69 (65)		-4.9 [-17.0 to 7.3]	0.9 [0.8 to 1.1]	
2	33 (27)	36 (34)		7.0 [-4.8 to 18.9]	1.3 [0.9 to 1.9]	
3	5 (4)	2 (2)		-2.2 [-6.5 to 2.1]	0.5 [0.1 to 2.3]	
Diabetes Mellitus	7 (6)	6 (6)		-0.0 [-6.0 to 5.9]	1.0 [0.3 to 2.9]	
Smoking	65 (54)	48 (47)		-7.1 [-20.2 to 6.0]	0.9 [0.7 to 1.1]	
Trauma mechanism				0.9 [-1.0 to 2.8]	1.0 [0.8 to 1.2]	
Fall from height	87 (70)	64 (60)		-9.8 [-22.1 to 2.5]	0.9 [0.7 to 1.0]	
Fall from stairs	17 (14)	27 (26)		11.8 [1.5 to 22.0]	1.9 [1.1 to 3.2]	
Car accident	8 (7)	2 (2)		-4.6 [-9.6 to 0.5]	0.3 [0.1 to 1.3]	
Motor accident	0 (0)	2 (2)		1.9 [-0.7 to 4.5]	-	
Direct trauma	2 (2)	5 (5)		3.1 [-1.5 to 7.7]	2.9 [0.6 to 14.8]	
Other	10 (8)	6 (6)		-2.4 [-8.9 to 4.1]	0.7 [0.3 to 1.9]	
ISS ≥ 16	14 (11)	7 (7)		-4.7 [-12.0 to 2.5]	0.6 [0.2 to 1.4]	
Left-side fracture	62 (50)	42 (39)		-10.8 [-23.5 to 2.0]	0.8 [0.6 to 1.1]	
Open fracture	2 (2)	3 (3)		1.2 [-2.7 to 5.0]	1.7 [0.3 to 10.6]	
Bilateral fracture	23 (19)	15 (14)		-4.5 [-14.0 to 5.0]	0.8 [0.4 to 1.4]	
Fracture ipsilateral foot or ankle	13 (11)	13 (12)		1.7 [-6.5 to 9.8]	1.2 [0.6 to 2.4]	
Sanders fracture type				0.7 [-2.7 to 4.1]	1.0 [0.8 to 1.2]	
1	9 (8)	9 (9)		0.8 [-6.9 to 8.5]	1.1 [0.5 to 2.6]	
2	73 (68)	67 (68)		0.1 [-12.7 to 12.8]	1.0 [0.8 to 1.2]	
3	24 (22)	20 (20)		-2.0 [-13.2 to 9.1]	0.9 [0.5 to 1.5]	
4	2 (2)	3 (3)		1.2 [-3.0 to 5.4]	1.6 [0.3 to 9.6]	
Days to surgery, median (range)	13.0 (1-24)	15.0 (2-60)				0.060
Duration of surgery, median (range)	1:54 (0:52-6:45)	2:08 (1:06-8:44)				0.002

CI: Confidence interval

Peri-operative imaging and intra-operative corrections

Almost every patient underwent a pre-operative CT scan (100 vs. 98%) (Table 2). In the 3D-group, a pre-operative MRI scan was obtained in one patient. An Anterior–Posterior (AP) and a lateral view were also obtained in almost all patients (99 vs. 97%), in contrast axial views, were obtained in only 53 vs. 52% of the patients. Brodén's views were

performed more often in the No-3D-group (34%) than in the 3D-group (20%) (RD 13.9%, 95% CI -25.9 to -1.8).

Intra-operative 2D-imaging was used during all operations. One or more corrections after intra-operative imaging were performed in 53% of the operations in the No-3D-group versus 69% in the 3D-group. Significantly fewer corrections were made after 2D-imaging in the 3D-group (38%) compared to the No-3D-group (53%); RD -15.4%, 95% CI -28.6 to -2. In both groups, usually only one correction was performed, with slightly more corrections in implant position (53 vs. 57%) than reduction (43 vs. 47%).

Table 2: Peri-operative imaging and intra-operative corrections

	No-3D n (%)	3D n (%)	Risk difference % [95% CI]	Risk ratio [95% CI]
Preoperative imaging			0.6 [-0.9 to 2.1]	1.0 [0.8 to 1.2]
X-ray	1 (1)	1 (1)	0.1 [-2.4 to 2.6]	1.1 [0.1 to 17.8]
CT-scan	45 (39)	47 (45)	6.7 [-6.2 to 19.7]	1.2 [0.9 to 1.6]
X-ray & CT-scan	71 (61)	55 (53)	-7.8 [-20.9 to 5.3]	0.9 [0.7 to 1.1]
Other	0 (0)	1 (1)	1.0 [-0.9 to 2.8]	-
Type of preoperative X-ray				
AP & lateral	92 (99)	85 (97)	-2.3 [-6.7 to 2.0]	1.0 [0.9 to 1.0]
Axial	55 (53)	50 (52)	-0.8 [-14.7 to 13.0]	1.0 [0.8 to 1.3]
Broden	35 (34)	19 (20)	-13.9 [-25.9 to -1.8]	0.6 [0.4 to 1.0]
Overall corrections performed	61 (53)	70 (69)	16.3 [3.5 to 29.1]	1.3 [1.1 to 1.6]
Corrections performed after 2D-imaging	61 (53)	38 (38)	-15.4 [-28.6 to -2.3]	0.7 [0.5 to 1.0]
Number of corrections after 2D-imaging			-3.4 [-6.6 to -0.3]	1.0 [0.8 to 1.2]
0	54 (47)	63 (62)	15.4 [2.3 to 28.55]	1.3 [1.0 to 1.7]
1	39 (34)	29 (29)	-5.2 [-17.6 to 7.2]	0.8 [0.6 to 1.3]
2	17 (15)	9 (9)	-5.9 [-14.4 to 2.7]	0.6 [0.3 to 1.3]
3	5 (4)	0 (0)	-4.3 [-8.1 to -0.6]	-
Type of correction after 2D-imaging			-3.5 [-21.0 to 14.0]	0.9 [0.7 to 1.3]
Reduction	39 (43)	22 (47)		
Implant position	51 (57)	25 (53)		
Year 3D-imaging performed			54.0 [43.6-64.5]	5.0 [2.9-8.7]
Before 2007	78 (87)	12 (13)		
After 2007	46 (33)	95 (67)		
Number of 3D-scans	-	90 (84)		
1				
2	-	16 (15)		
3	-	1 (1)		

Table 2: Continued

	No-3D n (%)	3D n (%)	Risk difference % [95% CI]	Risk ratio [95% CI]
Number of corrections after 3D-imaging				
0	-	48 (47)		
1	-	36 (35)		
2	-	13 (13)		
3	-	4 (4)		
4	-	0 (0)		
5	-	1 (1)		
Timing 3D-scan				
Before reduction & hardware implantation	-	0 (0)		
After reduction	-	12 (10)		
After reduction & hardware implantation	-	113 (90)		
Type of correction after 3D-imaging				
Reduction	-	2 (4)		
Implant position	-	51 (96)		
Postoperative imaging				
X-ray	118 (98)	102 (95)	-2.2 [-7.1 to 2.7]	1.0 [0.9 to 1.0]
CT-scan	0 (0)	0 (0)	-	-
X-ray & CT-scan	3 (3)	5 (5)	2.2 [-2.7 to 7.0]	1.9 [0.5 to 7.7]
Other	0 (0)	0 (0)	-	-
Type of postoperative X-ray				
AP & lateral	118 (100)	107 (100)	-	-
Axial	89 (75)	86 (80)	5.0 [-5.9 to 15.8]	1.1 [0.9 to 1.2]
Brodén	37 (31)	37 (35)	3.2 [-9.1 to 15.5]	1.1 [0.8 to 1.6]

CI: Confidence interval

In 107 procedures, additional 3D-imaging was performed; most often once (84%), but sometimes two or three times during the surgical procedure. Most procedures with 3D-imaging were performed from the beginning of the year 2007. After 2007, a 3D scan was performed in 67% of the surgical procedures. Ninety percent of the scans were obtained after reduction and fixation, while the remaining 10% was performed after fracture reduction but before definitive hardware implantation. When 3D-imaging was available, in more than half (53%) of the operations an additional correction was performed following 3D-imaging. In contrast to corrections following 2D-imaging, 96.2% of the corrections were corrections of implant (plate and/or screw) position.

All patients underwent postoperative X-ray imaging and, in 3% and 5% respectively, a postoperative CT scan was performed. In contrast with preoperative imaging, in both groups Brodén's views were taken in approximately one- third of the patients. AP and lateral views were obtained in all patients and axial views in 75–80% of them.

Outcomes

No significant differences were found in patient outcomes between the two groups (Table 3). Revision surgery was deemed necessary in 2% versus 3% of patients following ORIF. Wound infections occurred in 25% versus 33% of patients of which the majority was superficial. Implants were removed in less than half of the patients, mainly due to painful symptoms. Secondary arthrodesis was performed in 7% of patients in the No-3D-group and 11% in the 3D-group, mainly due to a painful joint.

Table 3: Patient-relevant outcomes

	No-3D n (%)	3D n (%)	Risk Difference % [95% CI]	Risk ratio [95% CI]
Revision surgery	2 (2)	3 (3)	1.2 [-2.6 to 5.0]	1.7 [0.3 to 10.2]
Wound infection	31 (25)	35 (33)	7.5 [-4.2 to 19.3]	1.3 [0.9 to 2.0]
Type of wound infection			2.9 [-3.1 to 8.9]	1.0 [0.7 to 1.5]
Superficial without antibiotics	7 (23)	7 (20)	-2.6 [-22.4 to 17.2]	0.9 [0.3 to 2.2]
Superficial with antibiotics	13 (42)	15 (43)	0.9 [-23.0 to 24.8]	1.0 [0.6 to 1.8]
Deep with debridement	6 (19)	6 (17)	-2.2 [-20.9 to 16.5]	0.9 [0.3 to 2.5]
Deep with hardware removal	5 (16)	5 (14)	-1.8 [-19.2 to 15.5]	0.9 [0.3 to 2.8]
Osteomyelitis	0 (0)	2 (6)	5.7 [-2.0 to 13.4]	-
Implant removal	58 (47)	45 (42)	-4.7 [-17.6 to 8.1]	0.9 [0.7 to 1.2]
Reason for implant removal			-0.3 [-5.6 to 5.0]	1.0 [0.8 to 1.3]
Pain	43 (75)	31 (69)	-6.6 [-24.1 to 11.0]	0.9 [0.7 to 1.2]
Material related	3 (5)	6 (13)	8.1 [-3.4 to 19.6]	2.5 [0.7 to 9.6]
Infection	8 (14)	7 (16)	1.5 [-12.4 to 15.4]	1.1 [0.4 to 2.8]
Planned removal	3 (5)	1 (2)	-3.0 [-10.3 to 4.2]	0.4 [0.0 to 3.9]
Arthrodesis	8 (7)	11 (11)	4.0 [-3.2 to 11.3]	1.6 [0.7 to 3.9]
Reason for arthrodesis				
Pain	6 (75)	7 (78)	2.8 [-37.7 to 43.3]	1.0 [0.6 to 1.8]
Persisting infection	2 (25)	2 (22)	-2.8 [-43.3 to 37.7]	0.9 [0.2 to 4.9]

CI: Confidence interval

Discussion

In this study, we found that when 3D-imaging is available at the surgeon's preference additional corrections were performed in 53% of the patients, which were not performed after 2D-imaging. In addition, when the surgeon has 3D-imaging at his disposal the number of corrections performed after 2D-imaging decreases with 15%. These additional corrections are probably conducted because the increased information 3D-imaging gives about fracture reduction and implant position. However, the reduction in corrections performed after 2D-imaging also suggests that the surgeons' attitude towards 2D-imaging changes unwittingly when 3D-imaging is also available: they tend to rely more on 3D-imaging and postpone their decision to correct until 3D-imaging has been performed.

Additionally, following 3D-imaging most of the corrections were performed because of a suboptimal implant position, while after 2D-imaging corrections of both reduction and implant position were performed. A reason for this difference could be that reduction can be evaluated adequately with 2D-imaging, while implant position is more difficult to evaluate based on these images. Another explanation could be the timing of 3D-imaging, which is most often at the end of the procedure. The threshold to optimize reduction at this stage of the procedure could be higher, because mostly different implants need to be removed. The threshold to revise one or more screws because of length or position is lower and could therefore be done more frequently. The number of corrections in our study is slightly higher than the approximately 40% correction rate found in previous studies.^{12,20} However, the higher correction rate of implant position as found in the present study was also shown by others.^{15,20}

No differences were found in the patient-relevant outcomes or peri-operative imaging, except for the presence of pre-operative Brodén's views. This difference might be due to the nationwide trend towards centralization for complex fracture care, in which our hospital became a referral center for calcaneal fractures. In the referring hospitals, less Brodén's views could have been performed.

As described in the literature, 3D-imaging shows a better sensitivity for the evaluation of both reduction and implant position (ranging from 76–100%) than 2D-imaging (63–95%) and its results are similar to computer tomography.^{21–23} There is not yet literature known describing the diagnostic accuracy specific for the BV Pulsera. However, in our study no reduction in number and type of pre-, intra- and postoperative radiological exams was found when 3D-imaging was available. Various authors have suggested that corrections performed after intra-operative 3D-imaging can reduce the number of revision surgery.^{7,8,10,12,20,24} However, we found no difference in the need for revision surgery. An explanation for this could be overestimation of the number of additional corrections after 3D-imaging, because of a more critical attitude of the surgeon towards 2D-imaging when 3D-imaging is not available. Another explanation may be that the disadvantages of a reoperation outweigh the expected advantages of correcting a suboptimal reduction and/or implant position: the threshold for a reoperation is high. No differences were found in the percentage of patients requiring implant removal or secondary arthrodesis, indicating that these are legitimate considerations.

This was a before–after study comparing the effect of additional 3D-imaging groups on peri-operative imaging and patient outcome. After the clinical introduction of 3D-fluoroscopic imaging in 2007, the application of 3D-imaging was at the surgeons' discretion, which was done in 67% of the operations. Although reasons for not using 3D-imaging could not be retrieved retrospectively, unavailability of the 3D-C-arm due to maintenance or repair was likely to be the main reason. However, selection bias cannot be excluded. Additionally, the software enhanced with Titanview during the study period, which could have improved the diagnostic accuracy.

In addition, the retrospective character of this study could have led to underestimation of the number and type of corrections performed, especially after 2D-imaging. In contrast

to 2D-imaging, the surgeon has to make preparations for 3D-imaging in order to preserve sterility in the operation area and is, therefore, more conscious of the corrections made and more likely to report these corrections in the operation chart than when he uses 2D imaging more continuously during the procedure. However, we expect that this underestimation is similar in both groups, because the use of 2D-imaging is the same.

Our findings suggest no differences in patient outcome in terms of wound complications, revision surgery, or hardware removal. In addition, Gwak et al. did not find differences in the AOFAS hindfoot score or Visual Analog Scale.¹³ Unfortunately, no patient-reported outcome measures were taken into account in our study.

Follow-up of a multicenter randomized trial is ongoing. This trial answers the question whether the use of additional 3D-imaging improves the quality of reduction and fixation and patient outcomes.¹⁷ In this study, the availability of intra-operative 3D-imaging is determined by randomization, not until the surgeon is satisfied about the reduction and fixation based on fluoroscopic 2D-imaging and is ready to end the operation. Radiologic outcome is determined as well as functional outcome by patient-rated outcome measures. The results of this trial are expected in the summer of 2017.

Conclusions

The intra-operative availability of 3D-imaging during fracture surgery of the calcaneus leads to additional corrections in 53%. Moreover, 3D-imaging changed the surgeons' attitude to rely more on 3D-imaging, hence a 15%-decrease of corrections performed after 2D-imaging when 3D imaging was available.

In addition, in our study no differences in peri-operative imaging and patient-relevant outcomes are found. Therefore, previous conclusions that corrections performed after intra-operative 3D-imaging are always additional corrections and may reduce revision surgery and costs require better underpinning.

References

1. Schepers T., Ginai A.Z., Mulder P.G.H., et al. Radiographic evaluation of calcaneal fractures: To measure or not to measure. *Skeletal Radiology* 2007; 36: 847-52.
2. David V., Stephens T.J., Kindl R., et al. Calcaneotalar Ratio: A New Concept in the Estimation of the Length of the Calcaneus. *The Journal of Foot and Ankle Surgery* 2015; 54: 370-2.
3. Swords M.P., Alton T.B., Holt S., et al. Prognostic value of computed tomography classification systems for intra-articular calcaneus fractures. *Foot & Ankle International* 2014; 35: 975-80.
4. Kurozumi T., Jinno Y., Sato T., et al. Open reduction for intra-articular calcaneal fractures: evaluation using computed tomography. *Foot & Ankle International* 2003; 24: 942-8.
5. Gupta A., Ghalambor N., Nihal A., et al. The modified Palmer lateral approach for calcaneal fractures: Wound healing and postoperative computed tomographic evaluation of fracture reduction. *Foot & Ankle International* 2003; 24: 744-53.
6. Gitajn I.L., Toussaint R.J., Kwon J.Y. Assessing accuracy of sustentaculum screw placement during calcaneal fixation. *Foot & Ankle International* 2013; 34: 282-6.
7. Atesok K., Finkelstein J., Khoury A., et al. The use of intraoperative three-dimensional imaging (ISO-C-3D) in fixation of intraarticular fractures. *Injury* 2007; 38: 1163-9.
8. Bischoff M., Hebecker A., Hartwig E., et al. Cost effectiveness of intraoperative three-dimensional imaging with a mobile surgical C-arm. *Unfallchirurg* 2004; 107: 712-5.
9. Carelsen B., Haverlag R., Ubbink D.T., et al. Does intraoperative fluoroscopic 3D imaging provide extra information for fracture surgery? *Archives of Orthopaedic Trauma Surgery* 2008; 128: 1419-24.
10. Eckardt H., Lind M. Effect of Intraoperative Three-Dimensional Imaging During the Reduction and Fixation of Displaced Calcaneal Fractures on Articular Congruence and Implant Fixation. *Foot & Ankle International* 2015; 36: 764-73.
11. Franke J., von Recum J., Wendl K., et al. & Intraoperative 3-dimensional imaging - beneficial or necessary? *Unfallchirurg* 2013; 116: 185-90.
12. Geerling J., Kendoff D., Citak M., et al. Intraoperative 3D imaging in calcaneal fracture care-clinical implications and decision making. *The Journal of Trauma* 2009; 66: 768-73.
13. Gwak H.C., Kim J.G., Kim J.H., et al. Intraoperative Three-Dimensional Imaging in Calcaneal Fracture Treatment. *Clinics in Orthopedic Surgery* 2015; 7: 483-9.
14. Richter M., Geerling J., Zech S., et al. Intraoperative Three-Dimensional Imaging With a Motorized Mobile C-Arm (SIREMOBIL ISO-C-3D) in Foot and Ankle Trauma Care A Preliminary Report. *Journal of Orthopaedic Trauma* 2005; 19: 259-66.
15. Rübberdt A., Feil R., Stengel D., et al. The clinical use of the ISO-C(3D) imaging system in calcaneus fracture surgery. *Unfallchirurg* 2006; 109: 112-8.
16. Kienast B., Gille J., Queitsch C., et al. Early weight bearing of calcaneal fractures treated by intraoperative 3D-fluoroscopy and locked-screw plate fixation. *The Open Orthopaedics Journal* 2009; 3: 69-74.

17. Beerekamp M.S.H., Ubbink D.T., Maas M., et al. Fracture surgery of the extremities with the intra-operative use of 3D-RX: a randomized multicenter trial (EF3X-trial). *BMC Musculoskeletal Disorders* 2011; 12: 151.
18. Sanders R., Vaupel Z., Erdogan M., et al. The Operative Treatment of Displaced Intra-articular Calcaneal Fractures (DIACFs): Long Term (10-20 years) results in 108 fractures using a prognostic CT Classification. *Journal of Orthopaedic Trauma* 2014; 28: 551-63.
19. Dean A.G., Sullivan K.M. OpenEpi: Open Source Epidemiologic Statistics for Public Health, Version 3.01, updated 2013/04/06. Available at: <https://www.openepi.com> (Accessed 26th of October 2016).
20. Franke J., Wendl K., Suda A.J., et al. Intraoperative three-dimensional imaging in the treatment of calcaneal fractures. *The Journal of Bone and Joint Surgery (American Volume)* 2014; 96: e72
21. Kendoff D., Citak M., Gardner M., et al. Three-dimensional fluoroscopy for evaluation of articular reduction and screw placement in calcaneal fractures. *Foot & Ankle International* 2007; 28: 1165–71.
22. Kotsianos D., Wirth S., Fischer T., et al. 3D imaging with an isocentric mobile C-arm comparison of image quality with spiral CT. *European Radiology* 2004; 14: 1590–5.
23. Rock C., Linsenmaier U., Brandl R., et al. Introduction of a new mobile C-arm/CT combination equipment (ISO-C-3D). Initial results of 3-D sectional imaging. *Unfallchirurg* 2001; 104: 827–33.
24. Kendoff D., Citak M., Gardner M.J., et al. Intraoperative 3D imaging: Value and consequences in 248 cases. *The Journal of Trauma* 2009; 66: 232–8.



Chapter 7

Fracture Surgery of the extremities with the intra-operative use of 3D-RX: A randomized multicentre trial (EF3X-trial)

M.S.H. Beerekamp, D.T. Ubbink, M. Maas, J.S.K. Luitse, P. Kloen,
T.J. Blokhuis, M.J. Segers, M. Marmor, N.W.L. Schep, M.G. Dijkgraaf,
J.C. Goslings on behalf of the EF3X study group

The EF3X study group: R.W. Peters, V.M. de Jong, L. Leenen,
J. Winkelhagen, B. Twigt

BMC Musculoskeletal Disorders. 2011; 12: 151

Abstract

Background

Posttraumatic osteoarthritis can develop after an intra-articular extremity fracture, leading to pain and loss of function. According to international guidelines, anatomical reduction and fixation are the basis for an optimal functional result. In order to achieve this during fracture surgery, an optimal view on the position of the bone fragments and fixation material is a necessity. The currently used 2D-fluoroscopy does not provide sufficient insight, in particular in cases with complex anatomy or subtle injury, and even an 18-26% suboptimal fracture reduction is reported for the ankle and foot. More intra-operative information is therefore needed. Recently the 3D-RX-system was developed, which provides conventional 2D-fluoroscopic images as well as a 3D-reconstruction of bony structures. This modality provides more information, which consequently leads to extra corrections in 18-30% of the fracture operations. However, the effect of the extra corrections on the quality of the anatomical fracture reduction and fixation as well as on patient relevant outcomes has never been investigated. The objective of this study protocol is to investigate the effectiveness of the intra-operative use of the 3D-RX-system as compared to the conventional 2D-fluoroscopy in patients with traumatic intra-articular fractures of the wrist, ankle and calcaneus. The effectiveness will be assessed in two different areas: 1) the quality of fracture reduction and fixation, based on the current golden standard, Computed Tomography. 2) The patient-relevant outcomes like functional outcome range of motion and pain. In addition, the diagnostic accuracy of the 3D-RX-scan will be determined in a clinical setting and a cost-effectiveness as well as a cost-utility analysis will be performed.

Methods/design

In this protocol for an international multicenter randomized clinical trial, adult patients (age > 17 years) with a traumatic intra-articular fracture of the wrist, ankle or calcaneus eligible for surgery will be subjected to additional intra-operative 3D-RX. In half of the patients the surgeon will be blinded to these results, in the other half the surgeon may use the 3D-RX results to further optimize fracture reduction. In both randomization groups, a CT-scan will be performed postoperatively. Based on these CT-scans the quality of fracture reduction and fixation will be determined. During the follow-up visits after hospital discharge at 6, 12 weeks, and 1 year postoperatively, the patient relevant outcomes will be determined by joint specific, health economic and quality of life questionnaires. In addition, a follow up study will be performed to determine the patient relevant outcomes and prevalence of posttraumatic osteoarthritis at 2 and 5 years postoperatively.

Discussion

The results of the study will provide more information on the effectiveness of the intra-operative use of 3D-imaging during surgical treatment of intra-articular fractures of the wrist, ankle and calcaneus. A randomized design in which patients will be allocated to a treatment arm during surgery will be used because of its high methodological quality and the ability to detect incongruences in the reduction and/or fixation that occur intraoperatively in the blinded arm of the 3D-RX. An alternative, pragmatic design could be to randomize before the start of the surgery, then two surgical strategies would be compared. This resembles clinical practice better but introduces more bias and does not allow the assessment of incongruences that would have been detected by 3DRX in the blinded arm.

Introduction

Fractures of the extremities are common injuries, with an incidence of 38 wrist fractures per 10,000 inhabitants per year,¹ and an estimate of 25,000 - 68,000 ankle fractures per year in the Netherlands.² Posttraumatic osteoarthritis can develop after an intra-articular extremity fracture, which can lead to pain and loss of function. According to international guidelines, anatomical reduction and fixation are the basis for an optimal functional result.³ This can be achieved by closed reduction and cast fixation. If a conservative treatment leads to a suboptimal reduction and fixation, surgical treatment is indicated. During open reduction and internal fixation (ORIF), conventional 2D-fluoroscopy is used to gain more insight in the fracture fragments and fixation material next to a direct view. When it involves complex anatomy or subtle injury 2D-fluoroscopy often underestimates the extent of the injury or the degree of displacement of fracture fragments, which can be misleading to the surgeon. Consequently, postoperative X-ray images and CT-scans frequently show incorrect positioned screws or incongruences, like gaps and step-offs, in the joint surface, while these were not recognized on the intra-operative 2D-fluoroscopic images. E.g. for the ankle and foot even an 18-26% suboptimal fracture reduction is reported.⁴⁻⁶ More intra-operative information is therefore needed in order to minimize suboptimal fracture reduction.

Recently a 3-Dimensional Rotational X-ray system (3D-RX-system) was developed which can provide more detailed imaging intra-operatively. This system consists of a mobile C-arm unit modified to provide a motorized rotational movement and is combined with a workstation. Next to conventional 2D-fluoroscopy this system can provide multiplanar 3-dimensional reconstruction of the osseous structures.

Several cadaveric studies have been performed on different joints of the upper and lower limb to evaluate the image quality of intra-operative 3D-imaging.⁷⁻¹² In these studies 3D-imaging had a better diagnostic value than conventional radiography and 2D-fluoroscopic images. Although the subjective imaging quality was higher in CT-scanning, images of the intra-operative 3D-imaging were comparable in diagnostic value. In addition, in some clinical studies concerning intraoperative 3D-imaging, this modality has shown to provide extra information. Extra corrections after 3D-imaging were performed in 11-30% of the fracture operations.^{11,13-17} These corrections concerned suboptimal fracture reduction, like intra-articular steps-offs and fracture gaps, and incorrectly positioned fixation material. The studies mentioned above have shown that intraoperative 3D-imaging provides additional information and allows the surgeon to recognize problems with fracture reduction and/or fixation during the operation. However, these studies used indirect measurements to establish the added value of intra-operative 3D-imaging. The direct effects on the quality of fracture reduction and fixation and patient relevant outcomes have not yet been investigated.

The aim of this protocol for a randomized clinical trial is to investigate the effectiveness of the intra-operative use of the 3D-RX-system as compared to the use of conventional 2D-fluoroscopy alone in patients with traumatic intra-articular fractures of the wrist, ankle and calcaneus. This effectiveness will be assessed in two different areas: 1) the quality

of fracture reduction and fixation, based on the current golden standard, Computed Tomography. 2) The patient-relevant outcomes like functional outcome, range of motion and pain. In addition, the diagnostic accuracy of the 3D-RX-scan will be determined in a clinical setting and a cost-effectiveness as well as a cost-utility analysis will be performed.

Choice for the study design

With this study, we aim to address multiple issues regarding the intra-operative use of 3D-imaging in fractures of the extremities; the diagnostic value (sensitivity and specificity) of the 3D-RX-scan in a clinical setting, the therapeutically outcome and its effect on the quality of fracture reduction and fixation and the patient relevant outcomes. For this purpose, we prefer a blinded randomized design, offering the most robust way to investigate the effect of the intra-operative use of 3D-imaging.

In order to compare both techniques, patients will be randomized during surgery after the definitive adjustments based on 2D-fluoroscopy and before 3D-fluoroscopy. This avoids the phenomenon that the surgeon neglects the 2D-fluoroscopy and relies on the envisioned 3D-images for the reduction and fixation later during the surgical procedure. An additional advantage of this design is that both the diagnostic value as well as the effects on the quality of fracture reduction and fixation can be investigated.

A disadvantage of our study design is that half of the patients receive radiation of the 3D-scan, while they cannot benefit from this 3D-scan. Because of the relatively low radiation dose of the 3D-scan, this disadvantage is considered acceptable. An alternative, more pragmatic, study design would randomize between two operative strategies: with or without intra-operative 3D-imaging. In this design, no patient would receive unbeneficial radiation doses and this set-up will probably be a better reflection of the clinical practice. However, comparing two surgical strategies does not allow the assessment of any missed incongruences when using 2D-fluoroscopy alone. In addition, when the surgeon knows he can employ the 3D-imaging strategy, he might change his attitude towards 2D-fluoroscopy and be less accurate. Hence, more bias will be introduced because of the surgeon's attitude towards 3D-imaging. In addition, 3D-imaging may also detect incongruences that are corrected but may not have any influence on functional outcomes or long-term development of posttraumatic osteoarthritis. This possible over diagnosing with 3D-imaging cannot be detected with a pragmatic design.

The choice for our study design induced some practical drawbacks, i.e. the blinding of the 3D-scan for the surgeon needs some discipline, as the only way to blind the 3D-scan is to turn the screens from the surgeon. In addition, this design warrants more administration during surgery because the surgeon evaluates the radiological results after every imaging modality. Because of the use of a secured Internet module, this administration is relatively simple.

Methods/design

Objectives

The objectives of this randomized clinical trial are to:

1. Assess the quality of fracture reduction and fixation based on the postoperative CT-scans of the wrist, ankle or calcaneus, determined by a standard scoring protocol
2. Assess the patient relevant outcomes
3. Assess the diagnostic value of an intra-operative 3D-RX-scan in a clinical setting
4. Perform a cost-effectiveness analysis to assess whether the use of 2D-fluoroscopy and the 3D-RX-scan eventually results in cost savings or is compensated for by increased health benefits in comparison with the use of 2D-fluoroscopy only

Study population

The study population consists of adult patients with a traumatic intra-articular fracture of the wrist, ankle or calcaneus in which operative treatment is indicated.

Inclusion criteria are:

- Adult patients (age > 17 years)
- Distal radius fracture, AO-classification A2-C3, or
- Distal tibial fracture, AO-classification B1-C3, or
- Malleolar fractures, AO-classification A1-C3, or
- Calcaneal fractures, Sanders classification I-IV
- Fracture surgery (ORIF or CRIF) required (i.e. intra-articular fractures with dislocation).

Only intra-articular fractures will be included in this trial because the additional value of intra-operative 3D-imaging is to be expected in these types of fractures. The complexity of these fractures warrants more insight in the fracture fragments and fixation material than in extra-articular fractures. It is debatable whether the distal radius fractures AO-classification A2-3 and malleolar fractures C1-3 are true intra-articular fractures. Since we are interested in the congruence of the distal radioulnar joint (DRUJ) and the tibiofibular syndesmosis, these fracture types will be included. Especially in these fracture types, 3D-imaging can give more insight in rotation or subluxation of the ulna or fibula in these articulations.

Exclusion criteria are:

- Pathological fractures, i.e. due to underlying malignant disorder
- Rheumatoid osteoarthritis
- No written informed consent
- Inability to understand trial features due to mental handicap or language problems
- Pregnancy

Study design

The EF3X-trial is an international randomized multicenter trial, with participation of 4 hospitals (3 university hospitals and 1 regional hospital). Patients eligible for operative treatment of their intra-articular fracture of the wrist, ankle or calcaneus will be randomized after the surgeon is satisfied with the reduction and fixation after 2D-imaging. Patients will be blinded for the availability of the 3D-scan. When operative treatment is indicated

in patients presenting to the Emergency Department (ED) with an intra-articular fracture of the wrist, ankle or calcaneus, they will be counseled and asked for informed consent if the in- and exclusion criteria are met.

During surgery, initially only 2D-fluoroscopy is used for the intra-operative imaging as part of the usual intra-operative diagnostic procedure (Figure 1). The surgeon will then operate until (s)he is satisfied with fracture reduction and fixation. Then the surgeon will be asked to evaluate the conclusive 2D-images according to the scoring protocol for anatomical reduction and fixation, which is developed in the AMC. After this evaluation, a 3D-RX-scan will be performed, and randomization will take place.

The randomization will determine whether the information of the 3D-scan will be made available to the surgeon. Randomization is performed by an Internet randomization module prepared by the AMC Clinical Research Unit. Block randomization is used, and randomization will be stratified for the fractured joint (wrist, ankle or calcaneus) and participating center. Since it is not possible to blind the surgeon, randomization takes place after the surgeon has finished operating based on the information of 2D-fluoroscopy and is ready to close the wound. In this way (s)he cannot anticipate on the likeliness (s)he gets extra information of the 3D-scan.

Patients will not be informed about whether or not the 3D-scan was made available to the surgeon. If the 3D-scan results will not be made available, the surgeon terminates the procedure. If the information of the 3D-scan is available to the surgeon, he can act on the findings and, if necessary, surgical corrections can be made. If the surgeon is now satisfied with the operation result conclusive 2D-fluoroscopic images and a conclusive 3D-scan must be performed. The conclusive 3D-scan needs to be evaluated according to the scoring protocol for anatomical reduction. In both randomization groups, a CT-scan will be performed postoperatively.

The follow-up visits after hospital discharge will be planned at 6 and 12 weeks and 1, 2 and 5 years postoperatively.

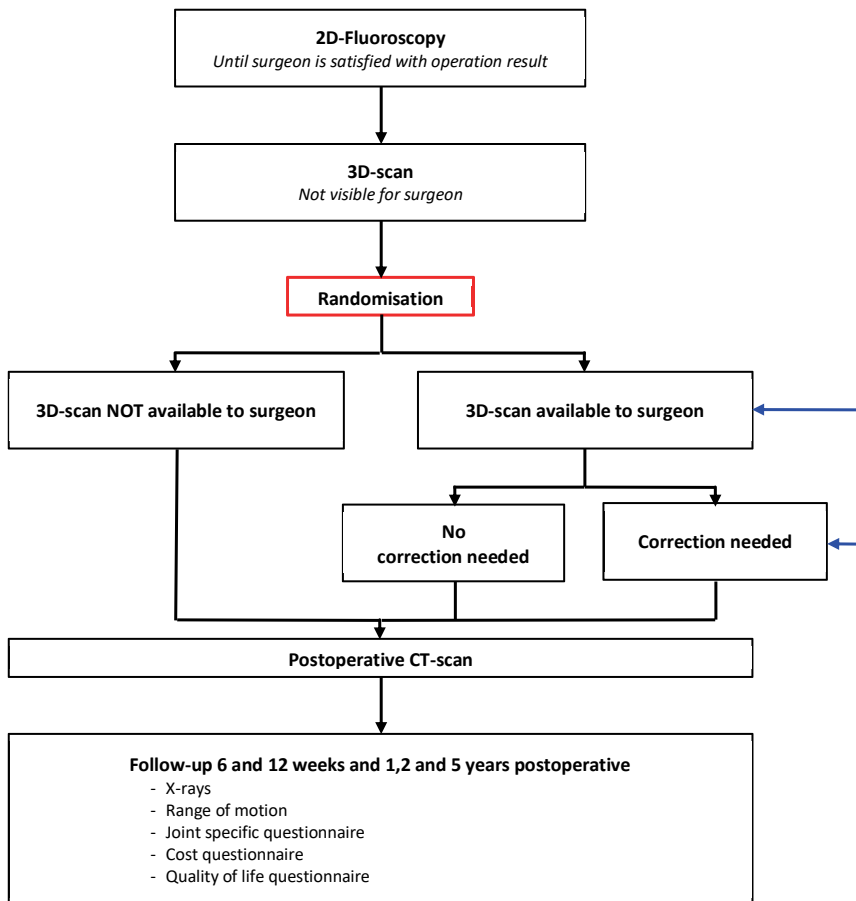


Figure 1: Flowchart of the EF3X-trial

Primary and secondary endpoints

Our primary outcomes are the quality of fracture reduction and fixation based on the postoperative CT-scans of the wrist, ankle or calcaneus. This will be determined by three independent experts. These experts will systematically evaluate the postoperative CT-scans according to a standard scoring protocol. After this evaluation, the images will be classified as optimal or suboptimal. A suboptimal reduction and/or fixation will be defined as an indication for a revision following from the systematic evaluation. In addition, this classification will be based on the radiological images alone. Patient related factors, as swelling of the soft tissue will not be taken into account in this evaluation of an (sub)optimal quality of fracture reduction and/or fixation. A standard scoring protocol for the radiological evaluation will be developed for each joint separately. Although scoring protocols for the wrist, ankle and calcaneus have been described in the literature; most of them lack clinical sensitivity, and are therefore infrequently used.¹⁸ Another reason for not using these scoring protocols is that they merely consist of assessment of distance and angle measurements that have a high interobserver variance and are infrequently used in clinical practice.¹⁹⁻²³ The scoring protocols we developed are based on a Delphi consensus



on how to evaluate the different joints. For the wrist and ankle this Delphi consensus was performed in the Netherlands.²⁴ A Delphi consensus for the calcaneus is currently being performed with international experts.

Second, the patient-relevant outcomes like functional outcome measured by joint specific questionnaires (Patient Rated Wrist Evaluation for the wrist and Foot and Ankle Outcome score and AOFAS for the ankle and calcaneus) will be determined. The patient relevant outcomes one year postoperative will be used as endpoints.

Patient relevant outcomes determined at 2 and 5 years postoperatively will be used for a follow up study for the prevalence of posttraumatic osteoarthritis. Before ending the operation, conclusive 2D-fluoroscopic images and a conclusive 3D-RX-scan are being performed. Together with the postoperative CT-scan (reference test), these radiologic images all represent the final operating result. Therefore, the diagnostic value of only the conclusive 2D-fluoroscopic images and 3D-RX-scan will be determined. This will be done for the wrist, ankle and calcaneus separately. Hereby the detection of a suboptimal result, as described above, on the 2D-fluoroscopic images and/or 3D-RX-scan will be compared to the postoperative CT-scans.

A cost-effectiveness analysis will be performed to assess the relative benefit from a societal perspective of the use of the 3D-RX-scan in addition to 2D-fluoroscopy.

Our secondary study outcomes are:

- > The number and type of corrections made after 2D-fluoroscopy
- > The number and type of corrections made after a 3D-scan
- > The number of revision operations within 30 days
- > The number and type of complications within 30 days
- > The length of the hospital stays expressed in days
- > The quality of life measured by the SF-36

Participating centers

Four centers will enroll patients. Three of these hospitals are Dutch and one University hospital in California is willing to participate. The three Dutch hospitals will consist of 1 regional teaching hospital and two University hospitals. One of the university hospitals, the Academic Medical Center has already started patient recruitment and has included 125 patients in a 15- month period. The other Dutch University hospital, the University Medical Center Utrecht, will start recruiting patients in the summer of 2011 and is also expected to recruit 8-9 patients a month in average. The University hospital in California expects to recruit 50 patients in a one-year period. In the regional teaching hospital, the Antonius Hospital in Nieuwegein, approximately 100- 150 patients with wrist, ankle or calcaneus fractures are operated upon yearly. Because this hospital has different locations, for logistic reasons it is not possible to recruit all these patients. It is expected that 75% of these patients will participate in this trial.

Study outline

Recruitment

Patients will be recruited if they are eligible for operative treatment of their intra-articular fracture of the wrist, ankle or calcaneus. This can be at the Emergency Department (ED), the outpatient clinic or the inpatient clinical wards of orthopedic or trauma surgery. After patients are counseled and informed consent is obtained, they can be included in the study.

Intra-operative 3D-scan

For this study, the BV Pulsera with 3D-RX (3-Dimensional Rotational X-ray) is used. The BV Pulsera (Philips Healthcare, Best, the Netherlands) consists of a mobile C-arm unit modified to provide a motorized rotational movement and is combined with a Philips 3D-RA workstation. A series of 225 projection images is acquired over a period of 30 seconds during a 200° rotation of the C-arm. The projection images are used to reconstruct a 3D data set. Both volume rendering and slice images are available. The images can be enhanced by coloring the metal present in the joint (Titanview).

The radiation exposure of each image in the scanning run is dynamically adjusted to provide the best combination of low dose and optimal image quality. The device is continuously available for the duration of this trial.

Radiation dose

Patients with a fractured wrist, ankle, or calcaneus will receive an expected maximum of two 3D-RX-scans, during surgery and two X-rays postoperatively. The maximum equivalent dosage of a 3D-RX-scan of the extremities is 17 μSv . Therefore, the additional dosage during the OR of two exams is in the order of 34 μSv . Together with the X-rays performed postoperatively; the radiation dose will approximate 50 μSv . The effective dose of the postoperative CT-exam (120 kV, 150 mAs) will not exceed 0,2 mSv. The total dosage for all radiographic exams performed as part of this trial will therefore be less than 0,25 mSv. A similar effective dose is included in category IIa (0,1-1 mSv) of the ICRP (report ICRP62), which is qualified as a "minor" risk.

Sample size calculation

Based on the available literature, the frequency of suboptimal fracture reduction is 18-26%. Research in our hospital showed a frequency of 17% (Weide vd A., Haverlag R., Goslings J.C. Inconsistencies in the radiographic analysis of intra-articular fractures.). Based on Kendoff et al., we anticipate that a suboptimal fracture reduction and/ or fixation will occur in 5% of the patients, when using the 3D-RX-system.²⁵ To detect this difference of 12% using a two group continuity corrected Chi-square test at an $\alpha=0.05$ and a power of $\beta=0.80$, we will need to include 122 patients per randomization group. To account for an approximately 3% dropout by technical or logistic failures of the 3D-RX-system, 250 patients have to be included for each fracture type.

Because of possibly differential results, patients will be stratified into three groups: Patients with wrist fractures will include distal radius fractures, AO-classification A1-C3



Patients with ankle fractures will include distal tibial fractures, AO-classification B1-C3 and malleolar fractures, AO-classification A1-C3

Patients with calcaneal fractures will include Sanders classification I-IV

A total of 750 patients will be included in this trial, i.e. 250 for each fracture type.

Data collection

Pre-operatively baseline data of the patient and fracture type are collected. Intra-operatively the surgeon will be asked to evaluate the operated joint according to the scoring protocol for anatomical reduction and fixation, which is developed in the AMC. If the 3D-scan is available to the surgeon (s)he will evaluate the 3D-scan intra-operatively according to the scoring protocol mentioned above.

During the follow-up visits at 6 and 12 weeks and 1, 2 and 5 years postoperatively the range of motion, functional outcome and strength of the operated joint will be recorded and compared to the contralateral joint. For wrist fractures the 'Patient rated Wrist Evaluation' (PRWE) score will be used, for ankle and calcaneus fractures the 'Foot and Ankle Outcome Score' (FAOS) will be assessed. Quality of life will be determined by the SF-36. These are validated outcome scores. In addition, a questionnaire pertaining questions on work-related items and the patients' indirect costs of production loss will be assessed.

All intra-operative images (both 2D-fluoroscopy and 3D-scans) and postoperative CT-scans will be evaluated by three independent experts in blinded fashion and random order according to a standard scoring protocol. These experts will consist of 2 trauma/orthopedic surgeons and a radiologist. Data collected by the physicians will be entered in a secured Internet module, which is specially designed for the EF3X-trial. Patients will be given the choice to receive digital or paper questionnaires. Collection of data and questionnaires will be safeguarded by the trial coordinator.

Data monitoring

Because of the size of the trial, it was considered important to ensure independent review. Therefore, a Data Monitoring Committee (DMC) is set up to ensure the safety of the study participants, provide independent review of safety, ensure the integrity of the study conduct and results and review of the formal interim analysis.

Data analysis

All analyses will be performed in accordance with the intention to treat principle. The primary outcome, the quality of fracture reduction as well as the quality of fixation will be classified as optimal or suboptimal. This dichotomous outcome will be described as a percentage in both groups. Differences between study groups will be analyzed by means of a Chi-square test. A p-value < 0.05 will be taken as the threshold for statistical significance.

The scores of the functional outcomes determined by joint specific questionnaires at 1 year postoperative will be expressed as means and standard deviations (SD) in case of a normal distribution. Non-normally distributed outcomes will be expressed as medians

and interquartile ranges. Normality of continuous data will be tested with the Shapiro-Wilk and Kolmogorov-Smirnov test and by inspecting the frequency distributions (histograms). The homogeneity of variances will be tested using the Levene's test. The functional outcomes will be assessed using the Student's T-test (parametric data) or the Mann-Whitney-U-test (non-parametric data). Differences will be considered statistically significant when P-values are < 0.05 .

The diagnostic accuracy of a suboptimal quality of fracture reduction and/or fixation will be determined for reduction and fixation for the wrist, ankle and calcaneus separately. Sensitivity, specificity, positive and negative predictive values for both 2D-fluoroscopy and the 3DRX-scan will be calculated with the corresponding 95% confidence intervals for the classification of an optimal or suboptimal result as described above. This will be determined for both 2D-fluoroscopy and the 3D-RX-scan with the postoperative CT-scan as reference standard.

The number of patients in which corrections were performed intra-operatively after 2D-fluoroscopy or the 3D-RX-scan will be described as percentages. Differences between study groups will be analyzed by means of a Chi-square test. The same analysis will be done for the number of patients with a revision operation or complication within 30 days. The length of hospital stay will be expressed, as medians and interquartile ranges, and differences between groups will be analyzed using a Mann-Whitney U test. The quality of life measured by the SF-36 will be expressed as means and standard deviations (SD) after testing for normal distribution and compared between groups using an unpaired Student t-test. For all secondary parameters, a p-value < 0.05 will be taken as the threshold for statistical significance.

Economic evaluation

The economic evaluation of intra-operative use of 3DRX against the use of 2D-fluoroscopy as its best alternative will be performed from a societal perspective as both, a cost-effective and a cost-utility analysis. As the costs of a 3D-RX-system are 1,5 times the costs of a standard C-arm and there is the risk of over diagnosing, an economic evaluation is warranted. This cost-effectiveness analysis is chosen to comply with the clinical endpoint and enables assessment of diagnostic strategies and therapeutic interventions within the field of joint trauma care. The cost-utility analysis is chosen to enable comparisons between the currently proposed optimization of health care (3D- versus 2D- imaging) on the one hand and new developments and technologies for other diseases and in other areas of medicine on the other hand. The primary outcomes will be the costs per patient with optimal fracture reduction (at 12 weeks post index operation, thus including assessments of re-interventions) and the costs per QALY respectively. The time horizon will be 12 weeks following the index operation. With this length of the follow-up period, no discounting of costs will take place.

Incremental cost-effectiveness and cost-utility ratios will be calculated for the extra costs per extra patient with optimal fracture reduction and the extra costs per QALY gained. Univariable and multivariable sensitivity analyses will be applied for unit costs of 3D-scan and country-specific health utility value sets (see below). Bias corrected and accelerated

bootstrapping will be done to account for sampling variability. All analyses will be done for each subgroup of patients (with wrist, ankle or calcaneus fracture respectively).

The costs will include the direct medical and nonmedical as well as the indirect non-medical costs of care. The direct medical costs include the costs of diagnostics, surgery, in-patient stay, and out-of-hospital care post-discharge (e.g. family practitioner, physiotherapist, rehabilitation care). Also, out-of-pocket expenses of patients will be quantified (over-the-counter medication, private help at home, etc.). The indirect non-medical costs of production loss due to work absenteeism will also be calculated. Principally, the friction cost method will be applied to quantify these production losses (in practice though, the length of the friction period at the time of analysis presumably will be longer than the planned follow-up period of patients). Volume data on health care resource use, out-of-pocket expenses and work absenteeism will be gathered with case report forms, hospital information systems, and a patient questionnaire, partially based on the Health and Labor questionnaire.²⁶ Unit costs will derive from the national guideline on costing in health care research.²⁷ Unit costs will be price-indexed to derive cost estimates for the base year 2011.

Fractures can be quite disabling in daily life. In addition to the already mentioned general (SF-36) and domain-specific (FAOS, PRWE) quality of life questionnaires, the EQ-5D will be applied as a health utility instrument for use in the cost-utility analysis. The health status scoring profiles gathered with the EQ-5D will be transformed into health utilities using available time trade-off-based valuation algorithms from the literature. Initially, the Dutch valuations will be used.²⁸ In sensitivity analysis, the internationally more frequently applied algorithm from the UK will be applied.²⁹

Early experience from the ongoing trial

During a period of 15 months, 125 patients have been included in one hospital alone. Next to recruitment of patients in the Academic Medical Center (AMC), recruitment will also start in the St. Antonius hospital in Nieuwegein and the University Medical Center Utrecht in the Netherlands. Internationally the University of California San Francisco Medical Center will participate.

Patient recruitment in the AMC has gone according to expectations and there are few patients not willing to participate. Due the acute nature of fracture surgery some patients are not able to be counseled and therefore excluded from participation. For the clinical follow up it appears that 6 weeks postoperative is too early to fill in the self-reported joint-specific questionnaires. Most patients have had 6 weeks of cast immobilization and have not performed the activities questioned or were advised not to perform some of the activities. For this reason, most patients leave some answers blank. Most of the questionnaires filled in after 12 weeks and 1 year postoperatively are filled in correctly and will be used as an endpoint for the clinical outcome.

Discussion

Intra-operative 3D-imaging in fractures of the extremities has been introduced a decade ago. Several cadaver studies have been performed to determine the diagnostic value of 3D-imaging, showing that it is comparable to CT-scanning. Clinical studies have shown that extra corrections in 11-30% are performed when using additional 3D-imaging during fracture surgery. Still the effectiveness of the corrections mentioned before on the quality of fracture reduction and fixation and patient relevant outcomes has not yet been determined. The EF3X-trial aims to provide evidence-based answers on the effectiveness of the intra-operative use of 3D-imaging intra-articular fractures of the extremities.

This trial compares the use of additional 3D-imaging in surgical treatment of intra-articular fractures of the extremities. Although it is widely accepted to strive for anatomical fracture reduction and fixation, there's still little evidence to support this. Therefore, in addition to the short-term radiological endpoint, also the long-term patient relevant outcomes will be determined in this trial.



Acknowledgements

We would like to thank the other members of the project group of the EF3X-trial:

Trauma Unit, Department of Surgery, Academic Medical Center, Amsterdam, the Netherlands

- Rolf W. Peters
- Vincent M. de Jong

Department of Surgery, University Medical Center, Utrecht, the Netherlands

- Loek Leenen
- Jasper Winkelhagen

Department of Surgery, Saint Antonius Hospital, Nieuwegein, the Netherlands

- Bas Twigt

With special thanks to the members of our Data Monitoring Committee:

- J.B. Reitsma, MD PhD, Clinical Epidemiologist, Julius Center, Utrecht
- I.B. Schipper, MD PhD, Trauma Surgeon, Leiden University Medical Center

References

1. Oskam J., Kingma J., Klasen H. J. Fracture of the distal forearm: Epidemiological developments in the period 1971-1995. *Injury* 1998; 29: 353–355.
2. van Dijk C.N. CBO-guideline for diagnosis and treatment of the acute ankle injury. National organization for quality assurance in hospitals. *Nederlands Tijdschrift voor Geneeskunde* 1999; 143: 2097–101.
3. Ruedi T.P., Buckley R.E., Moran C.G. AO Principles of fracture management. *Thieme Medical Publishers*, 01/2011.
4. Chen S.H., Wu P.H., Lee Y.S. Long-term results of pilon fractures. *Archives of Orthopaedic and Trauma Surgery* 2007; 127: 55–60.
5. Langenhuijsen J.F., Heetveld M.J., Ultee J.M., et al. Results of ankle fractures with involvement of the posterior tibial margin. *The Journal of Trauma* 2002; 53: 55–60.
6. Stulik J., Stehlik J., Rysavy M., et al. Minimally-invasive treatment of intra-articular fractures of the calcaneum. *The Journal of Bone and Joint Surgery (British Volume)* 2006; 88: 1634–41.
7. Kotsianos D., Rock C., Euler E., et al. 3-D imaging with a mobile surgical image enhancement equipment (ISO-C-3D). Initial examples of fracture diagnosis of peripheral joints in comparison with spiral CT and conventional radiography. *Unfallchirurg* 2001; 104: 834–8 (2001).
8. Kotsianos D., Rock C., Wirth S., et al. Detection of tibial condylar fractures using 3D imaging with a mobile image amplifier (Siemens ISO-C-3D): Comparison with plain films and spiral CT. *Rofo* 2002; 174: 82–7.
9. Rock C., Linsenmaier U., Brandl R., et al. Introduction of a new mobile C-arm/CT combination equipment (ISO-C-3D). Initial results of 3-D sectional imaging. *Unfallchirurg* 2001; 104: 827–33.
10. Rock C., Kotsianos D., Linsenmaier U., et al. Studies on image quality, high contrast resolution and dose for the axial skeleton and limbs with a new, dedicated CT system (ISO-C-3 D). *Rofo* 2002; 174: 170–6.
11. Euler E., Wirth S., Linsenmaier U., et al. Comparative study of the quality of C-arm based 3D imaging of the talus. *Unfallchirurg* 2001; 104: 839–46.
12. Wirth S., Euler E., Linsenmaier U., et al. C-arm-based mobile computed tomography: A comparison with established imaging on the basis of simulated treatments of talus neck fractures in a cadaveric study. *Computer Aided Surgery* 2004; 9: 27–38.
13. Hüfner T., Stübig T., Gösling T., et al. Cost-benefit analysis of intraoperative 3D imaging. *Unfallchirurg* 2007; 110: 14–21.
14. Richter M., Geerling J., Zech S., et al. Intraoperative Three-Dimensional Imaging With a Motorized Mobile C-Arm (SIREMOBIL ISO-C-3D) in Foot and Ankle Trauma Care A Preliminary Report. *Journal of Orthopaedic Trauma* 2005; 19: 259-66.
15. Wich M., Spranger N., Ekkernkamp A. Intraoperative imaging with the ISO C(3D). *Der Chirurg* 2004; 75: 982–7.

16. Beerekamp M.S.H., Ubbink D.T., Luitse J.S.K., et al. Perioperative 3D fluoroscopy of intra-articular fractures of the extremities. *Nederlands Tijdschrift voor Geneeskunde* 2011; 155: A2737.
17. Beerekamp M.S.H., Haverlag R., Luitse J.S.K., et al. Het peroperatieve gebruik van 3D-beeldvorming bij fracturen aan de extremiteiten. *Nederlands Tijdschrift voor Traumachirurgie* 2011; 1: 2–8.
18. Jaremko J.L., Lambert R.G.W., Rowe B.H., et al. Do radiographic indices of distal radius fracture reduction predict outcomes in older adults receiving conservative treatment? *Clinical Radiology* 2007; 62: 65–72.
19. Cole R.J., Bindra R.R., Evanoff B.A., et al. Radiographic evaluation of osseous displacement following intra-articular fractures of the distal radius: reliability of plain radiography versus computed tomography. *The Journal of Hand Surgery (American Volume)* 1997; 22: 792–800.
20. Grose A., Gardner M.J., Hettrick C., et al. Open reduction and internal fixation of tibial pilon fractures using a lateral approach. *Journal of Orthopaedic Trauma* 2007; 21: 530–7.
21. Kreder H.J., Hanel D.P., McKee M., et al. X-ray film measurements for healed distal radius fractures. *The Journal of Hand Surgery (American Volume)* 1996; 21, 31–9.
22. van Eerten P.V., Lindeboom R., Oosterkamp A.E., et al. An X-ray template assessment for distal radial fractures. *Archives of Orthopaedic and Trauma Surgery* 2008; 128: 217–21.
23. Grainger A.J., Duryea, J., Elliott J.M., et al. The evaluation of a new digital semi-automated system for the radiological assessment of distal radial fractures. *Skeletal Radiology* 2002; 31: 457–63.
24. Beerekamp M.S.H., Haverlag R., Ubbink D.T., et al. How to evaluate the quality of fracture reduction and fixation of the wrist and ankle in clinical practice: a Delphi consensus. *Archives of Orthopaedic Trauma Surgery* 2011; 131: 739–46.
25. Kendoff D., Citak M., Gardner M.J., et al. Intraoperative 3D imaging: Value and consequences in 248 cases. *The Journal of Trauma* 2009; 66: 232–8.
26. van Roijen L., Essink-Bot M. L., Koopmanschap M. A., et al. Labor and health status in economic evaluation of health care. The Health and Labor Questionnaire. *International Journal of Technology Assessment in Health Care* 1996; 12: 405–15.
27. Hakkaart-van Roijen L., Tan S., Bouwmans C. *Manual for Cost Research, Methods and Standard Cost Prices for Economic Evaluations in Health Care*. (College voor Zorgverzekeringen, 2010).
28. Lamers L.M., Stalmeier P.F.M., McDonnell J., et al. Measuring the quality of life in economic evaluations: The Dutch EQ-5D tariff. *Nederlands Tijdschrift voor Geneeskunde* 2005; 149: 1574–8.
29. Dolan P. Modeling valuations for EuroQol health states. *Medical Care* 1997; 35: 1095–108.



Chapter 8

Intraoperative effect of 2D vs 3D fluoroscopy on quality of reduction and patient-related outcome in calcaneal fracture surgery

J.A. Halm, M.S.H. Beerekamp, R.J.O. de Muinck Keizer, L.F.M. Beenen, M. Maas,
J.C. Goslings, T. Schepers, on behalf of the EF3X Study group*

The EF3X Study group: T.J. Blokhuis, M.M. Segers, V.M. de Jong, J.S.K. Luitse,
B. Twigt, D.T. Ubbink

Foot & Ankle International, 2020, ePub ahead of print

Abstract

Background

Three-dimensional (3D) fluoroscopy is thought to be advantageous in the operative reduction and internal fixation (ORIF) of calcaneal fractures. The goal of this multicenter randomized controlled trial was to investigate the clinical effect of additional intraoperative 3D fluoroscopy on postoperative quality of reduction and fixation and patient reported outcomes as compared to conventional 2D fluoroscopy in patients with intra-articular fractures of the calcaneus.

Methods

Patients were randomized between 3D or conventional 2D fluoroscopy during operative treatment of calcaneal fractures. Primary outcome was the difference in quality of fracture reduction and implant position on postoperative computed tomography (CT). Secondary endpoints included intraoperative corrections (prior to wound closure), complications, and revision surgery (after wound closure). Function and patient reported outcome were evaluated after surgery and included range of motion, Foot and Ankle Outcome Score (FAOS), American Orthopedic Foot and Ankle Score (AOFAS), Short-Form 36 (SF-36) questionnaires and Kellgren-Lawrence post-traumatic osteoarthritis classification.

Results

A total of 102 calcaneal fractures were included in the study in 100 patients. Fifty patients were randomized to the 3D group and 52 to the 2D group. There was a statistically significant difference in duration of surgery between the groups. After 3D fluoroscopy a total of 57 intraoperative corrections were performed in 28 subjects (56%). The postoperative CT-scan revealed an indication for additional revision of reduction or implant position in 69% of the 3D group versus 60% in the 2D fluoroscopy group. At two years, there was no difference in number of revision surgery, complications, FAOS, AOFAS, SF-36 or post-traumatic osteoarthritis.

Conclusion

The use of intraoperative 3D fluoroscopy in the treatment of intra articular calcaneal fractures prolongs the operative procedures without improving the quality of reduction and fixation. There was no benefit of intraoperative 3D fluoroscopy with regard to postoperative complications, quality of life, functional outcome or post-traumatic osteoarthritis.

Introduction

Displaced intra-articular calcaneal fractures are commonly treated by open reduction and internal fixation (ORIF).^{1,2} The goal of operative treatment is to restore functional anatomy, as intra-articular incongruence leads to poor clinical outcomes due to posttraumatic osteoarthritis of the subtalar joint.³⁻⁶ Despite the efforts to restore anatomy, up to 20% of operatively treated patients show a persisting step-off in the subtalar joint of >2mm.⁷⁻⁹ Intraoperative 2D fluoroscopy is used to evaluate the quality of reduction and implant position during open reduction and internal fixation (ORIF) of calcaneal fractures. Due to the complex anatomy of the calcaneus and the subtalar joint however conventional fluoroscopy might not always provide sufficient insight.^{3,10}

Three-dimensional (3D) fluoroscopy involves a mobile C-arm unit, modified to provide motorized rotational movement combined with a computer workstation. The system provides multiplanar 3D reconstructions of bony structures in addition to conventional 2-dimensional (2D) fluoroscopic images. The diagnostic accuracy of 3D fluoroscopy appears to be higher than 2D fluoroscopy and similar to computed tomography (CT) for the evaluation of both reduction and implant position.¹¹⁻¹⁴

3D fluoroscopy has proven to be a valuable addition to conventional intraoperative fluoroscopy in calcaneal fracture surgery.¹⁵ Previous studies of 3D fluoroscopy in calcaneal fracture surgery have reported intraoperative correction rate of up to 47% for indications that were not recognized on conventional 2D fluoroscopy.^{3,10,16,17} The effect of these corrective measures on the radiological and patient reported outcomes has been not been investigated yet.^{16,18}

The objective of this study was to investigate the clinical effect of additional intraoperative 3D fluoroscopy on postoperative quality of reduction and fixation and patient reported outcomes as compared to conventional 2D fluoroscopy in patients with intra-articular fractures of the calcaneus.

Methods

This multicenter randomized clinical trial was conducted in two academic level 1 trauma centers and one regional teaching hospital between December 2010 and July 2014, with a 2-year follow-up, as described in our published study protocol.¹⁹ Patients were eligible to participate if they sustained an intra-articular fracture of the calcaneus that required open reduction and internal fixation. Patients were included if they were older than 17 years and signed informed consent was obtained. Patients with bilateral fractures were allowed to participate with both extremities evaluated. Patients were excluded in case of pregnancy, a history of rheumatoid arthritis, or inability to comprehend the trial's features.

Our sample size calculation was based on the available literature at 2009. The frequency of suboptimal fracture reduction of intra-articular fractures of the wrist, ankle and calcaneus was 18-26%.²⁰⁻²² Research in our own hospital, based on postoperative X-rays showed a frequency of 17% (Weide vd A, Haverlag R, Goslings JC. Inconsistencies in the radiographic analysis of intra-articular fractures, not published). Based on Kendoff et al.,

we anticipated that a suboptimal fracture reduction and/or fixation will be found in 5% of the patients, when using the 3D-RX-system.²³ To detect a difference of 12% using a two group continuity corrected Chi-square test at an $\alpha=0.05$ and a power of $\beta=0.80$, we will need to include 122 patients per randomization group. To account for an approximately 3% dropout by technical or logistic failures of the 3D-RX-system, 250 patients have to be included for each fracture type.

Reduction and internal fixation were performed through an extended lateral approach (ETA) or sinus tarsi approach (STA), according to the surgeons' preference. Choice of implants was at the surgeon's discretion.

The study consisted of two distinct parts. In the first part 2D fluoroscopy was available for imaging throughout the operation until the surgeon was satisfied with the reduction and implant position. Prior to wound closure a 3D fluoroscopy scan was performed in all patients. Whether or not the intraoperative 3D images were to be made available to the surgeon was based on randomization. A dedicated and secured online randomization module performed block randomization stratified for participating center. Patients remained unaware of the availability of the 3D scan to the surgeon throughout the entire trial. In case the results of the 3D fluoroscopy were not made available, the surgeon ended the procedure by wound closure. If the results of 3D fluoroscopy were made available to the surgeon, the surgeon was asked to evaluate the available 3D images according to a scoring protocol for anatomical reduction and implant position, which was published previously.^{24,25} This protocol, based on Delphi consensus, specified 5 categories (23 individual points) to evaluate post-operative reduction of the most important anatomical landmarks of the calcaneus as well as hardware positioning.

Corrections were performed (if deemed necessary and feasible) and registered accordingly, after which an additional 3D fluoroscopy scan was performed and evaluated in a similar fashion.

Postoperative CT-scans were obtained within 7-days of surgery in all cases. Follow-up outpatient clinic visits were planned for 6 and 12 weeks and 1 and 2 years postoperatively. The postoperative CT scans were anonymized and systematically evaluated by three independent blinded observers (an experienced foot- and ankle surgeon, a musculoskeletal trauma radiologist and a PhD candidate with 4 years of research experience in calcaneal fractures). This systemical evaluation by the independent observers was performed at least 6 months after inclusion of patients in the study and did not influence clinical practice. For evaluation of the quality of fracture reduction and fixation and whether a revision was indicated, the previously mentioned imaging 23 question scoring protocol was utilized.^{24,25} Intra-articular gaps and steps measuring up to 2 mm were deemed acceptable.²⁵ A revision was indicated when one of the items was scored as 'not acceptable'. An indication for a revision was based only on the radiological evaluation. Technical difficulties, duration of the operation or other reasons not to perform a revision were not taken into account in the evaluation by the independent observers. Answers of the three blinded observers on these 23 items, as well as the indication for a revision in reduction and/or fixation,

were combined into a single radiological 'profile' of the fracture and implants. In case of inconsistency between observers, majority consensus was sought.

Primary outcome was the need for revision surgery as determined by the observers, based on the postoperative CT-scan as described above. Secondary outcomes were the number and type of corrections prior to wound closure after 2D and 3D fluoroscopy, complications, revision operations within one year, Foot and Ankle Outcome Score (FAOS), American Orthopedic Foot and Ankle Score (AOFAS) hindfoot score²⁶ and Short Form 36 (SF-36) questionnaire. Posttraumatic osteoarthritis was classified according to the Kellgren & Lawrence classification at two years postoperatively by three independent observers.²⁷ Total fluoroscopy time is given in seconds, total radiation dose is given as a dose area product (DAP) in mGy*cm². Previously published power calculations have shown a sample size of 250 subjects (125 subjects in both arms) for this trial.¹⁹

The BV Pulsera 3D-RX (Philips Healthcare, Best, the Netherlands) mobile C-arm unit prepared for motorized rotational movement for volumetric acquisition and a Philips 3D-RA workstation for visualization of the 3D data set was used in all participating centers. A series of 225 projection images is acquired over a period of 30 seconds during a 200-degree rotation of the C-arm. Both volume rendering and multiplanar reformations (MPR) in axial, coronal and sagittal planes were available for evaluation if randomized for allocation in 3D group.

Statistical analyses were performed in accordance with the intention to treat principle using software (SPSS 20.0 for Windows; Chicago, IL). The primary dichotomous outcome, indication for revision yes/no, as well as the number of intraoperative corrections based on available 3D fluoroscopy is described as a percentage in both groups. Differences between groups were given as a risk ratio (RR) and risk difference (RD). Scores of functional outcomes are expressed as means and standard deviations (SD) in case of normal distribution; non-normally distributed data was expressed as medians with ranges. Continuous parameters were analyzed using the Student's T-test (parametric data) or the Mann-Whitney U-test (non-parametric data).

Based on a previous study by Agren and colleagues, an additional subgroup analysis was performed.² We selected the subjects with the highest 50% AOFAS scores at 2 years postoperatively and performed a logistic regression analysis on age, fracture type (Sanders classification), open fractures, infections and the availability of 3D fluoroscopy. We repeated this analysis for arthrodesis at 2 years postoperatively.

This study was reported according to the principles of the Consolidated Standards of Reporting Trials (CONSORT) statement guidance. Approval was obtained from the medical ethics committee and all patients provided written informed consent. The study was registered under Dutch Trial Register NTR 1902.

Results

Between December 2010 and June 2014, a total of 102 fractures (i.e. subjects) in 100 patients were included in the study (Figure 1). Demographics are displayed in Table 1.

Study inclusion ended prior to reaching the expected 250 inclusions due to a lower than predicted accrual rate and subsequent budgetary restraints. No patient withdrew consent. Four patients (five calcaneal fractures) were lost to follow up at 12 months postoperatively, (2 patients in the 2D and 2 patients (3 fractures) in the 3D group).

Table 1: Patient, trauma and fracture characteristics

Characteristic	2D-group N (%)	3D-group N (%)	Mean Difference [95% CI]	Risk Ratio [95% CI]	Risk Difference [95% CI]
Number of subjects	52 (51.0)	50 (49.0)			
Including hospital				0.96 [0.70-1.32]	-1.31 [-11.87-9.25]
I	45 (86.5)	44 (88)		1.02 [0.88-1.18]	1.46 [-11.47-14.39]
II	5 (9.6)	3 (6.0)		0.62 [0.15-2.47]	-3.61 [-13.98-6.75]
III	2 (3.8)	3 (6.0)		0.69 [0.12-3.98]	-1.76 [-10.12-6.58]
Gender male	39 (75)	42 (84)		1.12 [0.91-1.37]	9 [-6.5-24.55]
Age, mean (SD)	47.3 (13.4)	45.6 (12.4)	1.7 [-3.4-6.8]		
Trauma mechanism					
Low Energy fall	12 (23.1)	10 (20.0)		0.87 [0.41-1.82]	-3.08 [-19.02-12.86]
Fall from height	38 (73.1)	37 (74.0)		1.01 [0.80-1.28]	0.92 [-16.2-18.04]
Motor vehicle accident	2 (3.8)	1 (2.0)		0.52 [0.05-5.56]	-1.85 [-8.36-4.66]
Other	0 (0.0)	2 (2.0)		-	3.48 [-1.38-9.07]
Concomitant fractures	10 (19.2)	17 (34.0)		1.77 [0.90-3.48]	14.77 [-2.18-31.71]
Ipsilateral lower extremity	3 (5.8)	2 (4.0)		0.69 [0.12-3.98]	-1.76 [-10.12-6.58]
Contralateral lower extremity	5 (9.6)	6 (12.0)		1.25 [0.41-3.83]	2.39 [-9.67-14.44]
Left-sided fracture	26 (50.0)	25 (50.0)		1.00 [0.68-1.47]	0.00 [-19.41-19.41]
Open fracture	1 (2.0)	2 (4.1)		2.08 [0.20-22.23]	2.12 [-4.60-8.84]
Sanders fracture type				1.08 [0.79-1.48]	2.21 [-3.25-7.66]
I	1 (1.9)	2 (4.0)		2.08 [0.19-22.22]	2.08 [-4.51-8.67]
II	18 (34.6)	18 (36.0)		1.04 [0.61-1.76]	1.39 [-17.17-19.94]
III	24 (46.2)	23 (46.0)		1.00 [0.65-1.52]	-0.15 [-19.50-19.20]
IV	9 (17.3)	7 (6.9)		1.34 [0.54-3.32]	4.54 [-9.58-18.66]

SD: standard deviation; CVD: cardiovascular disease; CI: confidence interval

Intraoperative effect 3D fluoroscopy on quality of reduction and patient-related outcome

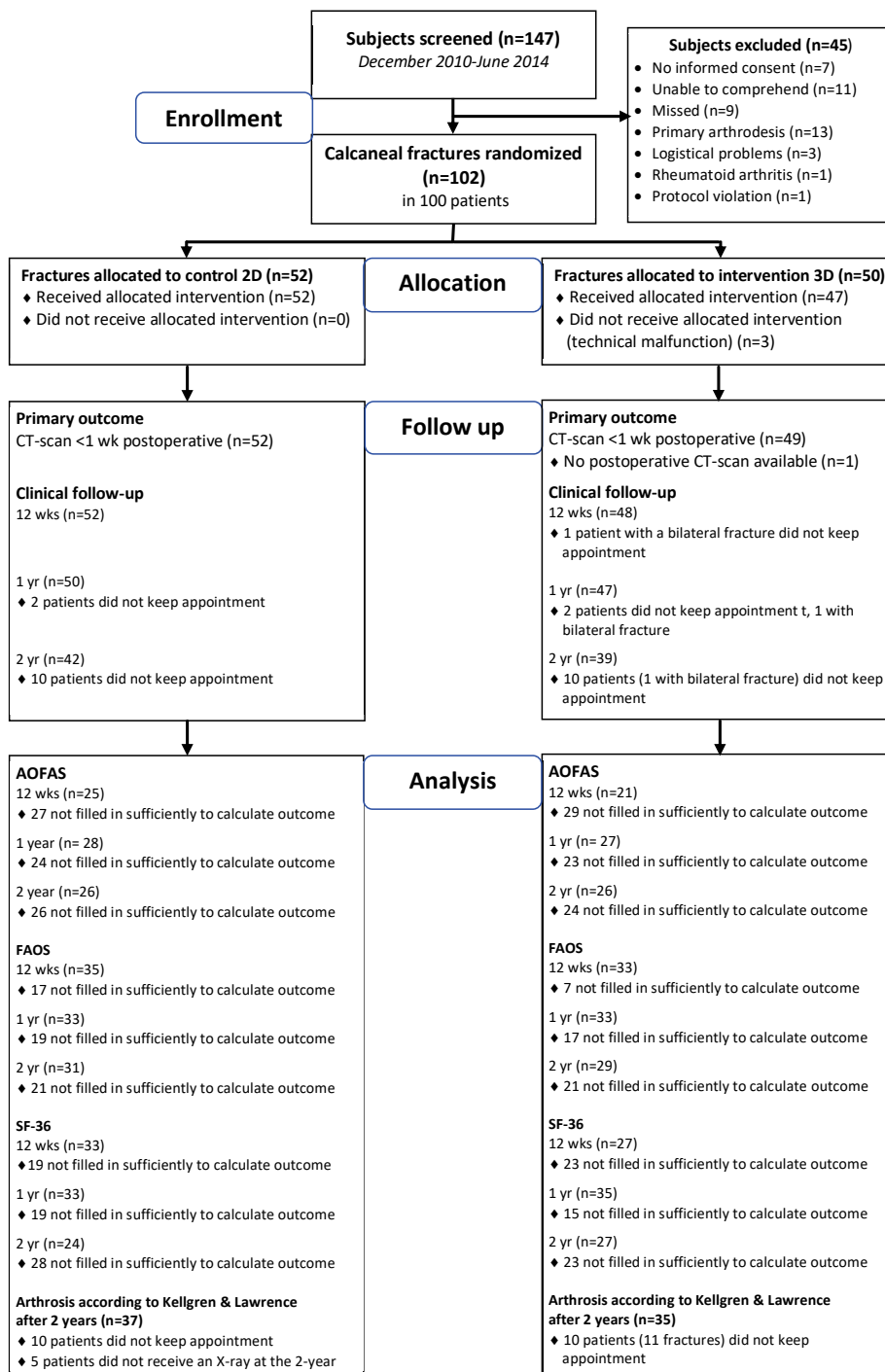


Figure 1: Flowchart of the EF3X-trial

In 81 (79.4%) cases an extended lateral approach (ELA) was used; in 20 (19.6%) cases the sinus tarsi approach (STA) was used and one calcaneal fracture (1%) underwent closed reduction and percutaneous fixation.

Of the 102 subjects, 50 were randomized to intraoperative availability of the 3D fluoroscopy (prior to wound closure); 52 subjects were operated with conventional 2D fluoroscopy alone (3D imaging was obtained but not available to the surgeon). Baseline characteristics were equally distributed among the randomization groups (table 1). In 3 subjects allocated in the 3D group, the 3D system was not available due to a technical error. Subsequently 47 subjects remained for analysis of which 28 (56.0%) underwent corrections after 3D images had been reviewed by the surgeon prior to wound closure. The majority of corrective measures (91.2%) aimed to enhance implant position of which details are shown in Table 2. Further fracture reduction was performed in five (8.8%) subjects after availability of 3D fluoroscopy images.

Radiation dose did not differ in terms of mGy and radiation time. However, the median mGy-m² differed significantly with a median of 0.06 mGy (range 0.03-2.25) in the 2D-group compared to 0.07 mGy (range 0.03-0.21).

The postoperative CT scan as evaluated by three independent observers revealed an indication for additional revision of reduction or implant position in 69.4% of the 3D group versus 59.6% in the 2D fluoroscopy group. The corresponding risk ratio of 1.16 (95% CI 0.87-1.56) did not reach statistical significance. Indications for revision of reduction or fixation by the raters, were actually performed in three subjects. In one subject in the 3D-scan group an intra-articular screw was revised. In the 2D-group 2 revision operations were performed; one because of an insufficient reduction of the PTC-joint and in another subject an intra-articular screw was revised. In seven subjects, indications for corrective measures were identified also identified intra-operatively but not performed for various reasons (Table 2).

Table 2: Operation characteristics, intra-operative imaging, corrections and radiologic outcome

Characteristic	2D group N (%)	3D Group N (%)	P-value
Days to surgery, median (range)	18 (2-60)	18 (4-72)	0.43
Duration of surgery (min), median (range)	125 (69-219)	147 (76-507)	0.00
Radiation dose, median (range)			
mGy	3.60 (1.63-9.74)	4.36 (1.44-10.40)	0.20
mGy-cm ²	570 (286-1290)	726 (304-2110)	0.04
Time (s)	100 (28-260)	105 (50-274)	0.28
Total nr corrections after 3D		57	
Type of corrections after 3D			
Reduction			
Step-off -		0 (0.0)	
Gap -		2 (3.5)	
Bone fragment -		2 (5.3)	
Other -		1 (1.8)	
Total Reduction		5 (8.8)	
Fixation			
Screw too long -		48 (84.2)	
Screw too short -		1 (1.8)	
Screw direction/position -		3 (5.3)	
Total implant position		52 (91.2)	
3D-based surgeon verdict			
Inadequate reduction -		4 (8.5)	
Inadequate implant position -		3 (6.5)	
Total inadequate ORIF		7 (15.2)	
Reason revision not performed			
Inadequate bone quality -		1 (1.8)	
Screw size not in stock -		1 (1.8)	
Reason unspecified -		5 (8.8)	
Total		7 (15.2)	

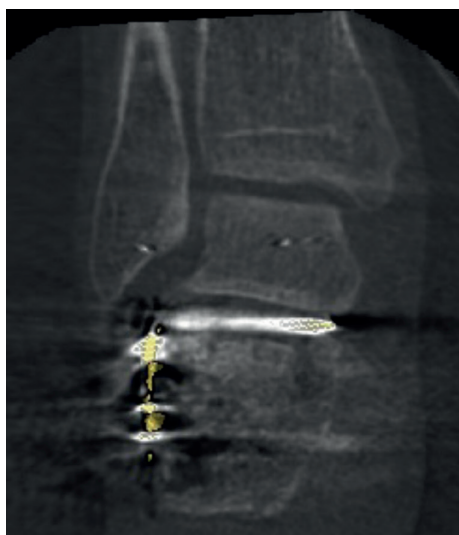ORIF: Open reduction & internal fixation; CI: confidence interval

Examples of intraoperative 3D- and corresponding postoperative CT images are shown in Figure 2. There was a statistically significant difference in duration of surgery between the groups with a median of 147 minutes (3D group) versus 125 minutes (2D group) ($p < 0.001$). Exclusion of the one outlier in the 3D group with 507 minutes due to operative treatment of concomitant injuries, did not change this result.

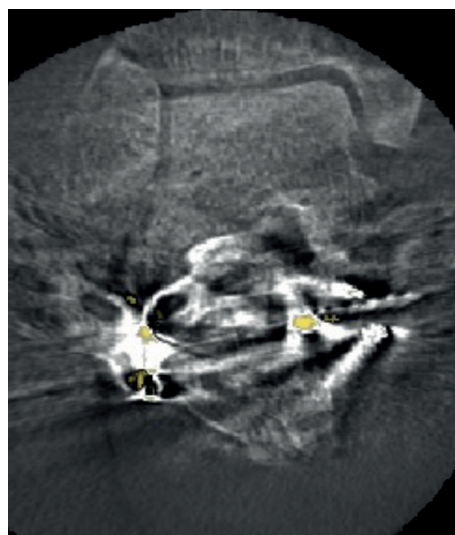
There were no significant differences between groups in terms of type of approach, revision surgery, complications, wound infections, posttraumatic osteoarthritis, short-term rate of arthrodesis, patient reported outcome measures including AOFAS, FAOS and SF-36 between the groups. Patient (reported)outcomes are shown in Supplementary Table 4.

Although infectious complications occurred more when ELA (29.1%) was used compared to STA (5.3%) (RR 0.18 [0.03-1.26; RD -23.85 [-38.03- -9.67]), additional subgroup regression analysis showed no association between 50% of patients with highest AOFAS score at 2 years postoperatively and age, fracture type, open fractures, type of approach, infections, availability of 3D fluoroscopy or duration of operation. Furthermore, we found no association for these factors with arthrodesis at 2 years postoperatively.

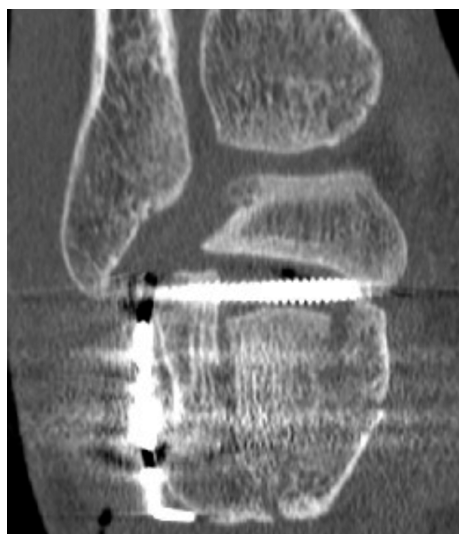



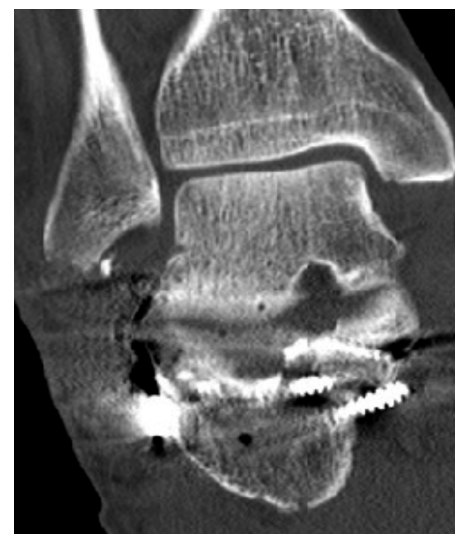Intraoperative 3D fluoroscopy



Intraoperative 3D fluoroscopy



Postoperative CT scan



Postoperative CT scan

Figure 2: Two examples of intraoperative 3D- and corresponding postoperative CT images **2a.** This subject was randomized in the **conventional 2D fluoroscopy** group. The postoperative CT scan clearly showed an unacceptable reduction of the posterior talocalcaneal (PTC) joint and an intra-articular screw position; both findings were also recognized on the postoperative evaluation of the 3D fluoroscopy. Patient underwent revision surgery within 24h and suffered from a superficial wound infection. **2b.** This subject was randomized to the **3D fluoroscopy** group. The 3D images however show substantial scattering, impeding proper evaluation of the images. The postoperative CT scan showed a medially protruding screw that missed the sustentaculum.

Table 3: Patient outcomes

Characteristic	2D group N (%)	3D group N (%)	Risk Ratio [95% CI]	Risk Difference [95% CI]
Revision required outcome independent observer	31 (59.6)	34 (69.4)	1.16 [0.87-1.56]	9.77 [-8.78-28.33]
Revision surgery (< 1 yr)				
Infection	6 (11.5)	3 (6.0)	0.52 [0.14-1.97]	-5.54 [-16.43-5.36]
Reduction	1 (1.9)	1 (2.0)	1.04 [0.07-16.18]	0.08 [-5.31-5.46]
Implant removal (planned)	0 (0.0)	1 (2.0)	-	2 [-1.88-5.88]
Implant removal (infection)	4 (7.7)	2 (4.0)	0.52 [0.10-2.71]	-3.69 [-12.74-5.36]
Implant removal (complaints)	8 (15.4)	6 (12.0)	0.78 [0.29-2.09]	-3.39 [-16.70-9.93]
Arthrodesis	1 (1.9)	2 (4.0)	2.08 [0.19-22.22]	2.08 [-4.51-8.67]
Infectious complications				
Superficial without antibiotics	0 (0.0)	2 (4.0)	-	4 [-1.43-9.43]
Superficial with antibiotics	4 (7.7)	1 (2.0)	0.26 [0.03-2.25]	-5.69 [-13.91-2.52]
Deep with debridement	7 (13.5)	4 (8.0)	0.59 [0.19-1.91]	-5.46 [-17.40-6.48]
Deep with hardware removal	3 (5.8)	4 (8.0)	1.39 [0.33-5.89]	2.23 [-7.60-12.06]
Total infections	14 (26.9)	11 (22.0)	0.82 [0.41-1.63]	-4.92 [-21.57-11.72]
Posttraumatic arthritis (2 years, KLGS)				
0	2 (3.8)	1 (2.0)	0.53 [0.05-5.57]	-2.49 [-11.39-6.42]
1	7 (13.5)	10 (20.0)	1.51 [0.64-3.53]	9.36 [-9.77-28.49]
2	12 (23.1)	8 (16.0)	0.70 [0.33-1.52]	-9.36 [-29.43-0.71]
3	12 (23.1)	10 (20.0)	0.88 [0.43-1.78]	-3.80 [-24.6-16.99]
4	5 (9.6)	7 (14.0)	1.48 [0.52-4.24]	6.29 [-10.52-23.1]
Missing	14 (26.9)	14 (28.0)		
Arthrodesis (within 2 years)	1 (2.0)	5 (10.2)	5 [0.61-41.2]	8.16 [-1.19-17.5]

KLGS: Kellgren & Lawrence Grading Scale; CRPS: Complex Regional Pain Syndrome; ROM: Range of Motion



Table 4: Patient outcomes

Characteristic		2D group N (%)	3D group N (%)	P-value
ROM, median (range)				
	Dorsi/plantar flexion			
	1 yr FU	50.0 (30-80)	55.0 (20-80)	0.44
	2 yr FU	50.0 (30-90)	55.0 (20-80)	0.43
	In/Eversion			
	1 yr FU	15.0 (0-50)	20.0 (0-60)	0.80
	2 yr FU	7.5 (0-60)	10.0 (0-40)	0.48
AOFAS, median (range)				
	1 yr FU	80.5 (54-97)	78.0 (38-97)	0.19
	2 yr FU	82.0 (46-100)	80.0 (26-100)	0.51
FAOS, median (range)				
	Symptoms			
	1 yr FU	57.1 (18-82)	55.4 (29-82)	0.75
	2 yr FU	57.1 (29-86)	53.6 (29-79)	0.51
	Pain			
	1 yr FU	65.3 (3-100)	69.4 (39-100)	0.37
	2 yr FU	75.0 (6-100)	75.0 (28-100)	0.82
	ADL			
	1 yr FU	82.4 (19-100)	79.4 (32-100)	0.94
	2 yr FU	92.7 (15-100)	86.8 (32-100)	0.50
	Sport/ Recreation			
	1 yr FU	40.0 (0-100)	45.0 (0-100)	0.90
	2 yr FU	65.0 (0-100)	70.0 (0-100)	0.50
	Quality of Life			
	1 yr FU	56.3 (6-100)	43.8 (0-94)	0.34
	2 yr FU	56.3 (0-94)	86.8 (32-100)	0.88
SF-36, median (range)				
	PCS			
	1 yr FU	43.1 (23-59)	41.9 (27-59)	0.96
	2 yr FU	48.6 (29-61)	45.2 (27-61)	0.43
	MCS			
	1 yr FU	56.5 (28-65)	41.9 (27-59)	0.17
	2 yr FU	50.9 (20-60)	52.6 (26-61)	0.71

PCS: Physical Component Scale; MCS: Mental Component Scale.

Discussion

Despite 57 individual intraoperative corrections in 28 subjects (56% of the 3D group), the current study did not find a beneficial effect of intraoperative 3D fluoroscopy in terms of radiological, patient reported or functional (e.g. ROM) outcome as compared to conventional 2D fluoroscopy. Follow-up CT scan revealed indications for revision regardless of prior availability of 3D fluoroscopy images during surgery and performed corrections. Moreover, the duration of the surgical procedure was significantly longer in the 3D group.

To our knowledge, this is the first randomized controlled trial reporting the functional results of patients in which additional 3D fluoroscopy was compared to conventional

fluoroscopy in the treatment of calcaneal fractures. In 2015, Gwak et al. published a retrospective cohort study of 60 calcaneal fractures, half of which were treated with additional 3D fluoroscopy. In accordance with our results, they found no statistically significant differences between groups in terms of Böhler's angle, Gissane's angle, AOFAS or VAS pain score after 2 years postoperatively.¹⁷

Most other available studies reporting on 3D fluoroscopy lack a control group or put emphasis on the number of intraoperative 3D related corrections rather than reporting functional or radiological outcomes.^{11,14,23,30} In 2015, Eckhardt et al. published on a series of 62 calcaneal fractures operated on using intraoperative 3D imaging.¹¹ They used an O-arm with high quality imaging, leading to 40% corrections and good radiological results on the final intraoperative 3D scan. No postoperative CT scan was made as a gold standard, they did not have a control group with conventional fluoroscopy, nor did they report functional outcome. In 2014, Franke et al. published a large retrospective cohort of operatively treated calcaneal fractures using 3D fluoroscopy and showed an intraoperative correction rate of 40.3%.¹⁴ Of the evaluated group, 45% still had residual step-off of ≥ 2 mm on the postoperative evaluation of the 3D scan. No control group was mentioned in terms of 2D fluoroscopy.

Our results show considerable percentages of indications for revision based on the postoperative CT-scan. Multiple factors potentially contribute to these high revision rates. First, we evaluated 23 items of reduction and fixation per subject. These items included, Böhler and Gissane's angle, as well as steps, gaps and bone fragments of the PTC-, CC- and ATC-joint. Additionally, the position of fixation material was scored in the previously mentioned joints and the sustentaculum and medial wall. When scoring to such an extent instead of solely focusing on e.g. the joint surface, it is more likely to find indications for improvement. Moreover, images were often difficult to interpret due to the amount of scattering caused by the implants regardless of software used. Third and most important, the evaluation of our CT images was done outside of the operation theater. Consequently, observers were not hampered by the reality of operative challenges, additional risks of further surgical procedures and time constraints, lowering the threshold for finding indications for implant and reduction improvement.

Only in 10 subjects the indicated revisions were identified by the operating surgeons, and only three of them were actually revised. The postoperative CT-scans were evaluated by the operating surgeon, but not scored by them according to the 23-item scoring list. Therefore, we do not know whether the other indicated revisions were also identified by the operating surgeons. Reasons for the much lower actual revision rate could have been the operating surgeons do not agree with the rater's indications for revision. Other reasons could be lack of bone stock, technical challenges or risk of wound infection by a second operation.

Despite the high percentage of indicated revisions, functional results of our cohort are comparable to the literature. In 2009, Kienast et al. used 3D fluoroscopy in a series of 136 operatively treated calcaneal fractures.²³ At an average follow up of 8.6 months the average AOFAS scored between 81 and 84. The previously mentioned study by Gwak et

al. reported average AOFAS scores between 78.3 and 82.3 after two year follow up.¹⁷ The minimal clinically important difference (MCID) of the AOFAS following calcaneal fracture surgery is not known, however the AOFAS difference between 2D and 3D group is well below the known MCID for hallux valgus surgery (7.9 points).⁸ SF-36 scores are similar compared with other large clinical trials.^{2,16}

In this study, there was an indication for a revision in respectively 69.4% of the 3D group versus 59.6% in the 2D-group. This indication for revision rate almost triples the 20% described in the literature.^{2,7,16} Reason for this difference is that we performed an extensive evaluation of the postoperative CT-scan, while most of the mentioned studies based their indications for revision on postoperative X-rays. Not articular incongruences and misplaced fixation material found in CT-scans are detected on X-rays.

In addition, the strict evaluation of the postoperative CT-scan shows no relation with the postoperative clinical outcome or incidence of 2-year posttraumatic arthritis. This could be due to our limited number of subjects and the variety of incidence of incongruences in the reduction and fixation of the calcaneal fractures. Another reason could be that the indications for revisions based on the postoperative CT-scan were too strict.

In our study, 24.5% of subjects suffered from a post-operative wound infection, which is quite high, but also encountered in other studies.^{2,11,16} The large number of extended lateral approaches is responsible for the more than 20% wound complications, comparable to the literature.^{26,32} Although there is a shift to the use of the sinus tarsi approach, the extended lateral approach has not been abandoned completely.¹⁹ Even though there is a difference in infectious complications between ELA and STA, Schepers et al. showed there are no differences in radiological outcome between the two approaches.³² In addition, the type of approach was not related with patient-relevant outcomes or posttraumatic arthritis in our study.

A strength of this study is that we were able to evaluate clinical effectiveness of this technique by comparison of an intervention (3D) and a control group (2D). Not only were we able to obtain validated functional outcome parameters, but also systemically evaluated reduction and hardware position on CT using a detailed protocol. Instead of exact measurements that are mostly performed in research settings, we have used subjective evaluations (e.g. good, moderate or poor). This approach mimics intraoperative evaluation. During surgery no measurements (e.g. Böhlers angle measurement) can be performed: the surgeon can only eyeball the quality of reduction and fixation, based on his experience with the acceptable measurements. Moreover, subjective (categorical) and objective (numerical values) evaluations have previously proven to have a good correlation.¹⁸

Limitations of this study include that as the project progressed, surgeons got more accustomed to the use of 3D fluoroscopy techniques. Inspired by the benefits of multiple angle views, surgeons sporadically used continuous fluoroscopy whilst turning the foot manually. This maneuver potentially provided additional information, leading to more radiation exposure and reduced the additional value of 3D fluoroscopy.

Even though study inclusion was ended prior to reaching the expected 250 inclusions, for the primary radiological outcome no trend toward clinically relevant differences were seen. Therefore, we do not believe results would have been different when we would have included more patients. Our power calculation was based on a suboptimal reduction and fixation of only 17% based on postoperative X-rays. As we can identify more suboptimal aspects in reduction and fixation based on a CT-scan, first a definition of CT-based indications for revisions have to be developed in order to perform a proper power analysis.

This study was designed with analysis of the diagnostic accuracy of 3D fluoroscopy in mind. For this purpose, both randomization groups were subject to 3D fluoroscopy. As the radiation dose of a single 3D scan is different for each individual subject, we were not able to correct for the received 3D scan in the 2D group. Hence, the additional radiation dose in the 3D group as mentioned in Table 2 is a consequence of fluoroscopy (2D and/or 3D) used *after* the initial 3D scan. The maximum equivalent dosage of a 3D-RX-scan of the extremities is 17 μ Sv. Although in the 3D-group more 3D-scans are performed, no clinically relevant difference can be seen between groups in terms of radiation exposure. Unfortunately, we cannot extract the radiation dose used for 2D-fluoroscopy alone and the fluoroscopy used for the 3D-run. However, this suggests that the additional 2D-fluoroscopy dosage used for 2D-images is comparable to the radiation dose of a 3D-scan. Additional radiation exposure for the patient and personnel can be classified as 'minor risk' according to the ICRP (report ICRP62).

The radiation exposure is expressed as dose area product (DAP) in $\text{mGy} \cdot \text{cm}^2$: we chose to refrain from estimating effective dose (mSv) because of its uncertain reliability.^{31,34} Rausch et al. reported a mean DAP of $392 \pm 145 \text{ mGy/cm}^2$ for 3D fluoroscopy in a series of operatively treated wrist fractures.²⁹ Our 3D group received a median of 726 mGy/cm^2 . The bigger mass of the lower extremity is accountable for a large part of this difference in radiation dose.

With high percentages of intraoperative corrections, mainly implant related, it is likely that 3D fluoroscopy has some form of advantage. Future studies should elucidate and specify these advantages, potentially by narrowing down the indications for use of this technique. Calcaneal fractures that are particularly at risk for medial or intra-articular screw protrusion might benefit from 3D more fluoroscopy than fractures that need less complex fixation.

Conclusion

The use of intraoperative 3D fluoroscopy prolongs the procedure without improving the quality of reduction and fixation in the management of calcaneal fractures. We found no benefit of intraoperative 3D fluoroscopy with regard to postoperative complications, quality of life, functional outcome or post-traumatic osteoarthritis at 2-year follow-up.

References

1. Bruce M.J., Sutherland A. Surgical versus conservative interventions for displaced intra-articular calcaneal fractures. *The Cochrane Database of Systematic Reviews* 2013; 1: CD008628 .
2. Agren P.H., Mukka S., Tullberg T., et al. Factors affecting long-term treatment results of displaced intra-articular calcaneal fractures: A post-hoc analysis of a prospective, randomized, controlled multicenter trial. *Journal of Orthopaedic Trauma* 2014; 28: 564–568.
3. Franke J., Wendl K., Suda A.J., et al. Intraoperative three-dimensional imaging in the treatment of calcaneal fractures. *The Journal of Bone and Joint Surgery (American Volume)* 2014; 96: e72
4. Thordarson D., Krieger L. Operative vs. nonoperative treatment of intra-articular fractures of the calcaneus: A prospective randomized trial. *Foot & Ankle International* 1996; 17: 2–9.
5. Pozo J.L., Kirwan E.O., Jackson A.M. The long-term results of conservative management of severely displaced fractures of the calcaneus. *The Journal of Bone and Joint Surgery (British Volume)* 1984; 66: 386–90.
6. Paley D., Hall H. Intra-articular fractures of the calcaneus. A critical analysis of results and prognostic factors. *The Journal of Bone and Joint Surgery (American Volume)* 1993; 75: 342–54.
7. Buckley R., Tough S., McCormack R., et al. Operative compared with nonoperative treatment of displaced intra-articular calcaneal fractures: A prospective, randomized, controlled multicenter trial. *The Journal of Bone and Joint Surgery (American Volume)* 2002; 84-A: 1733–44.
8. Agren P.H., Wretenberg P. & Sayed-Noor A.S. Operative versus nonoperative treatment of displaced intra-articular calcaneal fractures: A prospective, randomized, controlled multicenter trial. *The Journal of Bone and Joint Surgery (American Volume)* 2013; 95: 1351–7.
9. Griffin D., Parsons N., Shaw E., et al. Operative versus non-operative treatment for closed, displaced, intra-articular fractures of the calcaneus: Randomised controlled trial. *British Medical Journal* 2014; 349: 1–13.
10. von Recum J., Wendl K., Vock B., et al. Intraoperative 3D C-arm imaging. State of the art. *Unfallchirurg* 2012; 115: 196–201.
11. Euler E., Wirth S., Linsenmaier U., et al. Comparative study of the quality of C-arm based 3D imaging of the talus. *Unfallchirurg* 2001; 104: 839–46.
12. Kendoff D., Citak M., Gardner M., et al. Three-dimensional fluoroscopy for evaluation of articular reduction and screw placement in calcaneal fractures. *Foot & Ankle International* 2007; 28: 1165–71.
13. Weil Y.A., Liebergall M, Mosheiff R., et al. Assessment of two 3-D fluoroscopic systems for articular fracture reduction: A cadaver study. *International Journal of Computer Assisted Radiology and Surgery* 2011; 6: 685–92.

14. Beerekamp M.S.H., Sulkers G.S., Ubbink D.T., et al. Accuracy and consequences of 3D-fluoroscopy in upper and lower extremity fracture treatment: a systematic review. *European Journal of Radiology* 2012; 81: 4019–28.
15. Geerling J., Kendoff D., Citak M., et al. Intraoperative 3D imaging in calcaneal fracture care-clinical implications and decision making. *The Journal of Trauma* 2009; 66: 768–73.
16. Franke J., von Recum J., Wendl K., et al. & Intraoperative 3-dimensional imaging - beneficial or necessary? *Unfallchirurg* 2013; 116: 185–90.
17. Kienast B., Gille J., Queitsch C., et al. Early weight bearing of calcaneal fractures treated by intraoperative 3D-fluoroscopy and locked-screw plate fixation. *The Open Orthopaedics Journal* 2009; 3: 69–74.
18. Gwak H.C., Kim J.G., Kim J.H., et al. Intraoperative Three-Dimensional Imaging in Calcaneal Fracture Treatment. *Clinics in Orthopedic Surgery* 2015; 7: 483–9.
19. Beerekamp M.S.H., Ubbink D.T., Maas M., et al. Fracture surgery of the extremities with the intra-operative use of 3D-RX: a randomized multicenter trial (EF3X-trial). *BMC Musculoskeletal Disorders* 2011; 12: 151.
20. Chen S.H., Wu P.H., Lee Y.S. Long-term results of pilon fractures. *Archives of Orthopaedic and Trauma Surgery* 2007; **127**: 55–60.
21. Langenhuijsen J.F., Heetveld M.J., Ultee J.M., Steller E.P., et al. Results of ankle fractures with involvement of the posterior tibial margin. *The Journal of Trauma* 2002; 53: 55–60 (2002).
22. Stulik J., Stehlik J., Rysavy M., et al. Minimally-invasive treatment of intra-articular fractures of the calcaneum. *The Journal of Bone and Joint Surgery (British Volume)* 2006; 88: 1634–41.
23. Kendoff D., Citak M., Gardner M.J., et al. Intraoperative 3D imaging: Value and consequences in 248 cases. *The Journal of Trauma* 2009; 66: 232–8.
24. Beerekamp M.S.H., Luitse J.S.K., Ubbink D.T., et al. Evaluation of reduction and fixation of calcaneal fractures: A Delphi consensus. *Archives of Orthopaedic Trauma Surgery* 2013; 133: 1377-84.
25. de Muinck Keizer R.J.O., Beerekamp M.S.H., Ubbink D.T., et al. Systematic CT evaluation of reduction and hardware positioning of surgically treated calcaneal fractures: A reliability analysis. *Archives of Orthopaedic Trauma Surgery* 2017; 137: 1261-7.
26. Cöster M.C., Rosengren B.E., Bremander A., et al. Comparison of the Self-reported Foot and Ankle Score (SEFAS) and the American Orthopedic Foot and Ankle Society Score (AOFAS). *Foot & Ankle International* 2014; 35: 1031–6.
27. Kellgren J.H., Lawrence J.S. Radiological Assessment of Osteo-Arthrosis. *Annals of the Rheumatic Diseases* 1957; 16: 494–503.
28. Eckardt H., Lind M. Effect of Intraoperative Three-Dimensional Imaging During the Reduction and Fixation of Displaced Calcaneal Fractures on Articular Congruence and Implant Fixation. *Foot & Ankle International* 2015; 36: 764–73.

29. Chan H.Y., Chen J.Y., Zainul-Abidin S., et al. Minimal clinically important differences for American Orthopaedic Foot & Ankle Society score in hallux valgus surgery. *Foot & Ankle International* 2017; 38: 551-7.
30. Schepers T., Backes M., Dingemans S.A., et al. Similar anatomical reduction and lower complication rates with the sinus tarsi approach compared with the extended lateral approach in displaced intra-articular calcaneal fractures. *Journal of Orthopaedic Trauma* 2017; 31: 293-298.
31. Nosewicz T.L., Dingemans S.A., Backes M., et al. A systematic review and meta-analysis of the sinus tarsi and extended lateral approach in the operative treatment of displaced intra-articular calcaneal fractures. *Foot and Ankle Surgery* 2019; 25: 580-8.
32. Jansen S.C.P., Bransen J., van Montfort G., et al. Should the extended lateral approach remain part of standard treatment in displaced Intra-articular calcaneal fractures? *The Journal of Foot and Ankle Surgery* 2018; 57: 1120-4.
33. Heiney J.P., Redfern R.E., Wanjiku S. Subjective and novel objective radiographic evaluation of inflatable bone tamp treatment of articular calcaneus, tibial plateau, tibial pilon and distal radius fractures. *Injury* 2013; 44: 1127-34.
34. Saltybaeva N., Jafari M.E., Hupfer M., et al. Effective Dose Estimates for CT scans of Lower Extremities. *Radiology* 2014; 273: 153-9.
35. Svalkvist A., Hansson J., Bath M. Estimating effective dose from 3D imaging with interventional fluoroscopy systems using limited exposure data. *Acta Radiologica* 2016; 57: 356-361.
36. Rausch S., Marintschev I., Graul I., et al. Tangential view and intraoperative three-dimensional fluoroscopy for the detection of screw-misplacements in volar plating of distal radius fractures. *Archives of Trauma Research* 2015; 4: e24622.



Chapter 9

The correlation between intraoperative 2D- and 3D fluoroscopy with postoperative CT-scans in the treatment of calcaneal fractures

M.S.H. Beerekamp, R.J.O. de Muinck Keizer, T. Schepers, L.F.M. Beenen,
J.S.K. Luitse, N.W. Schep, D.T. Ubbink, J.C. Goslings, on behalf of the EF3X-study
group*

The EF3X-study group: M.J.M. Segers, T.J. Blokhuis, V.M. de Jong,
J. Winkelhagen, B. Twigt, M. Maas

European Journal of Radiology 2019; 112: 222-228

Abstract

Objectives

The aim of this study was to determine the correlation of the intra-operative fluoroscopic 2D- and 3D-images compared with a postoperative CT-scan, in terms of quality of reduction and fixation of calcaneal fractures.

Methods

Patients requiring open reduction and internal fixation (ORIF) of a calcaneal fracture were recruited as part of the EF3X-trial. During surgery, intra-operative images of fluoroscopic 2D- and 3D-imaging were obtained to assess the quality of the reduction and implant position. All patients received a postoperative CT-scan within one week.

The operating surgeon evaluated intra-operatively both 2D- and 3D-images according to a 23-item scoring protocol on a 3-point Likert scale. A scoring panel, consisting of three clinical experts, evaluated all images in a blinded and independent fashion. Intraclass correlation coefficients (ICC) with their 95% confidence intervals (CI) were calculated using a two-way-random model with absolute agreement.

Results

A total of 102 calcaneal fractures were included. Agreement of 3D-imaging for the quality of reduction was better than 2D-imaging, although still fair, but for fixation moderate to good. Agreement between the 2D-images and the CT-scans was poor to fair. Intra-operative 2D-imaging received the highest ratings for image quality and interpretability, followed by CT-scanning.

Conclusion

Implant position can be evaluated satisfactory with the aid of intra-operative 3D-imaging. Although intra-operative 3D imaging had a better agreement with postoperative CT-scanning than 2D-imaging, there is a need to improve image quality and suppress scattering from implants to improve the additional value of intra-operative 3D imaging in calcaneal fracture reduction and fixation.

Introduction

The quality of reduction and accurate implant positioning in patients treated operatively for calcaneal fractures are considered important factor predictors for functional outcome.¹⁻⁶ To facilitate assessment of the reduction and implant positioning during surgery, intra-operative 3D-fluoroscopy (3D-imaging) was introduced in addition to conventional intra-operative 2D-fluoroscopy (2D-imaging).

Diagnostic accuracy of intra-operative 3D-imaging is assessed similar to CT-scanning in cadaver studies.⁷⁻¹¹ However, these studies evaluated a single screw implanted and fractures consisting of two fragments. This is not in concordance with clinical practice; commonly fractures are comminute and require multiple screws and a plate. As the number of implants negatively affects the image quality due to scattering, the interpretability and consequently the diagnostic accuracy of the images decreases with multiple implants.

The aim of this study was to correlate the surgeons' intraoperative evaluation of intra-operative fluoroscopic 2D- and 3D images with postoperative CT-scans in terms of quality of fracture reduction and implant position in operatively treated calcaneal fractures. Secondly, the same correlations were calculated when judged by an independent scoring panel.

Methods

This study was performed in accordance with the Quality Assessment of Diagnostic Accuracy Studies (QUADAS)-2 statement.¹²

Patients

Patients were participants of a randomised clinical trial, the EF3X-trial.¹³ In this trial the clinical effectiveness of the additional use of intra-operative 3D-imaging to 2D-imaging in the operative treatment of calcaneal, wrist and ankle fractures was studied. Approval was obtained from the medical ethics committee and all patients provided written informed consent. The study was registered under Dutch Trial Register NTR 1902.

All patients with a calcaneal fracture were included between December 2010 and July 2015, if they met the following inclusion criteria: Adult patients with a calcaneal Sanders classification I-IV fracture requiring surgery (ORIF or CRIF); no pathological fracture; no rheumatoid osteoarthritis; not pregnant; able to understand trial features and having signed informed consent.

Index test

Both 2D- and 3D-imaging techniques were used intra-operatively. For this purpose, the BV Pulsera (Philips Healthcare, Best, the Netherlands) with 3D-RX (3-Dimensional Rotational X-ray) was used. The use of 2D-imaging was at the disposal of the surgeon until he was satisfied with the reduction and implant position. Final images were obtained consisting of at least three views (lateral, axial and Brodén) to represent the result of the reduction and implant position.

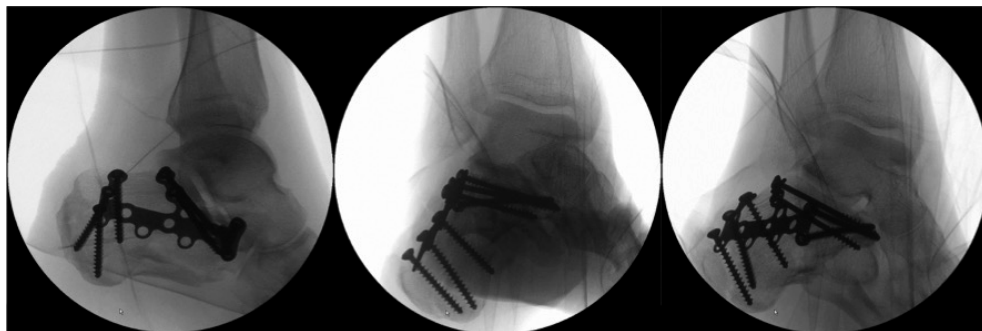


Figure 1: Intra-operative 2D-images
 Final intra-operative 2D-images. From left to right: Lateral, axial and Brodén view.

Hereafter, 3D-imaging was performed. All scans acquired 225 projection images over a period of 30 seconds during a 200° rotation of the C-arm. The projection images were used to reconstruct a 3D data set. Both volume rendering and slice images in 3 different directions (coronal, axial and sagittal planes) were available. The images could be enhanced by automatic colouring the implants (Titanview®). The radiation exposure of each image in the scanning run is dynamically adjusted to provide the best combination of low dose and optimal image quality.

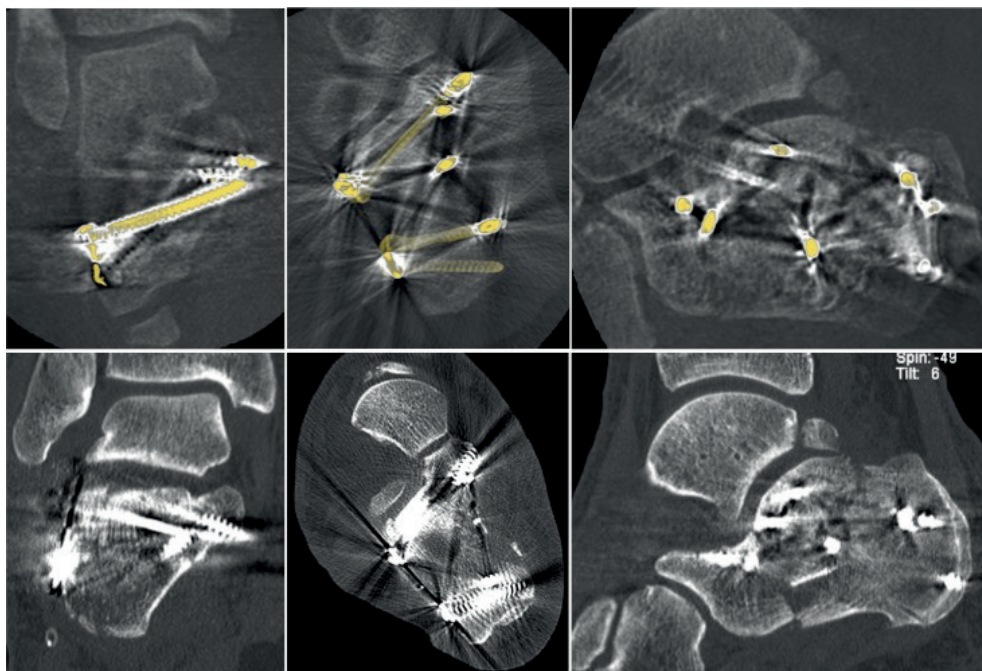


Figure 2: Intra-operative 3D-reconstructions and postoperative CT-scan
 Upper row intra-operative 3D-scan with, from left to right, coronal, axial and sagittal reconstructions
 Lower row postoperative CT-scan with, from left to right, coronal, axial and sagittal reconstructions

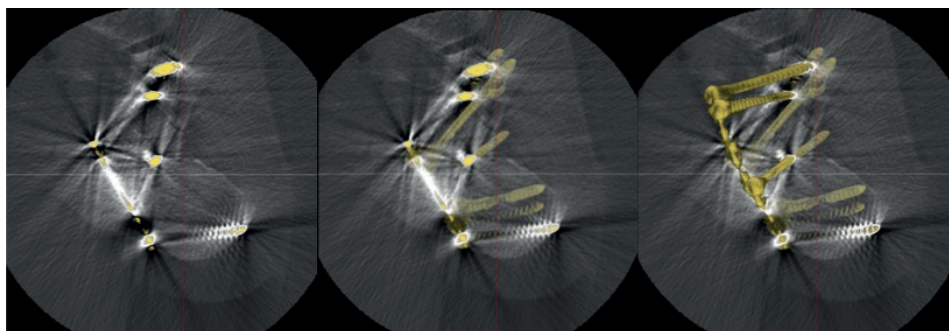


Figure 3: Titanview

Titanview® is software that colors the implants automatically

Left image: Implants in the current plane are colored

Middle image: Implants in both the current plane as well as the background are colored

Right image: Implants in the current plane as well as the fore- and background are colored

Randomisation determined whether the intra-operative images of 3D imaging were available to the surgeon. If 3D-imaging was available to the surgeon, corrections in both reduction and implant position were allowed. After the surgeon was satisfied with the reduction and implant position, final 3D imaging was performed. Only the final 3D images were used for this study. 2D-images were used when 3D imaging was not available to the surgeon or no corrections were performed after 3D imaging.

Reference standard

All patients underwent postoperative CT-scanning within one week after surgery. This postoperative CT-scan was used as a reference standard. CT-scans were performed using 64-slice CT-scanners with a maximal axial slice thickness of 1 mm. Standard multiplanar reconstructions (coronal, axial and sagittal plane) were available.

Assessment of quality of reduction and implant position of calcaneal fractures

The quality of reduction and implant position was evaluated according to a standard scoring protocol based on a Delphi consensus of international experts in calcaneal fracture surgery.^{14,15} The inter- and intra-observer reliability of this scoring protocol is similar to the measurements of Böhler's and Gissane's angles on conventional X-rays and 3D-CT-reconstructions.^{15,16}

This scoring protocol consists of 23 items evaluating the quality of reduction, implant (mal) positioning and quality of imaging. Reduction of the articulating surfaces of the calcaneus (the calcaneocuboid (CC), the posterior talocalcaneal (PTC) and anterior talocalcaneal (ATC) joint) consisted of assessment of the symmetry and width of the joint, presence of step-offs, gaps and intra-articular bone fragments. These items were scored on a 3-point Likert scale in the categories: 'anatomic'; 'not anatomic but acceptable'; 'not anatomic and not acceptable'; or 'not judgeable'. Implant position was evaluated for screw protrusion in the articular surface of the CC, PTC or ATC-joints and/or medial wall. Additionally, plate

position and correct positioning of screws in the sustentaculum and anterior process were evaluated.

All images available to the operating surgeon were evaluated intra-operatively. In order to provide an objective and independent evaluation, without interference of clinical information of direct sight on the fracture or information of perioperative images, all images were anonymized and systematically evaluated by a scoring panel consisting of 3 clinical experts (one trauma surgeon, one radiologist, one orthopaedic resident). The average scores of this scoring panel were used for the analyses.

Statistical analyses

Descriptive statistics were used to report image quality (SPSS version 23, IBM, Armonk, NY, USA). Usually diagnostic accuracy is expressed as sensitivity and specificity, requiring dichotomous outcomes of the radiologic evaluation. However, the scoring protocol, based on a Delphi consensus, consisted of a 3-point Likert scale. Therefore, intraclass correlation coefficients (ICC) with their 95% confidence intervals (CI) were calculated with a two-way-random model with absolute agreement. This model was used to enable generalisation of the results to a wider population. As for diagnostic accuracy purposes, scores have to be similar and not only consistent hence absolute agreement was used. Only single measures were reported for the clinical evaluation as well as the average evaluation of the scoring panel of both 2D- and 3D-fluoroscopy compared to average evaluation of the postoperative CT-scan. This was decided because in clinical practice the of 2D- and 3D-fluoroscopy will be rated by one person (i.e. the operating surgeon).¹⁷ Items scored as 'not judgeable' were excluded from the analysis.

Cut-offs were used as provided by Cicchetti et al. The reliability was considered 'poor' for ICC values less than 0.40, 'fair' for values between 0.40 and 0.59, 'good' for values between 0.60 and 0.74, and 'excellent' for values between 0.75 and 1.0 were used. An ICC of 0.60 was set as the minimal acceptable level of agreement.¹⁸

Results

102 calcaneal fractures in 100 patients were included for analysis. The fractures were classified on a pre-operative CT-scan as Type I (3); type II (36); type III (47); and type IV (16) according to the Sanders classification. Based on the postoperative CT-scan at least one of the reduction items was scored as 'not anatomical, not acceptable' in 19%, and one of the implant positioning items was 'not acceptable' in 26% of the calcaneal fractures, compared to 6% and 17%, respectively, based on evaluation of the 3D-images by the scoring panel

The 2D-images of 74 calcaneal fractures were included in the analysis, as these were the final images because 3D-imaging was not available due to randomisation or no corrections were performed after 3D-imaging. The surgeon was allowed to intra-operatively evaluate 3D-images in 50 cases. In six patients 3D-images were not saved correctly and could therefore not be evaluated by the scoring panel, one postoperative CT-scan was missing. The scoring panel evaluated all 3D-images of the 95 calcaneal fractures included in the

trial. Postoperative CT-scans were obtained in all but one patient and evaluated by the scoring panel. Therefore, correlation could be determined for 95 calcaneal fractures.

The median radiation dose intra-operatively, including both 2D- and 3D-imaging, differed significantly between the two randomisation groups. When the intra-operative 3D-scan was not available to the surgeon the median radiation dose was 570 mGy/cm² (range 286-1290 mGy/cm²). If the 3D-scan was available to the surgeon, the median radiation dose was 726 mGy/cm² (range 304-2110 mGy/cm²).

Intraclass correlation of intra-operative fluoroscopic 2D-imaging with computed tomography

The evaluation of reduction and fixation by the scoring panel showed a 'fair' ICC with the evaluation of the postoperative CT-scan except for the length of the calcaneus and varus/valgus position, which showed a 'moderate' ICC. (Table 1). For correlation of the surgeon's intra-operative evaluation showed a 'fair' ICC for all the items of reduction and fixation.

Table 1: Intraclass correlation coefficient of intra-operative fluoroscopic 2D-imaging and postoperative CT-scan

	Intraoperative 2D FLUOROSCOPY			Scoring panel 2D FLUOROSCOPY		
	ICC 3-items [95% CI]	N=74	Not judgeable 2D/CT	ICC 3-items [95% CI]	N=74	Not judgeable 2D/CT
Böhler's angle	-0.01 [-0.15-0.16]	71	0/2	0.20 [-0.05-0.42]	58	6/2
Gissane's angle	0.18 [-0.03-0.38]	71	0/2	0.19 [-0.06-0.43]	58	6/2
Length of the calcaneus	0.19 [-0.02-0.39]	73	0/0	0.53 [0.32-0.69]	61	5/0
Varus/varus of the tuber	0.06 [-0.16-0.28]	73	0/0	0.68 [0.42-0.83]	29	37/0
CC-joint	0.04 [-0.15-0.24]	73	0/0	0.04 [-0.15-0.24]	65	1/0
PTC-joint	0.22 [-0.03-0.44]	73	0/0	0.19 [-0.06-0.42]	65	1/0
ATC-joint	0.15 [-0.05-0.35]	72	1/0	0.12 [-0.07-0.32]	65	1/0
Overall quality of reduction	0.07 [-0.09-0.24]	70	1/2	0.11 [-0.07-0.31]	64	8/1
Position of fixation plate	0.23 [0.02-0.43]	72	1/0	0.22 [-0.02-0.43]	64	2/0
Grip of screws in sustentaculum	0.36 [0.13-0.55]	72	1/0	0.03[-0.16-0.23]	63	3/0
Intra-articular screws	0.00 [-0.19-0.21]	73	0/0	0.05 [-0.19-0.29]	66	1/0
Medial protrusion screws	-0.17 [-0.38-0.05]	73	0/0	0.07 [-0.14-0.29]	62	4/0
Overall quality of implant position	0.20 [-0.02-0.41]	72	1/0	0.16 [-0.08-0.39]	64	5/0
Overall quality of ORIF	0.12 [-0.07-0.32]	70	2/2	0.02 [-0.09-0.16]	54	10/1
Overall revision required				0.09 [-0.11-0.29]	66	0/0

Cut-offs are as provided by Cicchetti et al., with reliability being 'poor' for ICC values less than 0.40, 'fair' for values between 0.40 and 0.59, 'good' for values between 0.60 and 0.74, and 'excellent' for values between 0.75 and 1.0 were used



Intraclass correlation of intra-operative fluoroscopic 3D-imaging with computed tomography

The ICC of the fracture reduction as judged by the scoring panel, as well as intra-operatively, was 'fair', except for the evaluation of the CC-joint, which was 'moderate' (Table 2). The scoring panel scored the position of the fixation plate and intra-articular screws as 'good'. Correct screw positioning in the sustentaculum and tuber and medial protrusion of screws showed a 'moderate' correlation with CT. Overall quality of implant position evaluated by the scoring panel had a 'moderate' ICC and overall quality of reduction and implant position also score 'moderate'. The requirement of a revision had a 'fair' correlation with CT-images.

Image quality

Both the surgeon's intra-operative evaluation and the evaluation of the scoring panel of image quality, scattering and interpretability of 2D-imaging was considered 'good' in more than 90% of the images. As for 3D-imaging the intra-operative evaluation differed from the blinded evaluation by the scoring panel. Scattering was considered more of an issue for the scoring panel (11%) than intra-operatively for the surgeons (2%): the surgeons scored image quality in 85% as 'good' versus only 18% by the scoring panel. Interpretability of CT-images were rated 'good' in 92% of cases versus only 22% for the 3D-images.

Table 2: Intraclass correlation coefficient of intra-operative fluoroscopic 3D-imaging and postoperative CT-scan

	Intraoperative 3D FLUOROSCOPY			Scoring panel 3D FLUOROSCOPY		
	ICC 3-items [95% CI]	N=50	Not judgeable 2D/CT	ICC 3-items [95% CI]	N=95	Not judgeable 2D/CT
Böhler's angle	0.10 [-0.11-0.33]	46	2/1	0.36 [0.16-0.52]	91	2/2
Gissane's angle	0.16 [-0.08-0.40]	46	2/1	0.31 [0.11-0.48]	91	1/2
Length of the calcaneus	-0.04 [-0.24-0.19]	47	2/0	0.16 [-0.04-0.35]	93	2/0
Varus/varus of the tuber	-0.06 [-0.33-0.23]	47	2/0	0.06 [-0.14-0.26]	93	2/0
CC-joint	0.42 [0.16-0.63]	46	3/0	0.40 [0.21-0.56]	92	3/0
PTC-joint	0.19 [-0.08-0.45]	47	2/0	0.39 [0.10-0.60]	93	1/0
ATC-joint	0.26 [-0.02-0.50]	47	2/0	0.08 [-0.07-0.25]	94	0/0
Overall quality of reduction	0.22 [-0.07-0.49]	46	2/1	0.35 [0.00-0.59]	91	2/2
Position of fixation plate	0.37 [0.10-0.59]	46	2/1	0.68 [0.55-0.78]	92	1/1
Grip of screws in sustentaculum	0.18 [-0.07-0.43]	46	3/0	0.42 [0.24-0.57]	92	2/0
Intra-articular screws	0.15 [-0.12-0.41]	46	2/0	0.66 [0.53-0.76]	93	1/0
Medial protrusion screws	0.25 [-0.02-0.49]	47	2/0	0.51 [0.34-0.64]	92	2/0
Overall quality of implant position	0.30 [0.01-0.54]	46	2/0	0.48 [0.31-0.63]	93	1/0
Overall quality of ORIF	0.19 [-0.09-0.46]	45	2/1	0.37 [0.09-0.58]	89	1/4
Overall revision required				0.27 [0.08-0.44]	66	0/0

Cut-offs are as provided by Cicchetti et al., with reliability being 'poor' for ICC values less than 0.40, 'fair' for values between 0.40 and 0.59, 'good' for values between 0.60 and 0.74, and 'excellent' for values between 0.75 and 1.0 were used.

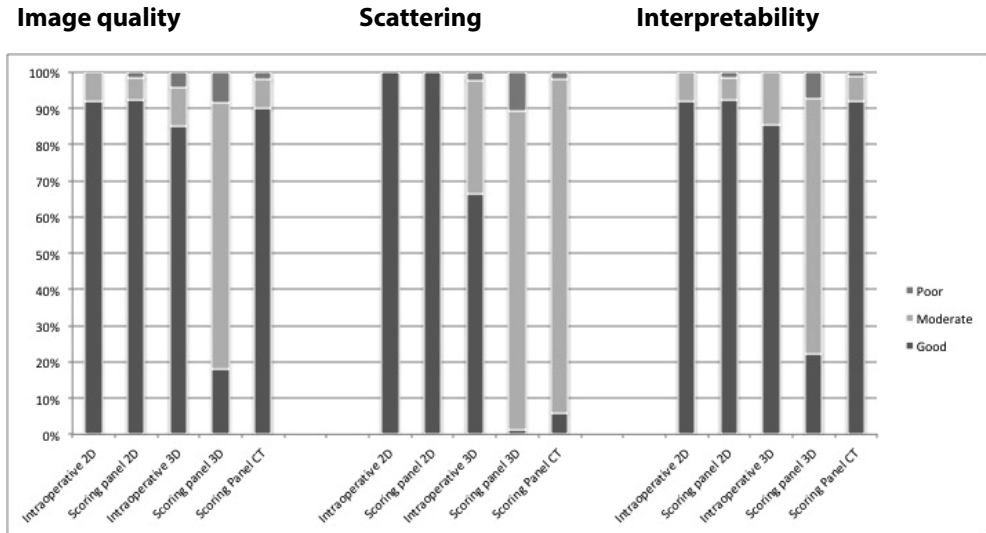


Figure 4: Subjective image quality

Intraoperative 2D: Intra-operative evaluation of 2D-fluoroscopy by the operating surgeon

Scoring panel 2D: Consensus of evaluation of 2D-fluoroscopy by the scoring panel

Intraoperative 3D: Intra-operative of 3D-fluoroscopy by the operating surgeon

Scoring panel 3D: Consensus of evaluation of 3D-fluoroscopy by the scoring panel

Scoring panel CT: Consensus of evaluation of the CT-scan by the scoring panel

Discussion

In this study, we found a poor to good correlation between intra-operative evaluation of 2D- and 3D-imaging and the post-operative CT as to fracture reduction and fixation. The scoring panel showed an acceptable intraclass correlation for two reduction items (length and position of the tuber) of 2D-imaging and all items regarding fixation of 3D-imaging.

Image quality, scattering and interpretability of intra-operative fluoroscopic 2D-imaging was valued even higher than the CT-scan as current reference standard. The image quality of 3D-fluoroscopic imaging was lowest with a large difference between the intra-operative evaluation and the scoring panel. In contrast, agreement for the quality of reduction was better, although still fair, and still better for fixation.

Similar to previously reported results from Euler et al. and Wirth et al. about image quality, 2D-imaging was valued best on image quality, scattering and interpretability of images.^{7,19,20} Probably, intra-operative evaluation of the image quality was higher due to the additional information the surgeon had at hand (e.g. evaluation of pre-operative imaging, direct sight of the fracture fragments). This could have lowered the surgeons' demands of the interpretability and quality of the images available.



Ideally, to determine diagnostic accuracy of intra-operative 2D- and 3D-imaging, sensitivity and specificity should be calculated. In order to calculate these, a binary evaluation of the reduction and implant position is required (e.g. acceptable or not acceptable). In case of only two fracture fragments or one implant a binary evaluation is feasible. However, in case of a comminute fracture with multiple implants there are more nuances, with a grey area in which reduction and/or implant position might not be perfectly anatomical but acceptable, and no need for revision. Therefore, we used a scoring system with a 3-point Likert scale for the postoperative evaluation of reduction and fixation, to reflect the evaluation of fracture reduction and fixation in clinical practice.¹⁵

Intraclass correlation between the evaluation of intra-operative fluoroscopic images and the postoperative CT-evaluation was better for the scoring panel than the operating surgeons. A reason for this could be that the scoring panel performed the evaluation of the 3D-images and the CT-evaluation, while the operating surgeons only performed evaluation of the 3D-images. Thus, in case of the operating surgeons only inter-observer variation could have played a role, whereas in the scoring panel also intra-observer variance could have been a contributing factor.¹⁵

Although cadaver studies showed a sensitivity of 81-100% and specificity of 80-99%, we found only fair agreements for most of the evaluated items.⁷⁻¹¹ Clinical practice seems more intricate than a cadaver setting. The clinical study from Kendoff et al. showed that, even though intra-operative 3D-imaging was used, in 4% of the patients revision surgery was performed due to a clinically important malreduction or implant misplacement visible on the postoperative CT-scan.²¹ The authors concluded that the inconsistency between the intra-operative 3D-images and postoperative CT-scan was mainly the result of poor 3D image quality due to scattering of the implants. In the current study, 62% of the fractures were Sanders type III-IV requiring a plate with multiple screws. The subsequent scattering probably lowered the image quality, resulting in a lower correlation between 3D imaging and CT-scanning. However, this probably reflects the actual accuracy of intra-operative 3D imaging in clinical practice. For CT-scanning metal artefact reduction techniques have been introduced, but during this study these techniques were not available.

Only one comparative study of 3D-C-arms has been performed, comparing the Iso-C-3D (Siemens) and the Vario 3D (Ziehm).²² As this was a cadaver study, a reliable comparison with the diagnostic performance of the BV Pulsera (Philips) used in this clinical trial is not possible.

Ideally, for the calculation of intra-observer agreement outcomes should be more or less equally divided among the outcomes. However, in this study, only 19% of the reductions were not acceptable and implant position was misplaced in 26%, divided over the different scoring items. When compared to the postoperative CT-scan, the intra-operative 3D images showed a better correlation in terms of evaluating implant positioning than the evaluation of fracture reduction. This could explain a low correlation, as well as a lower correlation for the reduction items than for the fixation items.

This is the first study describing the correlation between intra-operative 3D imaging and postoperative CT-evaluation of calcaneal fractures of both reduction and implant position

in a clinical setting. Even though this study is a good reflection of clinical practice, this setting also has limitations. Because it is unethical not to strive for the best reduction and fixation possible it is very difficult to obtain variety in the quality of reduction and fixation on every item in this CT-based scoring protocol. On the other hand, these types of multifragmentary fractures are difficult to mimic in a cadaver setting. In addition, the operating surgeons and scoring panel were asked to give their overall opinion of the different fragments within one joint. Hence, they could have different opinions about which fragment dominated their judgement.


Imaging and software techniques develop rapidly, and future research should aim to adequately compare the diagnostic accuracy of intra-operative imaging devices in a clinical setting. Furthermore, in order to compare imaging devices, a further development and evaluation of the scoring protocol is necessary to determine which of the items truly predict clinical outcome and whether the current thresholds of intra-articular gaps and step-offs of 2 mm are clinically feasible and relevant in the various fracture types.

In conclusion, implant position can be evaluated satisfactory with the aid of intra-operative 3D-imaging. Although 3D-imaging showed a better agreement than 2D-imaging, there is a need to improve image quality and suppress scattering from implants to improve the correlation in the evaluation of fracture reduction. Moreover, because minimally invasive approaches have become more popular,²³ intra-operative imaging is a necessity for adequate reduction and fixation.

References

1. Schepers T., Ginai A.Z., Mulder P.G.H., et al. Radiographic evaluation of calcaneal fractures: To measure or not to measure. *Skeletal Radiology* 2007; 36: 847-52.
2. David V., Stephens T.J., Kindl R., et al. Calcaneotalar Ratio: A New Concept in the Estimation of the Length of the Calcaneus. *The Journal of Foot and Ankle Surgery* 2015; 54: 370-2.
3. Swords M.P., Alton T.B., Holt S., et al. Prognostic value of computed tomography classification systems for intra-articular calcaneus fractures. *Foot & Ankle International* 2014; 35: 975-80.
4. Kurozumi T., Jinno Y., Sato T., et al. Open reduction for intra-articular calcaneal fractures: evaluation using computed tomography. *Foot & Ankle International* 2003; 24: 942-8.
5. Gupta A., Ghalambor N., Nihal A., et al. The modified Palmer lateral approach for calcaneal fractures: Wound healing and postoperative computed tomographic evaluation of fracture reduction. *Foot & Ankle International* 2003; 24: 744-53.
6. Janzen D.L., Munk P.L., Buckle R.E., et al. Intraarticular fractures of the calcaneus: Value of CT findings in determining prognosis. *American Journal of Roentgenology* 1992; 158: 1271-4
7. Beerekamp M.S.H., Sulkers G.S., Ubbink D.T., et al. Accuracy and consequences of 3D-fluoroscopy in upper and lower extremity fracture treatment: a systematic review. *European Journal of Radiology* 2012; 81: 4019-28.
8. Franke J., Wendl K., Suda A.J., et al. Intraoperative three-dimensional imaging in the treatment of calcaneal fractures. *The Journal of Bone and Joint Surgery (American Volume)* 2014; 96: e72.
9. Kendoff D., Citak M., Gardner M., et al. Three-dimensional fluoroscopy for evaluation of articular reduction and screw placement in calcaneal fractures. *Foot & Ankle International* 2007; 28: 1165-71.
10. Kotsianos D., Wirth S., Fischer T., et al. 3D imaging with an isocentric mobile C-arm comparison of image quality with spiral CT. *European Radiology* 2004; 14: 1590-5.
11. Rock C., Linsenmaier U., Brandl R., et al. Introduction of a new mobile C-arm/CT combination equipment (ISO-C-3D). Initial results of 3-D sectional imaging. *Unfallchirurg* 2001; 104: 827-33.
12. Whiting P., Rutjes A.W.S., Reitsma J.B., et al. The development of QUADAS: a tool for the quality assessment of studies of diagnostic accuracy included in systematic reviews. *BMC Medical Research Methodology* 2003; 3: 25.
13. Beerekamp M.S.H., Ubbink D.T., Maas M., et al. Fracture surgery of the extremities with the intra-operative use of 3D-RX: a randomized multicenter trial (EF3X-trial). *BMC Musculoskeletal Disorders* 2011; 12: 151.
14. Beerekamp M.S.H., Luitse J.S.K., Ubbink D.T., et al. Evaluation of reduction and fixation of calcaneal fractures: A Delphi consensus. *Archives of Orthopaedic Trauma Surgery* 2013; 133: 1377-84.

15. de Muinck Keizer R.J.O., Beerekamp M.S.H., Ubbink D.T., et al. Systematic CT evaluation of reduction and hardware positioning of surgically treated calcaneal fractures: A reliability analysis. *Archives of Orthopaedic Trauma Surgery* 2017; 137: 1261-7.
16. Veltman E.S., van den Bekerom M.P., Doornberg J.N., et al. Three-dimensional computed tomography is not indicated for the classification and characterization of calcaneal fractures. *Injury* 2014; 45: 1117-20.
17. Hallgren K.A. Computing inter-rater reliability for observational data: An overview and tutorial. *Tutorials in Quantitative Methods for Psychology* 2012; 8: 23-34.
18. Cicchetti D.V. Multiple comparison methods: establishing guidelines for their valid application in neuropsychological research. *Journal of Clinical and Experimental Neuropsychology* 1994; 16: 155-61.
19. Euler E., Wirth S., Linsenmaier U., et al. Comparative study of the quality of C-arm based 3D imaging of the talus. *Unfallchirurg* 2001; 104: 839-46.
20. Wirth S., Euler E., Linsenmaier U., et al. C-arm-based mobile computed tomography: A comparison with established imaging on the basis of simulated treatments of talus neck fractures in a cadaveric study. *Computer Aided Surgery* 2004; 9: 27-38.
21. Kendoff D., Citak M., Gardner M.J., et al. Intraoperative 3D imaging: Value and consequences in 248 cases. *The Journal of Trauma* 2009; 66: 232-8.
22. Stübig T., Kendoff D., Citak M., et al. Comparative study of different intraoperative 3-D image intensifiers in orthopedic trauma care. *The Journal of Trauma* 2009; 66: 821-30.
23. Bai L., Hou Y.L., Lin G.H., et al. Sinus tarsi approach (STA) versus extensile lateral approach (ELA) for treatment of closed displaced intra-articular calcaneal fractures (DIACF): A meta-analysis. *Orthopaedics and Traumatology, Surgery and Research* 2018; 104: 239-44.



Thesis summary
General discussion and future perspectives

Nederlandse samenvatting
Algemene discussie en toekomstperspectieven

Thesis summary

To maximize success of operatively treated intra-articular fractures, optimal visualization of the fracture fragments and implant position during fracture reduction and fixation is essential. Preferably, reduction and fixation are performed with minimal soft tissue injury.¹ The continuous introduction of new techniques enabling surgeons to improve the quality of fracture reduction and fixation often seems promising. However, these new techniques require critical evaluation to assess whether they actually improve fracture care. This thesis focused on a critical evaluation of intra-operative 3D-imaging in extremity fracture surgery. Intra-operative 3D-imaging potentially enables the surgeon to improve the quality of fracture reduction and fixation of intra-articular fractures. Epidemiologic data of extremity fractures were updated in order to provide insight into the number of fractures this new technique could potentially be applied to. Furthermore, to evaluate the effectiveness of intra-operative 3D-imaging, qualification of the radiological anatomical reduction and fixation in a scoring protocol was necessary. This scoring protocol enabled the comparison of the quality of the reduction and fixation.

In **Chapter 1**, epidemiologic data showed a growing and ageing population and a general increase in incidence of extremity fractures between 2004 and 2012. Additionally, a shift towards non-university hospitals was seen for patient presentations to the emergency department and definitive operative treatment. If these trends continue, this number is only expected to increase resulting in an equally growing burden on societal costs of extremity fractures. Therefore, policy makers should be advised to pro-actively adjust capacity and resources and invest in techniques aiding in optimizing fracture reduction and fixation.

Part 1 - The radiologic evaluation of reduction and fixation of extremity fractures

Based on literature data and experience of orthopedic and trauma surgeons as well as radiologists an online questionnaire was composed to identify the most important radiological criteria for evaluation of reduction and fixation. For the wrist and ankle, group consensus amongst Dutch clinical experts was obtained following the Delphi method, as described in **Chapter 2**. Experts agreed on a conventional posterior-anterior (PA) and lateral view of the wrist in the standard pre-operative radiological work-up. For pre- and postoperative CT-scanning no consensus was reached. Consensus was reached on the need to evaluate the congruency of the wrist joint (width and symmetry of joint spaces and configuration of the carpal bones) as well as the ulnar variance, dorsal angulation, distal radial ulnar joint (DRUJ) distance, position of the carpal bones and their relation to each other. For fracture reduction and fixation, the absence of intra-articular steps, gaps and bone fragments should be evaluated, in addition to the position of the fixation plate(s), the implant length and absence of intra-articular protrusion of screws or other implants. No consensus could be reached whether radiological items should be measured or could be evaluated by visual assessment.

The only consensus obtained for the pre-operative radiological work up for the ankle was a conventional lateral view, though most experts (79%) preferred an additional Mortise view. The experts' opinions diverged regarding standard pre- and postoperative CT-scanning.

Consensus was reached that the radiological evaluation of the ankle could be performed visually. The evaluation of the anatomy of the ankle should consist of assessment of the congruency of the ankle, symmetry and width of the joint space, the distance of the tibia and fibula at the syndesmosis and length and rotation of the fibula. Assessment of the absence of intra-articular steps, gaps and bone fragments, the position of fixation plates and other implants, bicortical screw length and absence of intra-articular protrusion of implants should be part of the evaluation of the reduction and fixation of the ankle.

In **Chapter 3**, group consensus for the radiological evaluation of the calcaneus was reached with an international clinical expert panel. Pre- and postoperative imaging requires at least conventional radiography with a lateral projection of the ankle and an axial projection of the calcaneus. For pre-operative planning a CT-scan is required with triplanar reconstructions. Intra-operative imaging should consist of a lateral view, axial view and Brodén view. Evaluation of anatomical landmarks should include congruency of the calcano-cuboid (CC), posterior talo-calcaneal (PTC) and anterior talo-calcaneal (ATC) joint; Böhler's angle, Gissane's angle and the position of the tuber calcanei. For reduction and fixation presence of steps and gaps in the CC-joint, PTC-joint and anterior process need to be evaluated. The acceptable threshold for steps and gaps is ≤ 2 mm. Furthermore, the absence of bone fragments in the CC-joint, ATC-joint and PTC-joint should be assessed. Implant position should be evaluated in regard of correctness of plate position and the sustentacular screw. The absence of protruding implants in the CC-joint, ATC-joint, PTC-joint, the medial wall and the tuber calcanei are also part of the evaluation of the quality of fixation.

Based on the international consensus a 23-item scoring protocol was introduced to systematically evaluate the quality of reduction and fixation of surgical treatment of calcaneal fractures. Validation of this scoring protocol is described in **Chapter 4**. Three independent raters scored the quality of reduction and implant position based on the blinded postoperative CT-scan of 102 calcaneal fractures according to the scoring protocol. After a month's interval, the raters scored a selected series of 25 fractures again. Overall, inter-rater reliability over the 23-items was good (ICC 0.66; 95% CI 0.64-0.69). Intra-rater reliability was good for all three raters individually with ICC's between 0.60 and 0.70.

Part 2 - Intra-operative 3D-imaging in extremity fracture surgery

Promising results were published after the introduction of intra-operative 3D-imaging. Cadaver studies showed a diagnostic accuracy comparable to CT scanning.²⁻¹⁰ Extra corrections were deemed necessary after 3D-imaging which would not have been recognized on 2D-imaging in clinical studies.¹¹⁻¹⁸ To obtain a broader perspective on the performance in terms of diagnostic accuracy, subjective image quality and clinical consequences of intra-operative 3D-imaging in extremity fractures, we performed a systematic review of the literature in **Chapter 5**. In this review MEDLINE, EMBASE and the Cochrane Central Register of Controlled trials (up to March 2012) were screened systematically. Eventually, we found 19 eligible articles of which 10 were cadaver studies and 9 clinical studies. Unfortunately, due to heterogeneity of the reported outcomes and incomplete data reporting no meta-analysis could be performed to determine the diagnostic accuracy. Diagnostic accuracy of intra-operative 3D-imaging appears to be

higher than 2D-fluoroscopy and X-ray and similar to CT-scanning for both reduction and implant position. In contrast, subjective image quality of 3D-imaging was scored inferior to all other imaging modalities. Additional intra-operative corrections after 3D-fluoroscopy were performed in 11-40% of the procedures with respectively 2-40% corrections in reduction and 6-26% in fixation or a combination of both in 3-8%. To conclude, intra-operative 3D-imaging is a promising diagnostic tool to facilitate optimal fracture reduction and fixation of extremity fractures.

To evaluate these promising clinical results for calcaneal fractures a before-after study was performed in **Chapter 6** assessing the effects of intra-operative use of 3D-imaging on intra-operative corrections, peri-operative imaging used, and patient-relevant outcomes compared to 2D-imaging alone. In total, 231 patients were included between 2000 and 2014 of which 46% was operated with the use of 3D-imaging. Operating time increased significantly with a median of 14 minutes when using 3D-imaging. Additional corrections after 3D-imaging were performed in 53% of the surgical procedures of which 96% were corrections of implant position. Concomitantly, a decrease in the number of corrections after 2D-imaging of 15% was seen when 3D-imaging was available. No differences were found in patient relevant outcomes or peri-operative imaging. Although this study confirms additional corrections after 3D-imaging no patient-related benefits could be established.

In **Chapter 7** we describe the protocol for a multicenter randomized clinical trial to investigate the clinical effect of intra-operative 3D imaging of articular fractures of the wrist, ankle and calcaneus: The **Extremity Fractures with intra-operative 3D-RX** trial (EF3X-trial). In this trial patients with a traumatic intra-articular fracture of the wrist, ankle or calcaneus were allocated to one of the two study-arms. Randomization determined whether or not the information of the 3D-scan, performed after reduction and fixation, was available to the operating surgeon. This study design was chosen to exclude changes in the surgeons' attitude towards 2D-imaging and therefore truly extricate the added value of intra-operative 3D-imaging in terms of quality of fracture reduction and fixation and patient reported outcomes.

The outcomes for calcaneal fractures of the EF3X-trial are reported in **Chapter 8**. A total of 102 operatively treated calcaneal fractures of 100 patients were randomized. Operating time increased significantly with the use of intra-operative 3D-imaging. However, no improvement of the quality of reduction and fixation could be detected. Also, no benefit of intra-operative 3D-imaging could be found regarding postoperative complications, quality of life, functional outcome or post-traumatic osteoarthritis.

The correlation between the evaluation of the 3D-images and the postoperative CT-scan is sufficient for implant position as is described in **Chapter 9**. The correlation between the evaluation of intra-operative 3D-imaging and CT-scanning of fracture reduction is fair. For 2D-imaging correlation with the postoperative CT-scan is fair for all items except the evaluation of the tuber calcanei. Subjective image quality of 3D-imaging was appreciated lowest compared to 2D-imaging and CT-scanning. Hence, there is a need to further

improve image quality and scatter suppression of 3D-imaging to improve the correlation with CT-scanning as reference standard.

General discussion & future perspectives

The aim of this thesis was to explore whether quality of fracture reduction and fixation of intra-articular extremity fractures, especially calcaneal fractures, can be improved by using intra-operative 3D-imaging. To be able to define the quality of fracture reduction and fixation, radiological scoring protocols were developed for the wrist, ankle and calcaneus and the latter was validated. Because of promising results of additional corrections performed after intra-operative 3D-imaging, we expected an improvement of the quality of fracture reduction and fixation, resulting in a better patient outcome.

In our studies, additional corrections were performed after intra-operative 3D-imaging. However, for calcaneal fractures, no clinical effect in terms of improvement in the quality of reduction and fixation, re-operations and patient reported outcomes was seen. This discrepancy with our expected results could have several explanations.

First, we could have overestimated the number of additional corrections that were performed. We saw a change in the surgeons' attitude towards intra-operative 2D-imaging when 3D-imaging was available. A drop of 15% was seen in the number of corrections performed after 2D-imaging when additional 3D-imaging was used.

In addition, during the 30 second 200° rotation of the C-arm, yielding 225 images, the images were shown live. The multiplanar reconstructions were available approximately three minutes after the run. The live 2D-images of the run already provided additional information instantly for both the evaluation of reduction and fixation. Consequently, this led to a more dynamic use of continuous 2D-imaging mimicking the information of the rotation of the C-arm.

In the past decade the use of peri-operative imaging has changed profoundly. The use of pre- and postoperative CT-scanning was still limited a decade ago. In the Delphi consensus, our expert panel pointed out that no post-operative CT-scans were necessary in the standard radiological evaluation. Nowadays, CT-scanning has become more widely available and indications for both pre- and postoperative CT-scanning have been extended in the standard evaluation of intra-articular fractures. Post-operative CT-scanning has given more insight into the quality of fracture reduction and fixation, and showed us more and larger steps, gaps and insufficient or protruding implant positions than expected based on conventional X-rays. This insight has led to increasing dynamical use of 2D-imaging and the use of additional 2D-projections. Possibly this could have led to a decrease in additional value of intra-operative 3D-imaging.

Sample size calculation of the EF3X-trial was based on retrospective data evaluating postoperative radiographs of extremity fractures alone as described in **Chapter 7**. These data showed inadequate reduction and/or fixation in 17% of the operated extremity fractures using intra-operative 2D-imaging. However, the postoperative CT-scans of the calcaneal fractures in the EF3X-trial showed an even higher percentage of revisions

required postoperatively of 59.6-69.4% in both groups. An explanation for this difference is that the quality of reduction and fixation based on radiographs is overestimated compared to CT-scanning. Another factor in this study could be the scoring protocol we used. We evaluated 23 items of reduction and fixation of calcaneal fractures. When scoring to such an extensive degree instead of solely focusing on e.g. the joint surface, it is more likely to find indications for improvement. Most importantly, the evaluation of our CT images was done outside of the operating theatre. Consequently, raters were not hampered by the reality of operative challenges. This could have created a lower threshold for seeing indications for improvement. Actual revision operations due to inadequate reduction and/or fixation were only performed in 2% in both randomization groups.

The hypothesized effect of 5% malreduced fractures or incorrect implant position when using intra-operative 3D-imaging was based on the study of Kendoff et al. In this study, revision operations were performed in 4% of 129 patients with various extremity fractures operated with intra-operative 3D-imaging.¹⁶ The need for revisions was based on postoperative CT-scanning because of an articular step-off (> 2mm), gap (> 2mm) or intra-articular implant protrusion. No studies could be found describing the quality of fracture reduction extensively.

Calcaneal fractures could be considered a different entity because of the multiple articulations and shape of the calcaneus. Therefore, in hindsight, it is questionable how representative the findings of our study and that of Kendoff et al. were for calcaneal fractures. However, at the time, it was the best available evidence for our sample size calculation.

The EF3X-trial was primarily designed to determine the clinical effectiveness of the use of intra-operative 3D-imaging in addition to intra-operative 2D-imaging. The secondary aim was to determine the diagnostic performance in a clinical setting. To truly investigate the additional value of 3D-imaging we chose to allow the surgeon to perform a 3D-scan only after he was satisfied with the reduction and fixation based on intra-operative 2D-imaging. In our retrospective study we saw that the availability of intra-operative 3D-imaging unconsciously changed the surgeons' attitude towards intra-operative 2D-imaging. However, this design also increased the threshold to revise malreduced fracture fragments. At the end of the procedure, the surgeon needs to weigh the expected benefits of revising both reduction and the definitive fixation versus the disadvantages. Disadvantages like prolonged operating time could be reduced when reduction of fracture fragments is evaluated after temporary fixation. In addition, temporary fixation mostly gives less scattering than definitive implants and is expected to allow for better evaluation of the reduction. A more pragmatic design with free use of 3D-imaging could potentially show more benefits. It would however not truly investigate the added value. On the other hand, in a pragmatic design the average radiation dose per patient can be calculated and valued against the profit gained from the quality improvement of fracture reduction and fixation.

Patient recruitment for the EF3X-trial proved to be more difficult than anticipated. Causes could be an overestimation of patients presenting with a calcaneal fracture and a higher number of exclusions than anticipated. Due to concentration of patient care, the large

majority of patients with a calcaneal fracture was included by the coordinating center. The patient population with calcaneal fractures is known for their frequent psychiatric comorbidities and eligibility of patients was lower than expected. Eventually, after 4 years the patient inclusion had to be terminated due to logistical and financial factors, long before the calculated volume of 250 patients was reached. However, the current conclusions are not expected to change with more patients included.

For calcaneal fractures, there is evidence that anatomic reduction and fixation restoring the calcaneal shape and joint congruity leads to acceptable functional outcomes. In both biomechanical and clinical studies, differences in outcome were seen with steps ≥ 2 mm and gaps ≥ 3 mm in the posterior talocalcaneal joint.¹⁹⁻²² For calcaneal shape, restoration of Böhler's angle and heel width are associated with better clinical outcome.²³⁻²⁵ However, perfect anatomical reduction and fixation is not always achievable due to fracture instability, decreased bone quality and poor soft tissue condition. Additionally, anatomical reduction and fixation is not the sole predictor of clinical outcome. Damage during injury, both to the bone and to the cartilage, seems to be an important predictor of a patients' functional outcome, as Sanders et al. showed a correlation with the Sanders fracture classification.²⁶ Moreover, patient related factors like comorbidities and substance abuse are important factors influencing functional outcome.²⁷ Furthermore, developments in minimally invasive fracture approach have shown a decrease in infection rate. When using the sinus tarsi approach, infection rate is only 2.9-4.1% compared to an infection rate of 14.4-21.2% with the extended lateral approach (ELA).^{28,29} A subsequent decrease in infection rate led to better functional results.

Patient-related outcomes for calcaneal fracture surgery do not solely depend on the radiological outcome of fracture reduction and fixation. Both patient and fracture selection as well as operating technique are of importance. How these different factors need to be weighed and to which extent anatomical fracture reduction and fixation has to be pursued in order to provide a tailor-made treatment for each patient has to be further elucidated.

Intra-operative revisions can be performed to a certain extent as residual bone stock diminishes by each drilling hole and infection rate increases due to prolonged operating time. Intra-operative 3D-imaging is mostly performed at the end of an operation and the expected benefit of revisions needs to be weighed against the disadvantages. Pre-operative planning is essential to reduce the number of revisions during surgery. Currently pre-operative planning is done theoretically and based on the pre-operative CT-scan with the possibility of volume rendering. In daily clinical practice 3D-printing has become available and has proven to be accurate in the reproduction of joints and fractures.³⁰ 3D-printing of the fractured bone allows the surgeon to simulate fracture reduction as well as the impact of the choice of implant type and its positioning in advance of the surgery. Additionally, the contralateral bone can be printed and act as a model. This allows for pre-operative management of any practical difficulties that may be encountered and consequent adjustment of planning. Some studies have shown that pre-operative simulation with 3D-printed models leads to a shorter operating time, a decrease in blood loss, a diminished fluoroscopy time and better anatomical reduction and fixation.^{31,32}

Furthermore these fracture models can help in patient communication to explain the operation and manage expectations about functional outcome.^{31,32}

Augmented reality is another technique becoming more widely available. This technique can be used for freehand locking of intramedullary nails, reducing operating time compared to the use 2D-fluoroscopy.³³ It also provides the opportunity to construct a detailed digital operating plan pre-operatively. This digital plan can be projected onto the patient intra-operatively in order to help the surgeon reduce all fracture fragments in the correct order and accurately place the implants in the predetermined position.³⁴

The use of intra-operative 3D-imaging in its current form did not lead to better patient outcomes in calcaneal fractures in our studies. However, there are no indications that intra-operative 3D-imaging negatively influenced patient outcome, except for the relatively low extra radiation dose. In simple fractures with a limited number of implants, some residual steps- and/or gaps or protruding implants can be detected intra-operatively after 3D-imaging. For the more complex fractures that require multiple implants, 3D-imaging requires further development. Therefore, intra-operative 3D-imaging should not be used as standard in daily practice yet. The potential of this technique is worth further exploration and may be of value in other fracture types or in future developments like 3D-navigation or augmented reality. Other new and promising techniques are queueing up to be further explored, which may continue to improve patient outcome. However, all these techniques require critical evaluation to determine the actual patient benefit and prevent them from being used merely as 'toys for the boys (and girls)'.

References

1. Buckley R., Moran C.G., Apivatthakakul T. AO Principles of fracture treatment. *Thieme Medical Publishers, 01/2011, 2018.*
2. Euler E., Wirth S., Linsenmaier U., et al. Comparative study of the quality of C-arm based 3D imaging of the talus. *Unfallchirurg* 2001; 104: 839–46.
3. Gössling, T., Klingler K., Geerling J., et al. Improved intra-operative reduction control using a three-dimensional mobile image intensifier - A proximal tibia cadaver study. *The Knee* 2009; 16: 58–63.
4. Kendoff D., Citak M., Gardner M., et al. Three-dimensional fluoroscopy for evaluation of articular reduction and screw placement in calcaneal fractures. *Foot & Ankle International* 2007; 28: 1165–71.
5. Linsenmaier U., Rock C., Euler E., et al. Three-dimensional CT with a modified C-arm image intensifier: Feasibility. *Radiology* 2002; 224: 286–92.
6. Weil Y.A., Liebergall M, Mosheiff R., et al. Assessment of two 3-D fluoroscopic systems for articular fracture reduction: A cadaver study. *International Journal of Computer Assisted Radiology and Surgery* 2011; 6: 685–92.
7. Wirth S., Euler E., Linsenmaier U., et al. C-arm-based mobile computed tomography: A comparison with established imaging on the basis of simulated treatments of talus neck fractures in a cadaveric study. *Computer Aided Surgery* 2004; 9: 27–38.
8. Kotsianos D., Wirth S., Fischer T., et al. 3D imaging with an isocentric mobile C-arm comparison of image quality with spiral CT. *European Radiology* 2004; 14: 1590–5.
9. Khoury A., Siewerdsen J.H., Whyne C.M., et al. Intraoperative cone-beam CT for image-guided tibial plateau fracture reduction. *Computer Aided Surgery* 2007; 12: 195–207.
10. Meier R., Geerling J., Hüfner T., et al. The isocentric C-arm. Visualization of fracture reduction and screw position in the radius. *Unfallchirurg* 2011; 114: 587–90.
11. Ruan Z., Luo C., Feng D., et al. Intraoperative three-dimensional imaging in tibial plateau fractures with complex depressions. *Technology and Health Care* 2011; 19: 71–7.
12. Khoury A., Atesok K., Liebergall M., et al. The role of ISO-C3D in crush injuries to the distal lower syndesmosis. *Current Orthopaedic Practice* 2011; 22: 167–170.
13. Rübberdt A., Feil R., Stengel D., et al. The clinical use of the ISO-C(3D) imaging system in calcaneus fracture surgery. *Unfallchirurg* 2006; 109: 112–8.
14. Queitsch C., Schulz A.P., Haustedt N., et al. Improved therapy of calcaneal fractures by intraoperative 3D-fluoroscopy and locked-screw plate fixation. *European Journal of Trauma* 2006; 32: 471–476.
15. Geerling J., Kendoff D., Citak M., et al. Intraoperative 3D imaging in calcaneal fracture care-clinical implications and decision making. *The Journal of Trauma* 2009; 66: 768–73.
16. Kendoff D., Citak M., Gardner M.J., et al. Intraoperative 3D imaging: Value and consequences in 248 cases. *The Journal of Trauma* 2009; 66: 232–8.

Thesis summary

17. Atesok K., Finkelstein J., Khoury A., et al. The use of intraoperative three-dimensional imaging (ISO-C-3D) in fixation of intraarticular fractures. *Injury* 2007; 38: 1163–9.
18. Beerekamp M.S.H., Haverlag, R., Luitse J.S.K., et al. Het peroperatieve gebruik van 3D-beeldvorming bij fracturen aan de extremiteiten. *Nederlands Tijdschrift voor Traumachirurgie* 2011; 1: 2–8.
19. Rammelt S., Sangeorzan B.J., Swords M.P. Calcaneal Fractures - Should we or should we not operate? *Indian Journal of Orthopaedics* 2018; 52: 220–230.
20. Mulcahy D.M., McCormack D.M., Stephens M.M. Intra-articular calcaneal fractures: Effect of open reduction and internal fixation on the contact characteristics of the subtalar joint. *Foot & Ankle International* 1998; 19: 842–8.
21. Sangeorzan B.J., Ananthkrishnan D., Tencer A.F. Contact characteristics of the subtalar joint after a simulated calcaneus fracture. *Journal of Orthopaedic Trauma* 1995; 9: 251–8.
22. Barrick B., Joyce D.A., Werner F.W., et al. Effect of calcaneus fracture gap without step-off on stress distribution across the subtalar joint. *Foot & Ankle International* 2017; 38: 298–303.
23. Buckley R., Tough S., McCormack R., et al. Operative compared with nonoperative treatment of displaced intra-articular calcaneal fractures: A prospective, randomized, controlled multicenter trial. *The Journal of Bone and Joint Surgery (American Volume)* 2002; 84-A: 1733–44.
24. Agren P.H., Mukka S., Tullberg T., et al. Factors affecting long-term treatment results of displaced intra-articular calcaneal fractures: A post-hoc analysis of a prospective, randomized, controlled multicenter trial. *Journal of Orthopaedic Trauma* 2014; 28: 564–8.
25. Agren P.H., Wretenberg P. & Sayed-Noor A.S. Operative versus nonoperative treatment of displaced intra-articular calcaneal fractures: A prospective, randomized, controlled multicenter trial. *The Journal of Bone and Joint Surgery (American Volume)* 2013; 95: 1351–7.
26. Sanders R., Vaupel Z., Erdogan M., et al. The Operative Treatment of Displaced Intra-articular Calcaneal Fractures (DIACFs): Long Term (10-20 years) results in 108 fractures using a prognostic CT Classification. *Journal of Orthopaedic Trauma* 2014; 28: 551-63.
27. Sharr P. J., Mangupli M.M., Winson I. G., et al. Current management options for displaced intra-articular calcaneal fractures: Non-operative, ORIF, minimally invasive reduction and fixation or primary ORIF and subtalar arthrodesis. A contemporary review. *Foot and Ankle Surgery* 2016; 22: 1-8.
28. Backes M., Spierings K.E., Dingemans S.A., et al. Evaluation and quantification of geographical differences in wound complication rates following the extended lateral approach in displaced intra-articular calcaneal fractures – A systematic review of the literature. *Injury* 2017; 48: 2329–35.
29. Bai L., Hou Y.L., Lin G.H., et al. Sinus tarsi approach (STA) versus extensile lateral approach (ELA) for treatment of closed displaced intra-articular calcaneal fractures (DIACF): A meta-analysis. *Orthopaedics and Traumatology, Surgery and Research* 2018; 104: 239-44.

30. Brouwers L., Teutelink A., van Tilborg F.A.J.B., et al. Validation study of 3D-printed anatomical models using 2 PLA printers for preoperative planning in trauma surgery, a human cadaver study. *European Journal of Trauma* 2019; 45: 1013-20.
31. Zheng W., Chen C., Zhang C., et al. The Feasibility of 3D Printing Technology on the Treatment of Pilon Fracture and Its Effect on Doctor-Patient Communication. *Biomedical Research International* 2018; 2018: 8054698.
32. Zheng W., Tao Z., Lou Y., et al. Comparison of the conventional surgery and the surgery assisted by 3D printing technology in the treatment of calcaneal fractures. *Journal of Investigative Surgery* 2017; 31: 557-67
33. Fischer M., Fuerst B., Lee S.C., et al. Preclinical usability study of multiple augmented reality concepts for K-wire placement. *International Journal of Computer Assisted Radiology and Surgery* 2016; **11**: 1007–14.
34. van Duren B.H., Sugand K., Wescott R., et al. Augmented reality fluoroscopy simulation of the guide-wire insertion in DHS surgery: A proof of concept study. *Medical Engineering & Physics* 2018; 55: 52–9.

Nederlandse samenvatting

Essentieel voor een optimaal resultaat van operatief behandelde intra-articulare fracturen is het optimaal visualiseren van de fractuurfragmenten en positie van de implantaten tijdens fractuur repositie en fixatie. Bij voorkeur vindt fractuur repositie en fixatie plaats met zo min mogelijk letsel aan de weke delen. De continue introductie van nieuwe technieken om de chirurg te ondersteunen bij het verbeteren van de kwaliteit van repositie en fixatie is vaak veelbelovend. Echter, deze technieken vereisen een kritische evaluatie om te testen of ze daadwerkelijk onze fractuurzorg verbeteren. Het doel van dit proefschrift was om het peroperatieve gebruik van 3D-Röntgendoorlichting bij fracturen van de extremiteiten kritisch te evalueren. Peroperatieve 3D-doorlichting kan de chirurg helpen om de kwaliteit van repositie en fixatie van intra-articulare fracturen van de extremiteiten te verbeteren. Een update van de epidemiologische data van extremiteitsfracturen was nodig om te bepalen voor hoeveel extremiteitsfracturen deze techniek in aanmerking zou kunnen komen. Om een beeldvormende techniek te kunnen evalueren was het eerst nodig om de radiologische uitkomst van de repositie en fixatie te definiëren, zodat de resultaten vergeleken konden worden.

In **Hoofdstuk 1** liet basale epidemiologie een groeiende en vergrijzende populatie zien en een algemene groei van de incidentie van extremiteitsfracturen in de periode van 2004-2012. Daarnaast werd een verschuiving naar meer operatieve behandelingen gezien en een toename in patiënt presentaties in perifere ziekenhuizen. Wanneer deze trends zich voortzetten zullen deze aantallen verder groeien. Hierdoor kunnen de maatschappelijke kosten mate stijgen. Daarom is het van belang dat beleidsmakers proactief de capaciteit en middelen aanpassen en tevens investeren in ondersteunende technieken voor het optimaliseren van de repositie en fixatie van fracturen.

Deel 1 – Deradiologischevaluatievanderepositieenfixatievanextremiteitsfracturen

Op basis van literatuurdata en ervaring van onze traumachirurgen, orthopeden en radiologen werd een online vragenlijst opgesteld om de belangrijkste radiologische criteria te identificeren voor de evaluatie van de repositie en fixatie. Groepsconsensus met Nederlandse klinische experts werd verkregen volgens de Delphi-methode voor de pols en de enkel, zoals werd beschreven in **Hoofdstuk 2**. De experts waren het erover eens dat de standaard radiologische work-up van de pols uit een posterieur-anterieure (PA) en laterale Röntgenprojectie moet bestaan. Voor het maken van pre- en postoperatieve CT-scans werd geen consensus bereikt. Er werd consensus bereikt dat de congruentie van de het polsgewricht geëvalueerd moet worden (wijdte en symmetrie van de gewrichtsspletten en configuratie van de carpalia), evenals de ulnaire variantie, dorsale angulatie, de grootte van distale radio-ulnaire gewrichtsspleet, de positie van de carpalia en hun relatie tot elkaar. Voor de repositie en fixatie is het van belang dat er geen intra-articulare trapjes, gaps en botfragmenten zijn en er geen osteosynthesemateriaal in het gewricht uitsteekt. Er kon geen consensus worden bereikt over de wijze van beoordelen van de radiologische parameters; moeten ze worden gemeten of kunnen ze op het oog worden beoordeeld. Voor de enkel werd alleen consensus bereikt voor een laterale Röntgenprojectie en de meeste experts (79%) gaven daarbij de voorkeur aan een Mortise projectie voor de radiologische evaluatie. Ook bij de enkel varieerde de meningen van de

experts met betrekking tot het standaard maken van pre- en postoperatieve CT-scans. In tegenstelling tot de pols werd consensus bereikt dat de evaluatie van de enkel op het oog kon worden verricht. De evaluatie van de anatomie van de enkel moet bestaan uit de beoordeling van de congruentie van het enkelgewricht, de symmetrie en breedte van de gewrichtsspleet, de afstand tussen de tibia en fibula ter hoogte van de syndesmose en de lengte en rotatie van de fibula. Repositie en fixatie van de enkel moet worden beoordeeld op basis van afwezigheid van intra-articulaire trapjes en gaps of botfragmenten; de positie van de fixatieplaat en ander osteosynthesemateriaal, bicorticale schroeflengte en de afwezigheid van intra-articulair uitstekend osteosynthesemateriaal.

In de studie beschreven in **Hoofdstuk 3** werd groepsconsensus bereikt met een internationaal expertpanel over de radiologische evaluatie van de calcaneus. Pre- en postoperatieve beeldvorming moet bestaan uit ten minste conventionele Röntgenopnames met een laterale projectie van de enkel en axiale projectie van de calcaneus. In de preoperatieve planning behoort een CT-scan tot de standaard work-up met reconstructies in drie vlakken (coronaal, sagittaal en axiaal). Peroperatief moet er een laterale projectie, een axiale projectie en een Brodén projectie worden gemaakt. Evaluatie van de anatomie moet bestaan uit de congruentie van het calcano-cuboidale (CC), posterieure talocalaneale (PTC) en anterieure talocalaneale (ATC) gewricht; de hoek van Böhler, de hoek van Gissane en de positie van de tuber calcanei. Voor de repositie en fixatie moet de afwezigheid van trapjes en gaps in het CC-gewricht, PTC-gewricht en het anterieure facet worden geëvalueerd met een acceptabele grens van ≤ 2 mm. Daarnaast mogen er geen botfragmenten in het CC-, ATC of PTC-gewricht bevinden. De positie van het osteosynthesemateriaal moet worden beoordeeld op de accuratesse van de positie van de plaat, de schroef in het sustentaculum en geen protrusie van osteosynthesemateriaal in het CC-, ATC- of PTC-gewricht, de mediale wand en de tuber calcanei.

Er werd een 23-items tellend scoringsprotocol opgesteld, gebaseerd op de internationale consensus, om systematisch de kwaliteit van de repositie en fixatie van operatief behandelde calcaneusfracturen te beoordelen. De validatie van dit scoringsprotocol werd beschreven in **Hoofdstuk 4**. Drie onafhankelijke beoordelaars hebben de kwaliteit van de repositie en fixatie beoordeeld, van de geblindeerde postoperatieve CT-scans van 102 calcaneusfracturen, volgens dit scoringsprotocol. Na een interval van een maand hebben de beoordelaars nogmaals een geselecteerde serie van 25 fracturen beoordeeld. De betrouwbaarheid tussen de verschillende beoordelaars van het 23-item scoring protocol was goed (ICC 0.66; 95% CI 0.64-0.69). De inter-beoordelaar betrouwbaarheid was goed voor alle drie beoordelaars met ICC's tussen de 0.60 en 0.70.

Deel 2 – Peroperatieve 3D-beeldvorming bij extremitetsfracturen

Veelbelovende resultaten werden gepubliceerd na de introductie van peroperatieve 3D-beeldvorming. Kadaverstudies lieten een diagnostische accuratesse zien die vergelijkbaar is met de CT-scan. Extra correcties waren nodig na 3D-beeldvorming die op basis van de 2D-beeldvorming niet waren herkend in klinische studies. Om een breder perspectief op de prestaties van peroperatieve 3D-beeldvorming te krijgen met betrekking tot diagnostische accuratesse, subjectieve beeldkwaliteit en klinische consequenties, werd een systematische beoordeling van de literatuur verricht en

beschreven in **Hoofdstuk 5**. In dit literatuuroverzicht hebben we systematisch de databases van MEDLINE, EMBASE en het Centrale Cochrane Register (tot en met maart 2012). Uiteindelijk vonden we 19 geschikte studies, bestaande uit 10 kadaver- en 9 klinische studies. Helaas kon vanwege heterogeniteit van de gerapporteerde uitkomsten en incomplete data geen meta-analyse worden verricht voor de diagnostische accuratesse. De diagnostische accuratesse van 3D-beeldvorming lijkt hoger te zijn dan 2D-doorlichting en conventionele Röntgendiagnostiek en vergelijkbaar met CT-scan voor zowel de beoordeling van de repositie en positie van het osteosynthesemateriaal. De subjectieve beeldkwaliteit van 3D-beeldvorming werd slechter beoordeeld in vergelijking met de andere modaliteiten. Additionele peroperatieve correcties werden in 11-40% verricht na 3D-beeldvorming met respectievelijk 2-40% correcties van de repositie en 6-26% van de fixatie of in 3-8% een combinatie van beiden. Met deze resultaten lijkt peroperatieve 3D-beeldvorming een veelbelovend diagnostisch hulpmiddel om de repositie en fixatie van extremitetsfracturen te optimaliseren.

Om deze veelbelovende resultaten te testen voor calcaneusfracturen hebben we een voor-na studie verricht in **Hoofdstuk 6** om de effecten van het peroperatieve gebruik van additionele 3D-beeldvorming op peroperatieve correcties, het type peri-operatieve beeldvorming wat werd gebruikt en de patiënt-relevante uitkomsten in vergelijking met het gebruik van alleen peroperatieve 2D-beeldvorming. In de periode van 2000-2014 konden 231 patiënten worden geïncludeerd, waarvan bij 46% van de operaties 3D-beeldvorming beschikbaar was. De operatieduur werd significant langer met een mediaan van 14 minuten wanneer 3D-beeldvorming werd gebruikt. Extra correcties na 3D-beeldvorming werden in 53% van de operaties gedaan, waarvan het in 96% correcties van de fixatie betrof. Tevens werd een afname in het aantal correcties na 2D-beeldvorming van 15% gezien als ook 3D-beeldvorming beschikbaar was. Er werden geen verschillen gevonden voor de patiënt-relevante uitkomsten of het type peri-operatieve beeldvorming. Hoewel deze studie ook extra correcties laat zien na 3D-beeldvorming, kon geen meerwaarde voor de patiënt worden vastgesteld.

In **Hoofdstuk 7** beschrijven we het protocol voor een multicenter gerandomiseerde klinische studie, opgezet om de klinische effecten van het gebruik van peroperatieve 3D-beeldvorming bij de pols, enkel en calcaneus te bepalen, de 'Extremity Fractures with intra-operative 3D-RX-trial (EF3X-trial)'. Tijdens deze studie werden patiënten met een traumatische fractuur van de pols, enkel of calcaneus gerandomiseerd in een van de twee studie-armen. Deze randomisatie bepaalde of de peroperatieve 3D-scan, die gemaakt werd na repositie en fixatie, beschikbaar was voor de chirurg om te zien. Dit studieontwerp werd gekozen om gedragsveranderingen van de chirurg ten aanzien van het gebruik van 2D-doorlichting uit te sluiten en alleen de toegevoegde waarde van peroperatieve 3D-beeldvorming te bepalen met betrekking tot de kwaliteit van repositie en fixatie en patiënt uitkomsten.

De uitkomsten van patiënten met een de calcaneusfractuur, geïncludeerd in de EF3X-trial, zijn gerapporteerd in **Hoofdstuk 8**. Er werden 102 operatief behandelde calcaneusfracturen van 100 patiënten gerandomiseerd. De operatieduur werd significant langer bij het gebruik van peroperatieve 3D-beeldvorming. Er kon echter geen verbetering

in de kwaliteit van de repositie en fixatie worden vastgesteld. Tevens werd er geen voordeel gevonden met betrekking tot postoperatieve complicaties, kwaliteit van leven, functionele uitkomst en posttraumatische artrose.

De correlatie tussen de evaluatie van de peroperatieve 3D-beelden en de postoperatieve CT-scan is bevredigend voor de positie van het osteosynthesemateriaal, zoals is beschreven in **Hoofdstuk 9**. De correlatie voor repositie is laag. Voor 2D-beeldvorming is er weinig correlatie voor de scorings-items behalve voor de evaluatie van het tuber calcanei. De subjectieve beeldkwaliteit van 3D-beeldvorming werd het slechtst beoordeeld ten opzichte van 2D-beeldvorming en CT-scan. Om de correlatie met de gouden standaard, de CT-scan, te verbeteren zou de beeldkwaliteit van peroperatieve 3D-beeldvorming moeten verbeteren met suppressie van stralingsverstrooiing door het osteosynthesemateriaal.

Algemene discussie & toekomstperspectieven

Het doel van dit proefschrift was om te exploreren of de kwaliteit van de repositie en fixatie van intra-articulaire extremiteitsfracturen, voornamelijk calcaneusfracturen, verbeterd kan worden door het gebruik van peroperatieve 3D-beeldvorming. Om dit te kunnen beoordelen werden radiologische scoring protocollen ontwikkeld voor de pols, enkel en calcaneus, en de laatste werd gevalideerd. Door de veelbelovende resultaten van de extra correcties die werden verricht na peroperatieve 3D-beeldvorming, verwachtten we dat de operatieresultaten en daarmee patiëntuitkomsten zouden verbeteren.

In onze studies werden extra correcties verricht na peroperatieve 3D-beeldvorming. Echter dit leidde bij calcaneusfracturen niet tot een klinisch effect met betrekking op verbetering van de kwaliteit van repositie en fixatie, re-operaties en patiënt gerapporteerde uitkomsten. Aan deze discrepantie met onze verwachte resultaten kunnen verschillende aspecten ten grondslag liggen.

Ten eerste zouden we het effect van de extra correcties die werden uitgevoerd kunnen hebben overschat. We zagen dat er een gedragsverandering plaatsvond tijdens het gebruik van peroperatieve 2D-beeldvorming wanneer ook 3D-beeldvorming beschikbaar was. Er was sprake van een daling van het aantal correcties na 2D-beeldvorming van 15% wanneer 3D-beeldvorming werd gebruikt.

Tevens werden de 225 beelden tijdens de 200° rotatie gedurende 30 seconden van de C-boog live getoond. De reconstructies in verschillende vlakken waren ongeveer drie minuten na de rotatie van de C-boog beschikbaar. De live-beelden tijdens de rotatie waren al zeer informatief voor zowel de evaluatie van de repositie als de fixatie. Dit inzicht leidde tot een dynamischer gebruik van continue 2D-doorlichting, wat de rotatie van de C-arm simuleert.

In het afgelopen decennium is het gebruik van peri-operatieve beeldvorming enorm veranderd. Pre- en postoperatieve CT-scans werden een decennium geleden nauwelijks gemaakt in de standaard work-up. Ons expert panel gaf in de Delphi consensus aan dat postoperatieve CT-scans niet nodig waren in de standaard radiologische evaluatie. Tegenwoordig is de CT-scan gangbaar in de peri-operatieve beeldvorming van intra-articulaire fracturen. Postoperatieve CT-scans hebben ons meer inzicht gegeven in de

kwaliteit van de repositie en fixatie. Zij hebben laten zien dat trapjes en gaps vaak groter zijn en het osteosynthesemateriaal vaker insufficiënt is of uitsteekt dan gedacht op basis van conventionele Röntgenbeelden. Deze inzichten hebben geleid tot additionele projecties en een meer dynamisch gebruik van 2D-beeldvorming. Bovenstaande redenen kunnen ertoe hebben geleid dat de toegevoegde waarde van peroperatieve 3D-beeldvorming minder is dan verwacht.

De sample-size berekening van de EF3X-trial was gebaseerd op retrospectieve data van de evaluatie van postoperatieve Röntgenbeelden van fracturen van de extremiteiten, zoals werd beschreven in **Hoofdstuk 7**. Uit deze data bleek dat er sprake was van een inadequate repositie en/of fixatie in 17% van de geopereerde fracturen aan de extremiteiten bij het gebruik van peroperatieve 2D-beeldvorming. Echter, de gevonden kwaliteit van repositie en fixatie van calcaneusfracturen in de EF3X-trial laten een veel hoger percentage van 59,6-69,4% benodigde revisies zien in beide groepen, gebaseerd op de postoperatieve CT-scan. Een verklaring voor dit verschil is dat de kwaliteit van repositie en fixatie op basis van conventionele Röntgenbeelden wordt overschat vergeleken met evaluatie van een CT-scan. Een andere factor in deze studie zou het gebruikte scoringsprotocol kunnen zijn. We evalueerden 23 items met betrekking op de repositie en fixatie van calcaneus fracturen. Wanneer de repositie en fixatie zo uitgebreid gescoord wordt, in plaats van te focussen op bijvoorbeeld het gewrichtsoppervlak, dan is het ook waarschijnlijker dat er een reden tot verbetering wordt gevonden. De evaluatie van de CT-beelden werd buiten de operatiekamers verricht. Hierdoor waren beoordelaars niet gehinderd door de realiteit van operatieve uitdagingen. Waardoor de drempel van indicaties voor revisies lager zou kunnen liggen. Werkelijke revisie-operaties vanwege inadequate repositie en/of fixatie werden slechts in 2% van de operaties uitgevoerd in beide randomisatie-groepen.

Het hypothetische effect van 12% slechts 5% inadequate repositie en/of fixatie van extremiteitsfracturen met behulp van peroperatieve 3D-beeldvorming was gebaseerd op een studie van Kendoff et al. In deze studie worden revisie-operaties verricht in 4% van de 129 patiënten met een variëteit aan extremiteitsfracturen. De noodzaak voor een revisie was gebaseerd op postoperatieve CT-scans vanwege een intra-articulair trapje (>2 mm), gap (> 2mm) of intra-articulaire protrusie van het osteosynthesemateriaal. Studies met een uitgebreide beschrijving van de kwaliteit van repositie en fixatie werden niet gevonden.

Calcaneusfracturen zijn waarschijnlijk een eigen entiteit binnen de extremiteitsfracturen, vanwege de multipale articulaties en de vorm. Terugkijkend is het de vraag hoe representatief de resultaten van onze eigen retrospectieve studie en Kendoff et al. zijn voor calcaneusfracturen. Toentertijd was dit het beste aanwezige bewijs om onze sample size te berekenen.

De EF3X-trial was ontworpen om de klinische effectiviteit van het additionele gebruik van peroperatieve 3D-beeldvorming ten opzichte van 2D-beeldvorming te onderzoeken. Het secundaire doel was om de diagnostische prestatie in een klinische setting te bepalen. Om de werkelijke toegevoegde waarde te onderzoeken van peroperatieve 3D-beeldvorming, hebben we ervoor gekozen dat de chirurg alleen maar een 3D-scan mocht maken nadat hij tevreden was met de fractuur repositie en fixatie gebaseerd

op de peroperatieve 2D-beeldvorming. In onze retrospectieve studie zagen we dat de beschikbaarheid van peroperatieve 3D-beeldvorming onbewust de houding ten opzichte van de peroperatieve 2D-beeldvorming veranderde. Dit ontwerp heeft ook de drempel verhoogd om een inadequate repositie van fractuurfragmenten te reviseren. Aan het einde van de procedure weegt een chirurg of de verwachte voordelen van het reviseren van zowel repositie als fixatie opweegt tegen de nadelen. Deze nadelen, zoals een verlengde operatietijd en een hoger infectierisico, zouden minder kunnen zijn wanneer repositie van fractuurfragmenten al geëvalueerd kan worden na alleen tijdelijke fixatie. Een meer pragmatisch ontwerp met vrij gebruik van peroperatieve 3D-beeldvorming zou een grotere toegevoegde waarde kunnen laten zien. Echter, dit zou niet de werkelijk toegevoegde waarde van 3D-beeldvorming laten zien, ondanks de extra stralingsbelasting voor de patiënt. Aan de andere kant zou bij een meer pragmatisch ontwerp de gemiddelde peroperatieve stralingsbelasting van zowel 2D- als 3D-beeldvorming per patiënt worden berekend en afgezet tegen de winst voor de kwaliteit van fractuur repositie en fixatie.

Patiënten werving voor deelname aan de EF3X-trial bleek lastiger dan was geanticipeerd. Oorzaken hiervoor kunnen een overschatting van presentaties van patiënten met fracturen per ziekenhuis zijn of meer dan verwachte exclusie van patiënten. Door de concentratie van zorg werd de overgrote meerderheid van de patiënten met een calcaneusfractuur geïnccludeerd door het coördinerende centrum. Het is bekend dat de patiëntpopulatie met calcaneusfracturen vaak psychiatrische comorbiditeiten heeft en de geschiktheid om te participeren in wetenschappelijk onderzoek was minder dan verwacht. Uiteindelijk, na 4 jaar van inclusie is vanwege logistieke en financiële redenen besloten om de patiënt-inclusie ruim voor de 250 patiënten te beëindigen. Gezien de huidige data, is er niet de verwachting dat onze conclusies zullen wijzigen bij uitbreiding van het aantal geïnccludeerde patiënten.

Voor calcaneusfracturen is er bewijs dat anatomische repositie en fixatie waarbij de vorm van de calcaneus wordt hersteld, alsmede de congruentie van het gewricht, tot acceptabele functionele uitkomsten leidt. In zowel biomechanische als in klinische studies worden verschillen in uitkomsten gezien bij trapjes ≥ 2 mm en gaps ≥ 3 mm in het posterieure talocalcaneale gewricht. De hoek van Böhler en hielwijdte zijn belangrijk voor de vorm van de calcaneus en herstel ervan is geassocieerd met betere klinische uitkomsten. Echter perfecte anatomische repositie en fixatie is niet altijd haalbaar vanwege fractuurinstabiliteit, verminderde botkwaliteit en slechte weke delen conditie. Daarbij is de anatomische repositie niet de enige voorspeller van de functionele uitkomst van de patiënt. Schade die ontstaan is tijdens het letsel aan zowel het bot als kraakbeen is een belangrijke voorspeller voor de functionele uitkomst, gezien de correlatie met de Sanders fractuurclassificatie zoals Sanders et al. heeft beschreven. Patiëntfactoren zoals co-morbiditeit en middenvoetmisbruik zijn eveneens belangrijke factoren die de functionele uitkomst bepalen. Tenslotte zijn er ontwikkelingen geweest in de fractuurbenadering, met minder weke delen letsel, die het infectiepercentage kunnen verminderen en daarmee ook de functionele uitkomst verbeteren. Bij de sinus tarsi benadering zien we maar een infectiepercentage van 2,9-4,1% in vergelijking met een infectiepercentage van 14,4-21,2% bij de 'extended lateral approach' (ELA). Als gevolg van een verlaging van het aantal infecties werden betere klinische resultaten gevonden.


Patiënt gerelateerde uitkomsten bij de operatieve behandeling van calcaneusfracturen is niet alleen afhankelijk van de radiologische uitkomst van de repositie en fixatie. Daarom is het van belang de juiste patiënt en de juiste fractuur te selecteren en daarvoor de juiste operatietechniek en benadering te kiezen. Op welke wijze deze factoren zich tot elkaar verhouden en in hoeverre anatomische repositie en fixatie moet worden nagestreefd ten koste van weke delen schade om een passende behandeling voor iedere patiënt aan te kunnen bieden moet nog verder worden uitgezocht.

Aan het aantal peroperatieve revisies dat kan worden uitgevoerd zit een beperking vanwege de vermindering van de botkwaliteit bij ieder nieuw boorgat en een groter wordend infectierisico bij een langere operatieduur. Peroperatieve 3D-beeldvorming wordt meestal aan het eind van de operatie uitgevoerd en dan moet het verwachte voordeel van reviseren worden afgewogen tegen de nadelen. Daarom is preoperatieve planning belangrijk om het aantal benodigde revisies peroperatief te limiteren. De huidige preoperatieve planning wordt nu verricht in het hoofd van de chirurg op basis van de preoperatieve CT-scan met de mogelijkheid van 3D-volume beelden. Tegenwoordig wordt 3D-printen algemeen beschikbaar en heeft het bewezen accuraat gewrichten en fracturen te kunnen reproduceren. 3D-printen van fracturen geeft de chirurg de mogelijkheid om preoperatief te oefenen met de repositie en het benodigde osteosynthesemateriaal te kiezen en de positionering ervan te bepalen. Tevens kan het contralaterale bot als model dienen. Praktische problemen kunnen daarmee al preoperatief worden gesignaleerd en geadresseerd en kan op basis daarvan de planning worden aangepast. Sommige studies hebben laten zien dat preoperatieve simulatie met 3D-geprinte modellen leidt tot een kortere operatieduur, verminderd bloedverlies, minder gebruik van doorlichting en betere anatomische repositie en fixatie. Tevens kunnen de fractuurmodellen helpen bij de patiënt-communicatie om de operatieprocedure uit te leggen en verwachtingen van de functionele uitkomst te sturen.

Augmented reality is een andere belovende techniek die voor steeds meer toepassingen beschikbaar wordt. Deze techniek kan worden gebruikt voor het uit de vrije hand vergrendelen van intramedullaire pennen. Tevens kan preoperatief digitaal een gedetailleerd operatieplan worden opgesteld, welke peroperatief op de patiënt kan worden geprojecteerd om zo de chirurg te ondersteunen de fractuur in de juiste volgorde te reponeren en het osteosynthesemateriaal accuraat op de juiste positie te plaatsen.

Het peroperatieve gebruik van 3D-beeldvorming in zijn huidige vorm heeft in ons onderzoek niet geleid tot betere patiëntuitkomsten in de operatieve behandeling van calcaneusfracturen. Aan de andere kant zijn er ook geen indicaties dat peroperatieve 3D-beeldvorming patiëntuitkomsten negatief heeft beïnvloed, ondanks de relatief lage extrastalingsbelasting. Bij simpele fracturen gefixeerd met weinig osteosynthesemateriaal kunnen trapjes en of gaps of intra-articulair uitstekend osteosynthesemateriaal peroperatief worden gedetecteerd door 3D-beeldvorming. Voor de meer complexe fracturen die uitgebreide osteosynthese vereisen moet peroperatieve 3D-beeldvorming verder worden ontwikkeld. Daarom heeft peroperatieve 3D-beeldvorming nog geen plaats verdiend in de standaard operatieve behandeling van intra-articulaire fracturen in de dagelijkse praktijk. Het potentieel van deze techniek is de moeite waard om te

exploreren en kan van waarde zijn bij andere fractuurtypen, 3D-navigatie of augmented reality. Andere nieuwe veelbelovende technieken dienen zich aan en er zal moeten worden uitgezocht of zij patiëntuitkomsten verder kunnen verbeteren. Al deze technieken zullen ook weer kritisch moeten worden geëvalueerd of patiënten daadwerkelijk voordeel hebben van het gebruik van deze nieuwe technieken en niet alleen als 'toys for the boys (and girls)' functioneren.



Appendix

PhD portfolio

Name PhD student:	M.S.H. Beerekamp		
PhD period:	2009 - 2020		
Name PhD supervisor:	Prof. dr. J.C. Goslings & Prof. dr. D.T. Ubbink	Year	Workload (ECTS)

1. PhD training**General courses**

• The AMC World of Science	2009	0,7
• Evidence-Based Chirurgie	2009	0,6
• Pubmed	2009	0,1
• Scientific Writing in English for publication	2009	1,5
• Systematic Reviews	2009	0,7
• Clinical Data Management	2010	0,3
• Oral presentation in English	2010	0,8
• Good clinical practice	2010,2017	0,9
• Practical Biostatistics	2010	1,1
• Clinical Epidemiology	2010	1,2

Specific courses

• Advanced topics in clinical epidemiology	2011	0,6
• Stralingshygiëne deskundigheidsniveau 5B	2010	1,7
• Stralingshygiëne deskundigheidsniveau 3C	2017	1,7

Seminars, workshops and master classes

• Master of Science in Evidence Based Practice, University of Amsterdam	2010-2012	99
• Regionaal refereren regio II	2009- 2018	2,0
• Regionaal Trauma refereren, regio Oost	2014-2018	0,5

Presentations

• European Congress of Trauma and Emergency Surgery, Basel, Switzerland	2012	0,5
- Evaluation of quality of fracture reduction and fixation of the calcaneus in clinical practice: An international Delphi consensus (Poster)		
- Radiographs in wrist injury: Routine or obligatory? (Oral presentation)		
• Chirurgendagen, Veldhoven, the Netherlands	2012	0,5
- De beoordeling van de kwaliteit van repositie en fixatie van calcaneusfracturen – Een internationale Delphi consensus. (Oral presentation)		

	Year	Workload (ECTS)
<ul style="list-style-type: none"> • Assistensymposium, Nederlandse Vereniging voor Traumachirurgie <ul style="list-style-type: none"> - De beoordeling van de kwaliteit van repositie en fixatie van calcaneusfracturen – Een internationale Delphi consensus. (Oral presentation) 	2012	0,5
<ul style="list-style-type: none"> • Assistentensymposium, Nederlandse Vereniging voor Traumachirurgie <ul style="list-style-type: none"> Radiographs in wrist injury: Routine of obligatory? (Oral presentation) 	2011	0,5
<ul style="list-style-type: none"> • European Congress of Trauma and Emergency Surgery, Milan, Italy <ul style="list-style-type: none"> - Accuracy and consequences of 3D-fluoroscopy in upper and lower extremity fracture treatment – A systematic review (Poster) 	2011	0,5
<ul style="list-style-type: none"> • European Congress of Radiology, Vienna, Austria <ul style="list-style-type: none"> - How to evaluate the quality of fracture reduction and fixation of the wrist and ankle in clinical practice: A Delphi consensus (Oral presentation) 	2010	0,5
<ul style="list-style-type: none"> • Traumadagen, Nederlandse Vereniging voor Traumachirurgie <ul style="list-style-type: none"> - Peroperatief gebruik van 3D-RX bij fracturen aan de extremiteiten (Poster) - X-pols en X-enkel: waar kijken we eigenlijk naar? Een Delphi consensus (Poster) 	2009	0,5
(Inter)national conferences		
<ul style="list-style-type: none"> • European Congress of Trauma and Emergency Surgery, Amsterdam 	2011, 2012	0,75
<ul style="list-style-type: none"> • Traumadagen, NVT 	2010-2012, 2015, 2017	1,0
<ul style="list-style-type: none"> • Chirurgendagen, NvvH 	2010-2019	1,5
Other		
<ul style="list-style-type: none"> • Traumabespreking, wekelijks 	2014-2018	1,0

	Year	Workload (ECTS)
<u>2. Teaching</u>		
Lecturing		
<ul style="list-style-type: none"> • Traumadagen, Nederlandse Vereniging voor Traumachirurgie - -3D doorlichting op de Trauma OK 	2011	0,5
Tutoring, Mentoring		
<ul style="list-style-type: none"> • Liselotte Ras, Master thesis interim analysis EF3X-trial • Gor Khatchikyan, Master thesis digital goniometer • Irene Lok, Master thesis PRAISE-trial • Aniek Bagijn, Master thesis POSITIVE trial • Jasper Vallinga, Master thesis AWR 	2011 2011 2010 2012 2011	1 1 1 1 1
<u>3. Parameters of Esteem</u>		
Grants		
<ul style="list-style-type: none"> • Philips Healthcare Best, the Netherlands • ZonMw, implementation of Amsterdam Wrist rules 	2009 2012/13	
Awards and Prizes		
<ul style="list-style-type: none"> • Assistensymposium, Nederlandse Vereniging voor Traumachirurgie <p>Dr. Heijmans award for best presentation</p>	2012	

Curriculum Vitae

Maria Suzanne Henriëtte Beerekamp, Suzan, werd 30 november 1983 in Amsterdam geboren en groeide op in 'klein Oostenrijk' in Hoogeveen. Daar ging ze naar het VWO op de openbare scholengemeenschap 'De Groene Driehoek' en slaagde cum laude in 2001. In datzelfde jaar begon zij met de studie geneeskunde in Groningen. Na co-schappen te hebben gelopen in het Sint Elisabeth Ziekenhuis op Curaçao en in Deventer Ziekenhuizen, heeft zij haar onderzoeksstage en keuze co-schap in het Amsterdam Universitair Medische Centra, locatie AMC gedaan onder supervisie van R. Haverlag en Prof. Dr. J.C. Goslings en rondde zij haar studie af in 2008. Dit was een goed moment om op de motor te stappen en via de zuidelijke zijderoute naar de Olympische Spelen in Beijing te rijden in een oranje karavaan met nog 6 motorrijders, 12 auto's en een DAF-stadsbus. Na terugkomst kwam de kans om een beurs bij Philips Medical Systems, Best aan te vragen om de klinische effectiviteit van peroperatieve 3D-beeldvorming te onderzoeken bij fracturen aan de extremiteiten wat uiteindelijk heeft geleid tot dit promotietraject en proefschrift. In afwachting van de start van het onderzoek heeft Suzan als arts niet in opleiding (ANIOS) in Tergooi ziekenhuizen, locatie Hilversum gewerkt onder supervisie van Dr. J.P. Eerenberg. Ten tijde van het promotieonderzoek heeft ze een 2-jarige master in Evidence Based Medicine afgerond. Na 3 jaar promotie-onderzoek in de Amsterdam Universitair Medische Centra, locatie AMC onder supervisie van Prof. Dr. J.C. Goslings, Prof. Dr. D.T. Ubbink en Dr. N.W.L. Schep, startte zij in 2012 met haar opleiding tot chirurg in de Amsterdam Universitair Medische Centra, locatie AMC onder supervisie van Prof. Dr. O.R.C. Busch. In 2014 vervolgde zij haar opleiding in Gelre Ziekenhuizen en startte haar differentiatie traumachirurgie onder supervisie van Dr. P. van Duijvendijk. Zij vervolgde haar differentiatie voor traumachirurgie en een certificering voor chirurgie bij kinderen in het Amsterdam Universitaire Medische Centra, locatie AMC onder supervisie van Dr. E.J. Nieveen van Dijkum, alwaar zij ook de opleiding eind juni 2020 afrondde. Per 1 juli zal zij als Fellow Traumachirurgie starten in het Medisch Spectrum Twente in Enschede. In 2013 trouwde zij met Michiel van Waning en samen hebben zij 3 kinderen: Kiki, Boaz en Sam.

List of publications

This Phd-thesis

Epidemiology of extremity fractures in the Netherlands

Beerekamp M.S.H., de Muinck Keizer R.J.O., Schep N.W.L., Ubbink D.T., Panneman M.J., Goslings J.C.

Injury. 2017; 48: 1355-62

How to evaluate the quality of fracture reduction and fixation of the wrist and ankle in clinical practice: A Delphi consensus

Beerekamp M.S.H., Haverlag R., Ubbink D.T., Luitse J.S.K., Ponsen K.J., Goslings J.C.

Archives of Orthopaedic Trauma Surgery, 2011;131:739-46

Evaluation of quality of fracture reduction and fixation of the calcaneus in clinical practice: An international Delphi consensus

Beerekamp M.S.H., Luitse J.S.K., Ubbink D.T., Schep N.W.L., Goslings J.C.

Archives of Orthopaedic Trauma Surgery 2013; 133: 1377-84.

Systematic CT evaluation of reduction and hardware positioning of surgically treated calcaneal fractures: a reliability analysis

De Muinck Keizer R.J.O., **Beerekamp M.S.H.**, Ubbink D.T., Beenen L.F., Schepers T., Goslings J.C.

Archives of Orthopaedic Trauma Surgery 2017; 137: 1261-67.

Accuracy and consequences of 3D-fluoroscopy in upper and lower extremity fracture treatment - A systematic review

Beerekamp M.S.H., Sulkers G.S., Ubbink, D.T., Maas M., Schep N.W.L., Goslings J.C.

European Journal of Radiology 2012; 81: 4019-28

Effects of intra-operative fluoroscopic 3D-imaging on perioperative strategy in calcaneal fracture surgery

Beerekamp M.S.H., Backes M., Schep N.W.L., Ubbink D.T., Luitse J.S.K., Schepers T., Goslings J.C.

Archives of Orthopaedic Trauma Surgery 2017; 137: 1667-75

Fracture Surgery of the extremities with the intra-operative use of 3D-RX:

A randomized multicenter trial (EF3X-trial)

Beerekamp M.S.H., Ubbink D.T., Maas M., Luitse J.S.K., Kloen P., Blokhuis T.J., Segers M.J., Marmor M., Schep N.W.L., Dijkgraaf M.G., Goslings J.C.; project group of the EF3X-trial.

BMC Musculoskeletal Disorders. 2011; 12: 151

Intraoperative effect of 2D vs 3D fluoroscopy on quality of reduction and patient-related outcome in calcaneal fracture surgery

Halm J.A., **Beerekamp M.S.H.**, de Muinck Keizer R.J.O., Beenen L.F., Maas M., Goslings J.C., Schepers T., project group of the EF3X-trial.

Foot & Ankle International, 2020: ePub ahead of print

The Clinical Diagnostic Correlation of Intra-Operative Two- and Three-Dimensional Fluoroscopy with postoperative CT-evaluation in the Treatment of Calcaneal Fractures
Beerekamp M.S.H., de Muinck Keizer R.J.O., Schepers T., Beenen L.F., Luitse J.S.K., Schep N.W.L., Goslings J.C., on behalf of the EF3X-studygroup
 European Journal of Radiology. 2019; 112: 222-8

Intraoperative 3D-imaging

Het peroperatieve gebruik van 3D-beeldvorming bij fracturen aan de extremiteiten
Beerekamp M.S.H., Haverlag R., Luitse J.S.K., Ubbink D.T., Goslings J.C.
 Nederlands Tijdschrift voor de Traumachirurgie 2011 (1); blz 2-8

Peroperatieve 3D-beeldvorming bij intra-articulaire fracturen aan de extremiteiten:
 Stand van Zaken
Beerekamp M.S.H., Ubbink D.T., Luitse J.S.K., Goslings J.C.
 Nederlands Tijdschrift voor Geneeskunde 2011;155: A2737

The value of intraoperative 3D fluoroscopy in the treatment of distal radius fractures:
 a randomized clinical trial
 Selles C.A., **Beerekamp M.S.H.**, de Muinck Keizer R.J.O., Leenhouts P.A., Kloen P., Blokhuis T.J., Segers M.J., Ubbink D.T., Goslings J.C., Schep N.W.L., on behalf of the EF3X-study group
 The Journal of Hand Surgery (American Volume) 2020; 45:189-95

The Amsterdam Wrist Rules

Amsterdam Wrist Rules: A clinical decision aid.
 Bentohami A., Walenkamp M.M., Slaar A., **Beerekamp M.S.H.**, de Groot J.A., Verhoog E.M., Jager L.C., Maas M., Bijlsma T.S., van Dijkman B.A., Schep N.W.L., Goslings J.C.
 BMC Musculoskeletal Disorders 2011; 12 :238

The Amsterdam wrist rules: The multicenter prospective derivation and external validation of a clinical decision rule for the use of radiography in acute wrist trauma.
 Walenkamp M.M., Bentohami A., Slaar A., **Beerekamp M.S.H.**, Maas M., Jager L.C., Sosef N.L., van Velde R., Ultee J.M., Steyerberg E.W., Goslings J.C., Schep N.W.L.
 Nederlands Tijdschrift voor Geneeskunde 2016; 160: D234.

Functional outcome in patients with unstable distal radius fractures, volar locking plate versus external fixation: a meta-analysis.
 Walenkamp M.M., Bentohami A., **Beerekamp M.S.H.**, Peters R.W., van der Heiden R., Goslings J.C., Schep N.W.L.
 Strategies in Trauma Limb Reconstruction 2013; 8: 67-75

The Amsterdam wrist rules: the multicenter prospective derivation and external validation of a clinical decision rule for the use of radiography in acute wrist trauma.
 Walenkamp M.M., Bentohami A., Slaar A., **Beerekamp M.S.H.**, Maas M., Steyerberg E.W., Goslings J.C., Schep N.W.L.
 BMC Musculoskeletal Disorders 2018;16: 389

List of publications

Demographics, fracture patterns and treatment strategies following wrist trauma
Mulders M.A.M., Bentohami A., Beerekamp M.S.H., Vallinga J., van Dijkman B., Goslings J.C., Schep N.W.L.

Acta Orthopaedica Belgica, 2019; 85: 234-9

Calcaneal fractures

Wound infections following open reduction and internal fixation of calcaneal fractures with an extended lateral approach.

Backes M., Schepers T., Beerekamp M.S.H., Luitse J.S.K., Goslings J.C., Schep N.W.L.

International Orthopaedics 2014; 38:767-73.

Prospective Computed Tomographic Analysis of Osteochondral Lesions of the Ankle Joint Associated with Ankle Fractures.

Nosewicz T.L., Beerekamp M.S.H., de Muinck Keizer R.J.O., Schepers T., Maas M., van Dijk C.N., Goslings J.C.

Foot & Ankle International 2016; 37: 829-34.

Domestic Violence

Prevalence of abuse and intimate partner violence surgical evaluation (PRAISE) in orthopaedic fracture clinics: a multinational prevalence study.

PRAISE Investigators, *Sprague S., Bhandari M., Della Rocca G.J., Goslings J.C., Poolman R.W., Madden K., Simunovic N., Dosanjh S., Schemitsch E.H.*

Lancet 2013; 382: 866-76

Prevalence of Abuse and Intimate Partner Violence Surgical Evaluation (P.R.A.I.S.E.): rationale and design of a multi-center cross-sectional study

PRAISE Investigators, *Bhandari M., Sprague S., Dosanjh S., Wu V., Schemitsch E.H.*

BMC Musculoskeletal Disorders 2010; 11: 77.

Patient Opinions of Screening for Intimate Partner Violence in a Fracture Clinic Setting: P.O.S.I.T.I.V.E.: A Multicenter Study.

Sprague S., Goslings J.C., Petrisor B.A., Avram V., Ayeni O.R., Schemitsch E.H., Poolman R.W., Madden K., Godin K., Dosanjh S., Bhandari M., P.O.S.I.T.I.V.E. Investigators.

The Journal of Bone & Joint Surgery (American Volume) 2013; 95(13): e911-10.

Screenen naar partnergeweld op de polikliniek traumachirurgie en orthopedie

Beerekamp M.S.H., *Goslings J.C., Luitse J.S.K., Scholtes V.A.P., Haverlag R., Poolman R.W., Sprague S., Schemitsch S.H., Bhandari M.*

Nederlands Tijdschrift voor de Traumachirurgie 2015; 4: 1

Dankwoord

Eindelijk is het zover; dit proefschrift heeft zijn weg naar de drukker gevonden! Deze reis is vaak anders gelopen dan van tevoren gepland en kende behoorlijk wat omwegen, hoge toppen, woelige wateren en soms diepe dalen. Dankbaar ben ik voor alle ontmoetingen, 'ongezochte vondsten', inzichten en persoonlijke groei die dit mij heeft gebracht. 'Life is what happens to you while you're busy making other plans' (John Lennon).

Veel mensen hebben bijgedragen aan dit proefschrift. Graag wil ik iedereen hartelijk danken, zonder jullie was dit proefschrift er niet geweest. Patiënten, verpleegkundigen, poli-medewerkers, traumachirurgen, operatie-assistenten, A(N)IOS, radiologen, radiologie-laboranten, projectgroepleden, medeauteurs, collegae en eenieder die zich niet onder deze opsomming kan scharen. Een aantal mensen wil ik graag in het bijzonder bedanken.

Prof. dr. J.C. Goslings, beste Carel, hartelijk dank dat je mij de kans hebt gegeven de onderzoeken voor dit proefschrift op te zetten toen ik net uit de schoolbanken kwam. Jouw sturing bij deze onderzoeken en tekstuele precisie waren van enorme waarde. Hoewel het niet altijd gemakkelijk moet zijn geweest, wil ik je bedanken voor het geduld dat je hebt gehad om mij te begeleiden tot er eindelijk een kaft om dit proefschrift heen kon.

Prof. dr. D.T. Ubbink, beste Dirk, jouw methodologische inbreng in dit proefschrift is van onschatbare waarde. Altijd kon jij helder uiteenzetten wat de voor- en nadelen van verschillende aanpakken zouden zijn en hoe we de onderzoeksopzet zo zuiver mogelijk konden houden. Wat ontzettend mooi, dat je nu mijn mede-promotor kan zijn in plaats van co-promotor.

Dr. N.W.L. Schep, beste Niels, jij kwam precies in het AMC op het moment dat ik vast zat met enkele manuscripten. Met jouw 'niet lullen, maar poetsen'-mentaliteit, trok je mij daar snel doorheen. Jouw liefde voor de hand en pols werkt aanstekelijk en ik hoop mij ook daarin verder te kunnen ontwikkelen. Maar nu is het eerst tijd voor een borrel!

Beste Robert, ik had mij als student geen warmer welkom in het AMC kunnen voorstellen voor mijn wetenschappelijke stage. Aan het studentenkamertje op G7, tegenover de afdeling en met uitzicht op Abcoude, heb ik vele goede herinneringen met medestudenten. Dankzij jou hebben wij ons onderzoeksvoorstel kunnen indienen om dit promotie-traject in te zetten. Wat fijn dat jij op afstand altijd betrokken bent gebleven en wij nu ook het einde van dit tijdperk kunnen vieren.

Beste Jan, jouw zeeën van ervaring zijn regelmatig een kompas geweest voor het pragmatisch opzetten van studies en verklaren van bevindingen. Hartelijk dank daarvoor.

Beste Tim en Jens, jullie liefde en enthousiasme voor zowel de voet en in het bijzonder calcaneusfracturen als de wetenschap waren een boost voor de laatste manuscripten. Ik waardeer het enorm dat jullie mij geholpen hebben mijn werk op een hoger niveau te tillen.

Dankwoord

EF3X-studie groep, Michiel Seegers, Bas Twigt, Taco Blokhuis, Marieke Kokke, Mario Maas, Ludo Beenen. Hartelijk dank voor het meedenken aan de studie-opzet, het werven en behandelen van patiënten, de beoordeling van een heleboel Röntgen- en CT-beelden en het kritisch meelesen van de manuscripten.

Beste Bart Carelsen, door jou ben ik in aanraking gekomen met de peroperatieve 3D-beeldvorming en mocht ik de klinische vertaling gaan doen van de meer technische aspecten die jij hebt onderzocht. Ik wil je bedanken voor een hele prettige samenwerking als contactpersoon voor ons onderzoek bij Philips, welke werd voortgezet door Peter Belei, Martijn Giessen en Jan Rongen. Ik kan me geen grotere expert op het gebied van peroperatieve 3D-beeldvorming bedenken en vind het dan ook een eer dat je nu in mijn promotiecommissie plaats hebt genomen.

Beste leden van de promotiecommissie. Prof. dr. P.M.M. Bossuyt, Prof. dr. F. Nollet, Prof. dr. M. Poeze, Prof. dr. R.J. Bennink, Dr. V.P.M. van der Hulst en, Dr. J.A. Halm en Dr. B. Carelsen. Hartelijk dank voor het beoordelen van dit proefschrift op zijn wetenschappelijke waarde. Het is een eer dit proefschrift ten overstaan van u te mogen verdedigen.

Lieve Jacq, altijd kun je even bij jou binnenlopen voor een gezellige klets of om iets te regelen. Jij weet altijd raad. Met jouw no-nonsense mentaliteit is alles binnen no-time geregeld. Ilse, jij nam het stokje probleemloos over en ik vind het knap hoe je de op de achtergrond de organisatie voor het trauma-team verzorgt. Ik wil je dan ook heel erg bedanken voor al je hulp bij het afronden van mijn promotie. Secretaresses van G4, in het bijzonder Joke, Coos^t en Els, het was en is altijd heerlijk om jullie even op te zoeken.

Zonder Jolanda was de follow-up van patiënten op de poli niet gelukt. Hartelijk dank voor je inzet en je probleemoplossend vermogen om te zorgen dat we zoveel mogelijk gegevens konden verzamelen.

Traumateam Teun, Pieter, Jo, Do, Pieter, Robert-Jan, Manouck, Wendy, Monique, Marjolein. Fijn dat ik altijd bij de jullie naar binnen kon lopen om te sparren. Samen maakten we van ieder congres een feest. RJ, dank voor het overnemen van mijn projecten en ik heb van je kunnen afkijken hoe deze te verdedigen.

Master-buddies Sanne, Nienke en Tessa. Twee jaar lang zaten we elke woensdagavond in de collegebanken om ons verder in de Evidence Based Medicine te verdiepen. Taaie kost werd met jullie een stuk beter te verteren!

Collega's van Gelre ziekenhuizen, verpleging en OK- en SEH-personeel, poli-medewerkers en secretariaat hartelijk dank voor de warme ontvangst. De vakgroep chirurgie en in het bijzonder. Peter en Hessel als hoofd- en vice-opleider wil ik bedanken voor de sturing, aandacht en oprechte interesse in jullie assistenten. Deze is goud waard. Hugo, Mike, Rob en Fred, jullie hebben me de fijne kneepjes van het trauma vak geleerd. Met jullie kunde en pragmatisme hebben jullie me geleerd hoe ieder probleem kan worden opgelost.

Lieve Q, Fleur, Eef, Kat & Lex, vanaf 2002 sloeg de vonk in de pan! Wat ben ik blij dat ik met jullie lief en leed mag delen. Ik weet dat ik altijd bij jullie terecht kan en andersom. En er komt nu weer meer tijd om te mixen & shaken, dus dat zit goed!

Lieve Jolien, Meike, Leo, Gooi, Els, Carlijn, Ab & Suzie-Q, weekendjes op de Bergeend of in de Hopschuur staan garant voor een goed gesprek en buikpijn van het lachen. Het is en blijft wonderlijk dat de mannen in d'Aldwal steeds jonger worden. Ik wil daarom aantekenen dat dit de wing-women-taken wel bemoeilijkt. Maar 'no guts, no gleuries', volgend jaar weer?

Daan en Laura, het paadje wat onze tuinen verbond is in de jaren dat we naast elkaar woonden helemaal platgelopen. Dank dat ik altijd even kon buurten!

Lieve Renske, Lisette en Marlous, vriendinnen van allemaal verschillende tijden. Hoewel het contact niet altijd even intensief is, zijn jullie me dierbaar.

Lieve Familie Gabriels, Jan[†], Anna, Jan-Willem, Hilgo en Roosje, wat was het heerlijk om als enig kind bij jullie gezin aan te schuiven en de dynamiek met twee grote broers te mogen ervaren. Roosje, onze vriendschap is me dierbaar ook al zien we elkaar niet vaak. Zonder de sturing van Jan aan de keukentafel, was ik waarschijnlijk geen geneeskunde gaan doen. Gezamenlijk hebben jullie een prachtig bedrijf opgebouwd. Zijn tijd ver vooruit. Ik vergeet nooit hoe het allemaal aan de keukentafel met hulp van de oma's is begonnen.

Lieve Fleur en lieve Frans, wat bijzonder fijn dat jullie naast mij staan bij de verdediging van mijn proefschrift.

Fleurtje, meestal hebben we aan één woord genoeg, hoewel we ook nooit uitgepraat raken. Jouw nuchterheid, oprechtheid en creativiteit zijn inspirerend. Het is een eer om zo'n krachtige en prachtige vrouw aan mijn zijde te mogen hebben.

Fransje, Dushi! Op de Kenepa is een mooie vriendschap ontstaan en gelukkig blijven onze paden elkaar kruisen. Geen dag heb ik jou chagrijnig gezien. Ik bewonder je levensvreugde en hoe je met frisse moed elke uitdaging aangaat.

Lieve Paul, Sabine, Wouter, Fré, Andy en Sammy. Wat ben ik in een enorm warm nest beland. Toen jullie ons uitzwaaiden in Castig op ons Vespa scootertje had ik nooit kunnen bedenken dat Gorssel een tweede thuis zou worden. Het is heerlijk om te zien dat onze kinderen dat ook zo ervaren.

Lieve pap & mam, dank voor de liefde, vrijheid en het vertrouwen wat ik altijd onvoorwaardelijk heb gevoeld om als zelfbewust mens in het leven te staan. Er is nog steeds niets lekkerder om thuisthuis op de bank te ploffen en te kletsen over wat ons bezighoudt.

Dankwoord

Lieve Kiki, Boaz & Sam, jullie drietjes zijn het meest bijzondere wat ons is overkomen. Op jullie eigen wijze hebben jullie ons al zoveel over onszelf geleerd en wat belangrijk is in dit leven. Intens lieve dromertjes, ik heb zo'n ontzettende zin in alle avonturen die we samen gaan beleven!

Mich, mijn lieve man, die mij heeft geleerd het onbekende te omarmen en af en toe gewoon een avontuur aan te gaan. Dit heeft mij en ons ontzettend veel leuke en spannende ervaringen gebracht. We kunnen samen op één Vespa scooter langs de kustlijn van West-Europa naar huis rijden, op de motor naar Beijing, toeren in de sneeuw of lekker burgerlijk thuis of 'op Vlie' knudderen en genieten van ons prachtige gezin. Onze liefde is als een cliché begonnen en vele clichés zouden kunnen beschrijven hoe blij ik ben dat ik mijn leven met jou mag delen. Geen dag met jou is saai. *Ton étoile est près de moi...*

